

Wills Eye Resident Series: Photophobia and decreased vision bring a patient to Wills, p. 65

REVIEW[®] *of* OPHTHALMOLOGY

July 2024 • reviewofophthalmology.com

Clinical advice you can trust

CORNEA/ANTERIOR SEGMENT

Managing SLK

PAGE 23

REFRACTIVE/CATARACT RUNDOWN

How to Handle Hyperopia

PAGE 27

RETINAL INSIDER

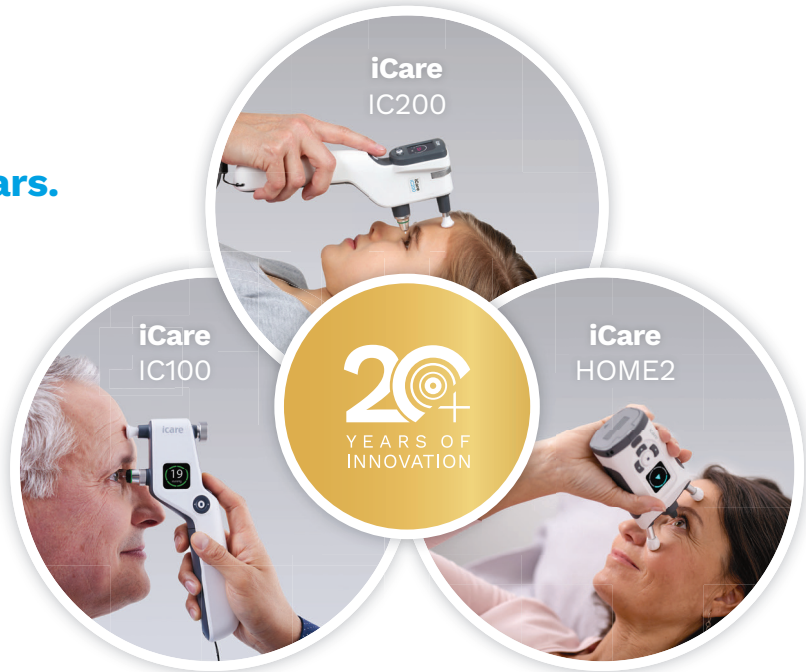Best Practices for Treating CSCR

PAGE 60

TREATING THE UNUSUAL PATIENT

Innovating rebound
tonometry for over 20 years.

Get to know
why iCare
is the Gold
Standard.



Learn more about iCare's leading
rebound tonometry technology.

Scan or visit www.icare-world.com/USA

icare

iCare is a trademark of Icare Finland Oy, Icare Finland Oy, Icare USA, Inc., Icare World Australia Pty Ltd and Centervue S.p.A., are parts of Revenlo Group and represent the brand iCare. iCare COMPASS, iCare DRSplus, iCare EIDON, iCare EIDON AF, iCare EIDON FA, iCare IC100, iCare IC200 and iCare ILLUME are trademarks or registered trademarks of Icare Finland Oy in the EU and the USA and/or other countries. Centervue S.p.A. is the legal manufacturer of DRSplus, COMPASS, EIDON, EIDON AF, EIDON FA, EIDON UWF Module, DRS, MAIA and S-MAIA. Not all products, accessories, services or offers are approved in every market. Approved labeling and instructions may vary from one country to another. ©2024 Icare Finland Oy. All rights reserved. ICARE-TONOMETRY-TRADE ADS-MM-274-1.0

iCare EIDON Family

High-resolution imaging covering 200°



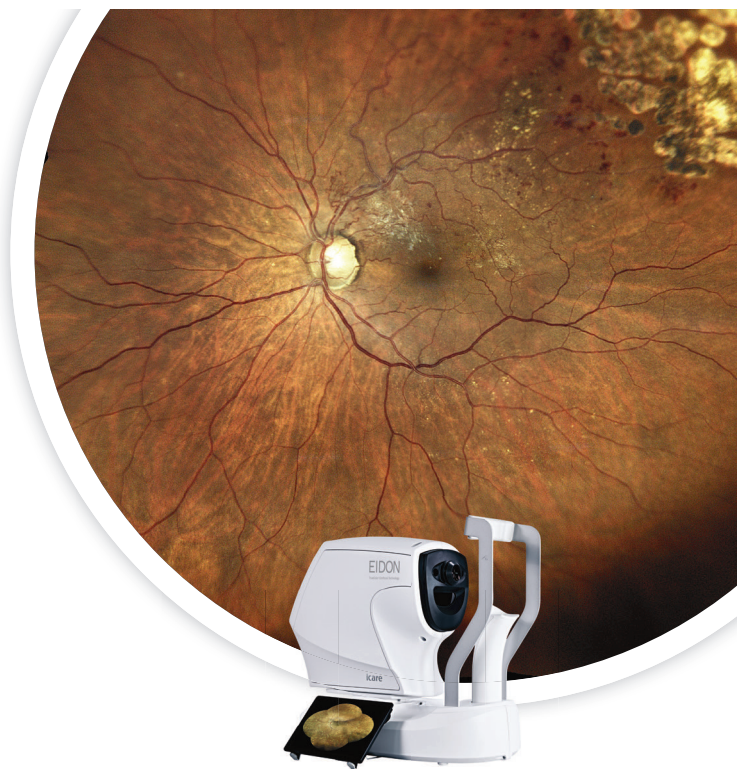Using white LED light provides TrueColor detail rich retinal images from the macula to the periphery



Confocal Technology allows scanning through media opacities and pupils as small as 2.5 mm resulting in high resolution images



Fully automated easy-to-use family of products with advanced features and multiple imaging modalities



Discover the next level of eye care
with our full line of devices.

Scan or visit www.icare-world.com/USA

icare | **20** YEARS OF
+ INNOVATION

Wills Eye Resident Series: Photophobia and decreased vision bring a patient to Wills, p. 65

REVIEW[®] *of* OPHTHALMOLOGY

July 2024 • reviewofophthalmology.com

Clinical advice you can trust

CORNEA/ANTERIOR SEGMENT

Managing SLK

PAGE 23

REFRACTIVE/CATARACT RUNDOWN

How to Handle Hyperopia

PAGE 27

RETINAL INSIDER

Best Practices for Treating CSCR

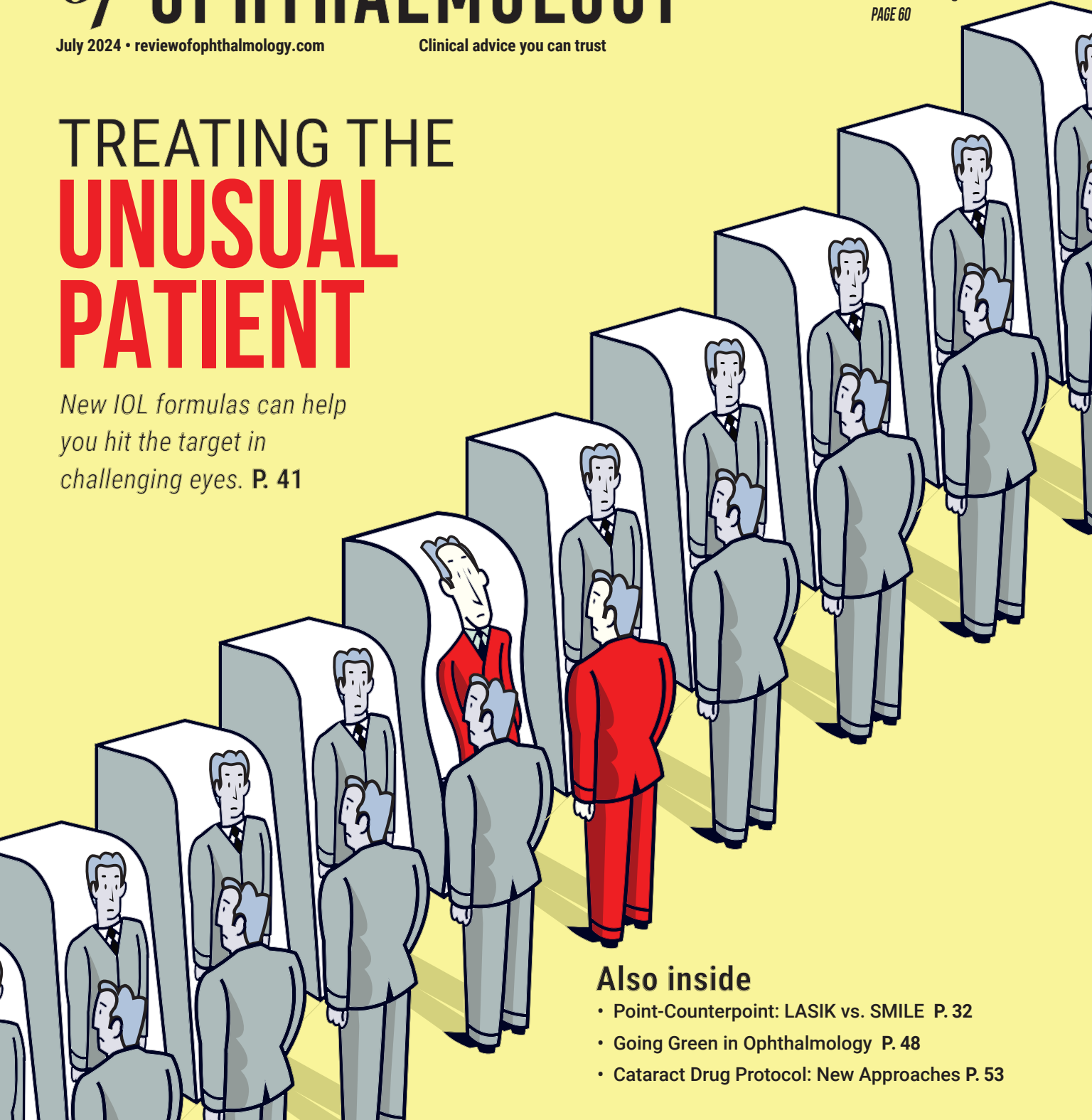
PAGE 60

TREATING THE UNUSUAL PATIENT

*New IOL formulas can help
you hit the target in
challenging eyes. P. 41*

Also inside

- Point-Counterpoint: LASIK vs. SMILE P. 32
- Going Green in Ophthalmology P. 48
- Cataract Drug Protocol: New Approaches P. 53



From The Eye Care Experts At
BAUSCH + LOMB

A NEW
**Clinically Proven
Supplement
For Dry Eyes***

Available
in the eye
care aisle



**BLINK™ NUTRITEARS®
WORKS DIFFERENTLY BY:**



Addressing dry
eyes from the
inside out*§



Promoting
healthy tear
production*§



Reducing patient
discomfort in
2 to 4 weeks*§

**RECOMMEND AS A COMPLEMENT TO
EVERY DRY EYE MANAGEMENT PLAN!**
To order patient samples, call 1-855-542-5682

*These statements have not been evaluated by the Food and Drug Administration.
This product is not intended to diagnose, treat, cure, or prevent any disease.

§Based on a clinical trial; N=116, randomized 1:1 NT and placebo.

©2024 Bausch + Lomb. BLS.0103.USA.24

Don't Wait for All Glaucoma Tests to Show Progression

Because prompt recognition of disease progression is the key to vision preservation, a recent study based out of Massachusetts Eye and Ear focused on whether detection of glaucoma progression is usually associated with concordance of structural and functional testing at the same clinic visit or not.¹ The researchers' longitudinal study over a five-year period found that both OCT structural parameters (i.e., RNFL thickness and minimum distance band rim thickness) and Humphrey visual field (HVF) functional parameters rarely progressed at the same time. Notably, the classic tests of structure and function detected disease progression in the same eye at the same visit in only 5 percent of eyes.

“The classic teaching for many residency programs is that tests of structure have to match tests of function,” says study co-author Teresa C. Chen, MD. “For example, a healthy nerve should match a normal visual field test. So, if you have a normal nerve measurement but an abnormal visual field test, then one should suspect that perhaps one of the tests is inaccurate. In the present study, however, there was very little agreement between when tests of structure worsened and when tests of function worsened.”

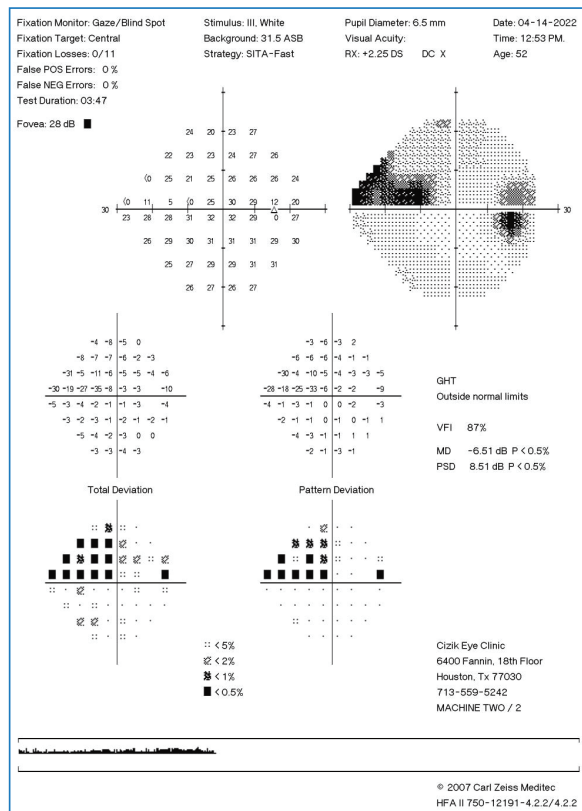
In the study of 124 open-angle glaucoma patients, one eye was randomly selected for each patient. Patients were included if they had open-angle glau-

ments and a 3D OCT neuroretinal rim measurement called minimum distance band, “the high-density version of the commercially available low-density

Bruch's membrane opening-minimum rim width,” the authors explained in their paper for the *American Journal of Ophthalmology*. For each test at each study visit, eyes were classified as progressors or non-progressors using event-based analysis.

The study found that 75 percent of eyes showed glaucoma progression by at least one of four tests by the end of the study period. The best overall agreements, including eyes of all glaucoma severities, were observed between minimum distance band thickness and RNFL thickness (17.5 percent of eyes) and between minimum distance band thickness and Humphrey visual field testing (16.1 percent), while the poorest agreements were observed between disc photography and RNFL thickness (5 percent) and between disc photography and Humphrey visual field testing (3.3 percent). Instead, progression is usually detected by just one or two tests (62.9 percent [78/124] of the time).

“This suggests that the higher sensitivity of the minimum distance band compared with traditional disc photography leads to better agreement in detecting progression at the same time as functional Humphrey visual field testing,” the researchers



A longitudinal study found that visual field parameters and OCT structural parameters rarely progressed at the same clinical visit.

coma and if they had at least four yearly study visits. Study visits included a full dilated eye exam, disc photography, Humphrey visual field (24-2) testing, 2D OCT RNFL thickness measure-

wrote in their paper. “This novel minimum distance band rim thickness OCT parameter measures neuroretinal rim thickness in 3D space and is a high-density version of the commercially available low-density Bruch’s membrane opening–minimum rim width.”

The researchers also explained in their paper that structural tests may better detect progression in pre-perimetric or early-stage glaucoma patients, while functional Humphrey visual field testing may detect progression better in advanced glaucoma patients.

“These are important findings, because if a clinician sees that the structural test is worse, that could really mean disease progression, and we don’t necessarily need to have progressive functional vision loss to confirm that,” Dr. Chen says.

If one test shows progression and the other doesn’t, she advises checking for artifacts and testing accuracy, and if any issues are present, consider repeating the test. In contrast, “if the test demonstrating progression seems accurate, if the reliability indices are good, and/or if there aren’t any testing artifacts, then a repeat test may not be needed. Then one would be more likely to initiate treatment,” she explains.

“It’s important for clinicians to realize that tests of structure can get worse at different times than tests of function,” Dr. Chen says. “As long as we understand this as our general framework when looking at tests in the clinic, we’re more likely to make the right treatment decisions for our patients. It’s recommended that clinicians use all available structural and functional testing to

assess glaucoma progression.”

Dr. Chen has no related financial disclosures.

Teresa C. Chen has received funding from Fidelity Charitable Fund (Harvard University), National Institutes of Health (NIH) R01 EB033321, NIH R44 EY034409, NIH UG1 EY033703, Alcon Laboratories, NIH UL1 RR025758, Massachusetts Lions Eye Research Fund, American Glaucoma Society Mid-Career Award. The sponsors or funding organizations had no role in the design or conduct of this research.

1. Manik D, Ratanawongphaibul K, Kim J, et al. Frequency of agreement between structural and functional glaucoma testing: a longitudinal study of 3D OCT and current clinical tests. *Am J Ophthalmol.* May 27, 2024. [Epub ahead of print].

Controlling Hypertension May Help Delay DR

Researchers recently investigated the relative impact of hypertension vs. diabetes on the wall-to-lumen ratio (WLR) of retinal arterioles in diabetic retinopathy.¹ Their prospective cross-sectional study aimed to address the unresolved question of whether there is a difference in WLR between healthy subjects and those with diabetes mellitus before the onset of clinical retinopathy (DR) and if so, whether the increase in WLR is mainly driven by diabetes or hypertension.

The study compared the retinal arteriolar WLR in 17 healthy eyes, 15 with diabetes but no apparent DR and eight with diabetic macular edema (DME) and either nonproliferative or proliferative DR. Adaptive optics scanning laser ophthalmoscopy (AO-SLO) and multiple linear regression were used to quantify the WLR and determine the effects of age, hypertension and diabetes.

The results showed that both subjects with diabetes but no apparent DR and subjects with DME had significantly higher WLR in retinal

arterioles compared to healthy subjects. The mean WLR for healthy subjects was 0.29, while for subjects with diabetes and no DR it was 0.36, and for subjects with DME it was 0.42.



When analyzing the correlation between WLR and hypertension, diabetes and age, it was found that in healthy subjects and subjects with diabetes and no DR, hypertension had the strongest effect on WLR. The analysis also showed that hypertension and WLR shared a significant positive

correlation, though age and diabetes were not significantly correlated with WLR in these groups.

In the analysis that included all three groups (healthy, diabetes no DR, and DME), diabetes had the strongest effect on WLR, and the two variables were positively correlated. Age and hypertension were not significantly correlated with WLR in this analysis.

While the small sample in this study limits its effect size, its results support the hypothesis that hypertension may be an early driver of retinal arteriolar wall thickening in preclinical DR, independent of age or diabetes. On the other hand, changes specific to DR may drive wall thickening in DME and later stages of DR.

“Our study sheds light on, and begins to address, an important gap in our knowledge regarding the relative contribution of hypertension (early) and diabetes (later) in the course of DR,” the researchers wrote in their study. “Understanding the pathogenesis of preclinical DR is important for the development of treatments to

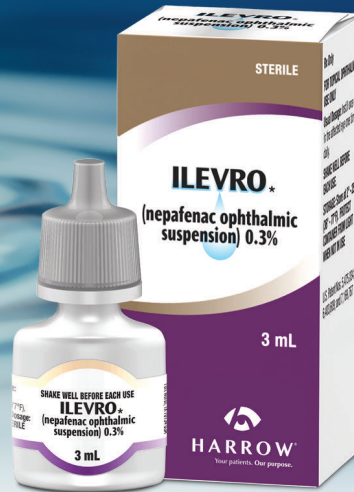ILEVRO[®]
(nepafenac ophthalmic
suspension) 0.3%

For your cataract surgery patients

STRIKE

AT
INFLAMMATION AND PAIN

Effective. Convenient. Accessible.



Learn more at
ILEVROHCP.com

INDICATIONS AND USAGE

ILEVRO[®] (nepafenac ophthalmic suspension) 0.3% is a nonsteroidal, anti-inflammatory prodrug indicated for the treatment of pain and inflammation associated with cataract surgery.

Dosage and Administration

One drop of ILEVRO[®] 0.3% should be applied to the affected eye one-time-daily beginning 1 day prior to cataract surgery, continued on the day of surgery and through the first 2 weeks of the postoperative period. An additional drop should be administered 30 to 120 minutes prior to surgery.

IMPORTANT SAFETY INFORMATION

Contraindications

ILEVRO[®] 0.3% is contraindicated in patients with previously demonstrated hypersensitivity to any of the ingredients in the formula or to other nonsteroidal anti-inflammatory drugs (NSAIDs).

Adverse Reactions

The most frequently reported ocular adverse reactions following cataract surgery occurring in approximately 5% to 10% of patients were capsular opacity, decreased visual acuity, foreign body sensation, increased intraocular pressure, and sticky sensation.

For additional information about ILEVRO[®] 0.3%, please see the Brief Summary of Full Prescribing Information on the following page or visit ilevrohcp.com.

Reference: ILEVRO (nepafenac ophthalmic suspension) 0.3% [package insert]. Harrow IP LLC; 2023.

ILEVRO, the ILEVRO logo, and the Harrow logo are registered trademarks of Harrow IP, LLC.
IVRO-00052 02/24 © 2024 Harrow. All Rights Reserved.


HARROW[®]
Your patients. Our purpose.

ILEVRO®

(nepafenac ophthalmic suspension) 0.3%

BRIEF SUMMARY OF PRESCRIBING INFORMATION

INDICATIONS AND USAGE

ILEVRO® (nepafenac ophthalmic suspension) 0.3% is indicated for the treatment of pain and inflammation associated with cataract surgery.

DOSAGE AND ADMINISTRATION

Recommended Dosing

One drop of ILEVRO® Suspension should be applied to the affected eye one-time-daily beginning 1 day prior to cataract surgery, continued on the day of surgery and through the first 2 weeks of the postoperative period. An additional drop should be administered 30 to 120 minutes prior to surgery.

Use with Other Topical Ophthalmic Medications

ILEVRO® Suspension may be administered in conjunction with other topical ophthalmic medications such as beta-blockers, carbonic anhydrase inhibitors, alpha-agonists, cycloplegics, and mydriatics. If more than one topical ophthalmic medication is being used, the medicines must be administered at least 5 minutes apart.

CONTRAINDICATIONS

ILEVRO® Suspension is contraindicated in patients with previously demonstrated hypersensitivity to any of the ingredients in the formula or to other NSAIDs.

WARNINGS AND PRECAUTIONS

Increased Bleeding Time

With some nonsteroidal anti-inflammatory drugs including ILEVRO® Suspension, there exists the potential for increased bleeding time due to interference with thrombocyte aggregation. There have been reports that ocularly applied nonsteroidal anti-inflammatory drugs may cause increased bleeding of ocular tissues (including hyphemas) in conjunction with ocular surgery. It is recommended that ILEVRO® Suspension be used with caution in patients with known bleeding tendencies or who are receiving other medications which may prolong bleeding time.

Delayed Healing

Topical nonsteroidal anti-inflammatory drugs (NSAIDs) including ILEVRO® Suspension, may slow or delay healing. Topical corticosteroids are also known to slow or delay healing. Concomitant use of topical NSAIDs and topical steroids may increase the potential for healing problems.

Corneal Effects

Use of topical NSAIDs may result in keratitis. In some susceptible patients, continued use of topical NSAIDs may result in epithelial breakdown, corneal thinning, corneal erosion, corneal ulceration or corneal perforation. These events may be sight threatening. Patients with evidence of corneal epithelial breakdown should immediately discontinue use of topical NSAIDs including ILEVRO® Suspension and should be closely monitored for corneal health. Post marketing experience with topical NSAIDs suggests that patients with complicated ocular surgeries, corneal denervation, corneal epithelial defects, diabetes mellitus, ocular surface diseases (e.g., dry eye syndrome), rheumatoid arthritis, or repeat ocular surgeries within a short period of time may be at increased risk for corneal adverse events which may become sight threatening. Topical NSAIDs should be used with caution in these patients. Post marketing experience with topical NSAIDs also suggests that use more than 1 day prior to surgery or use beyond

14 days post-surgery may increase patient risk and severity of corneal adverse events.

Contact Lens Wear

ILEVRO® Suspension should not be administered while using contact lenses.

ADVERSE REACTIONS

Because clinical studies are conducted under widely varying conditions, adverse reaction rates observed in the clinical studies of a drug cannot be directly compared to the rates in the clinical studies of another drug and may not reflect the rates observed in practice.

Serious and Otherwise Important Adverse Reactions

The following adverse reactions are discussed in greater detail in other sections of labeling:

- Increased Bleeding Time (Warnings and Precautions)
- Delayed Healing (Warnings and Precautions)
- Corneal Effects (Warnings and Precautions)

Ocular Adverse Reactions

The most frequently reported ocular adverse reactions following cataract surgery were capsular opacity, decreased visual acuity, foreign body sensation, increased intraocular pressure, and sticky sensation. These reactions occurred in approximately 5 to 10% of patients.

Other ocular adverse reactions occurring at an incidence of approximately 1 to 5% included conjunctival edema, corneal edema, dry eye, lid margin crusting, ocular discomfort, ocular hyperemia, ocular pain, ocular pruritus, photophobia, tearing and vitreous detachment.

Some of these reactions may be the consequence of the cataract surgical procedure.

Non-Ocular Adverse Reactions

Non-ocular adverse reactions reported at an incidence of 1 to 4% included headache, hypertension, nausea/vomiting, and sinusitis.

USE IN SPECIFIC POPULATIONS

Pregnancy

Teratogenic Effects.

Pregnancy Category C: Reproduction studies performed with nepafenac in rabbits and rats at oral doses up to 10 mg/kg/day have revealed no evidence of teratogenicity due to nepafenac, despite the induction of maternal toxicity. At this dose, the animal plasma exposure to nepafenac and amfenac was approximately 70 and 630 times human plasma exposure at the recommended human topical ophthalmic dose for rats and 20 and 180 times human plasma exposure for rabbits, respectively. In rats, maternally toxic doses ≥ 10 mg/kg were associated with dystocia, increased postimplantation loss, reduced fetal weights and growth, and reduced fetal survival.

Nepafenac has been shown to cross the placental barrier in rats. There are no adequate and well-controlled studies in pregnant women. Because animal reproduction studies are not always predictive of human response, ILEVRO® Suspension should be used during pregnancy only if the potential benefit justifies the potential risk to the fetus.

Non-teratogenic Effects

Because of the known effects of prostaglandin biosynthesis inhibiting drugs on the fetal cardiovascular system (closure of the ductus arteriosus), the use of ILEVRO® Suspension during late pregnancy should be avoided.

Nursing Mothers

ILEVRO® Suspension is excreted in the milk of lactating rats. It is not known whether this drug is excreted in human milk. Because many drugs are excreted in human milk, caution should be exercised when

ILEVRO® Suspension is administered to a nursing woman.

Pediatric Use

The safety and effectiveness of ILEVRO® Suspension in pediatric patients below the age of 10 years have not been established.

Geriatric Use

No overall differences in safety and effectiveness have been observed between elderly and younger patients.

NONCLINICAL TOXICOLOGY Carcinogenesis, Mutagenesis, Impairment of Fertility

Nepafenac has not been evaluated in long-term carcinogenicity studies. Increased chromosomal aberrations were observed in Chinese hamster ovary cells exposed *in vitro* to nepafenac suspension. Nepafenac was not mutagenic in the Ames assay or in the mouse lymphoma forward mutation assay. Oral doses up to 5,000 mg/kg did not result in an increase in the formation of micronucleated polychromatic erythrocytes *in vivo* in the mouse micronucleus assay in the bone marrow of mice. Nepafenac did not impair fertility when administered orally to male and female rats at 3 mg/kg.

PATIENT COUNSELING INFORMATION

Slow or Delayed Healing

Patients should be informed of the possibility that slow or delayed healing may occur while using nonsteroidal anti-inflammatory drugs (NSAIDs).

Avoiding Contamination of the Product

Patients should be instructed to avoid allowing the tip of the dispensing container to contact the eye or surrounding structures because this could cause the tip to become contaminated by common bacteria known to cause ocular infections. Serious damage to the eye and subsequent loss of vision may result from using contaminated solutions.

Use of the same bottle for both eyes is not recommended with topical eye drops that are used in association with surgery.

Contact Lens Wear

ILEVRO® Suspension should not be administered while wearing contact lenses.

Intercurrent Ocular Conditions

Patients should be advised that if they develop an intercurrent ocular condition (e.g., trauma, or infection) or have ocular surgery, they should immediately seek their physician's advice concerning the continued use of the multi-dose container.

Concomitant Topical Ocular Therapy

If more than one topical ophthalmic medication is being used, the medicines must be administered at least 5 minutes apart.

Shake Well Before Use

Patients should be instructed to shake well before each use.

U.S. Patent Nos. 5,475,034; 6,403,609; and 7,169,767.

©2023 Harrow 06/23 IVRO-00012



HARROW®

CONTRIBUTORS

CHIEF MEDICAL EDITOR

Mark H. Blecher, MD

CONTACT LENSES

Penny Asbell, MD

CORNEA / ANTERIOR SEGMENT

Thomas John, MD

GLAUCOMA MANAGEMENT

Peter Netland, MD, PHD
Kuldev Singh, MD

MEDICARE Q & A

Mary Pat Johnson,
COMT, CPC

PEDIATRIC PATIENT

Janine Collinge, MD

PLASTIC POINTERS

April Lao, MD

REFRACTIVE SURGERY

Arturo S. Chayet, MD

RETINAL INSIDER

Carl Regillo, MD, FACS
Yoshihiro Yonekawa, MD

TECHNOLOGY UPDATE

Steven T. Charles, MD
Michael Colvard, MD

WILLS RESIDENT CASE SERIES

Collin Rozanski, MD

ADVISORY BOARD

PENNY A. ASBELL, MD, MEMPHIS, TENN.

BRANDON AYRES, MD, PHILADELPHIA

SURENDRA BASTI, MD, CHICAGO

WILLIAM I. BOND, MD, PEKIN, ILL.

ALAN N. CARLSON, MD, DURHAM, N.C.

Y. RALPH CHU, MD, EDINA, MINN.

ADAM J. COHEN, MD, CHICAGO

JANINE COLLINGE, MD, FARMINGTON, CONN.

UDAY DEVGAN, MD, FACS, LOS ANGELES

ERIC DONNENFELD, MD, ROCKVILLE CENTRE, N.Y.

DANIEL S. DURRIE, MD, KANSAS CITY, MO.

ROBERT EPSTEIN, MD, MCHENRY, ILL.

ROBERT D. FECHTNER, MD, NEWARK, N.J.

BRIAN FRANCIS, MD, Los Angeles

JAMES P. GILLS, MD, TARPON SPRINGS, FLA.

HARRY GRABOW, MD, SARASOTA, FLA.

DOUGLAS K. GRAYSON, MD, NEW YORK CITY

DAVID R. HARDTEN, MD, MINNEAPOLIS

SARA J. HAUG, MD, PHD, DURANGO, COLO.

KENNETH J. HOFFER, MD, SANTA MONICA, CALIF.

JACK T. HOLLADAY, MD, MSEE, HOUSTON

JOHN D. HUNKELER, MD, KANSAS CITY, MO.

THOMAS JOHN, MD, TINLEY PARK, ILL.

ROBERT M. KERSHNER, MD, MS, PALM BEACH GARDENS, FLA.

GUY M. KEZIRIAN, MD, PARADISE VALLEY, ARIZ.

SUMITRA KHADELWAL, MD, HOUSTON

TERRY KIM, MD, DURHAM, N.C.

BRAD KLIGMAN, MD, MANHASSET, N.Y.

TOMMY KORN, MD, SAN DIEGO

APRIL LAO, MD, MEMPHIS

DAVID A. LEE, MD, HOUSTON

FRANCIS S. MAH, MD, LA JOLLA, CALIF.

NICK MAMALIS, MD, SALT LAKE CITY

EDWARD MANCHE, MD, PALO ALTO, CALIF.

MIKE S. MCFARLAND, MD, PINE BLUFF, ARK.

JEFFREY B. MORRIS, MD, MPH, ENCINITAS, CALIF.

KEVIN MILLER, MD, LOS ANGELES

MAJID MOSHIRFAR, MD, DRAPER, UTAH

MARLENE R. MOSTER, MD, PHILADELPHIA

ROBERT J. NOECKER, MD, FAIRFIELD, CONN.

ROBERT OSHER, MD, CINCINNATI

MARK PACKER, MD, WEST PALM BEACH, FLA.

CHRISTOPHER J. RAPUANO, MD, PHILADELPHIA

AUGUST READER III, MD, SAN FRANCISCO

TONY REALINI, MD, MPH, MORGANTOWN, W.V.

KENNETH J. ROSENTHAL, MD, GREAT NECK, N.Y.

ERIC ROTHCHILD, MD, DELRAY BEACH, FLA.

SHERI ROWEN, MD, BALTIMORE

INGRID U. SCOTT, MD, MPH, HERSHEY, PA.

JOEL SCHUMAN, MD, PITTSBURGH

GAURAV SHAH, MD, ST. LOUIS

DAVID R. STAGER JR., MD, DALLAS

KARL STONECIPHER, MD, GREENSBORO, N.C.

JAMES C. TSAI, MD, NEW YORK CITY

VANCE THOMPSON, MD, SIOUX FALLS, S.D.

FARRELL C. TYSON, MD, CAPE CORAL, FLA.

R. BRUCE WALLACE III, MD, ALEXANDRIA, LA.



BUSINESS OFFICES

19 CAMPUS BOULEVARD, SUITE 101
NEWTOWN SQUARE, PA 19073
SUBSCRIPTION INQUIRIES (877) 529-1746
(USA ONLY); OUTSIDE USA, CALL (847) 763-9630

BUSINESS STAFF

PUBLISHER

MICHAEL HOSTER

(610) 492-1028 MHOSTER@JOBSON.COM

SENIOR MANAGER, STRATEGIC ACCOUNTS

MICHELE BARRETT

(610) 492-1014 MBARRETT@JOBSON.COM

REGIONAL SALES MANAGER

JONATHAN DARDINE

(610) 492-1030 JDARDINE@JOBSON.COM

DIGITAL MARKETING MANAGER

MATT EGGER

(610) 492-1029 MEGGER@JOBSON.COM

CLASSIFIED ADVERTISING

(888)-498-1460

PRODUCTION MANAGER

KAREN LALLONE

(610) 492-1010 KLALLONE@JOBSON.COM

SUBSCRIPTIONS

\$63 A YEAR, \$99 (U.S.) IN CANADA,
\$158 (U.S.) IN ALL OTHER COUNTRIES.

SUBSCRIPTIONS E-MAIL:

REVOPHTHALMOLOGY@CAMBEYWEST.COM

CIRCULATION

PO BOX 71, CONGERS, NY 10920-0071

(877) 529-1746

OUTSIDE USA: (845) 267-3065

SENIOR CIRCULATION MANAGER

HAMILTON MAHER

(212) 219-7870 hmaher@jihhealth.com

CEO, INFORMATION GROUP SERVICES

BILL SCOTT

VICE PRESIDENT, CREATIVE SERVICES & PRODUCTION

MONICA TETTAMANZI

CREATIVE DIRECTOR • INTERNATIONAL MEDICAL NEWSGROUP

LOUISE KOENIG

DIRECTOR, PRODUCTION/MANUFACTURING

REBECCA SLEBODNIK

VICE PRESIDENT, HUMAN RESOURCES

TAMMY GARCIA

VICE PRESIDENT, CIRCULATION

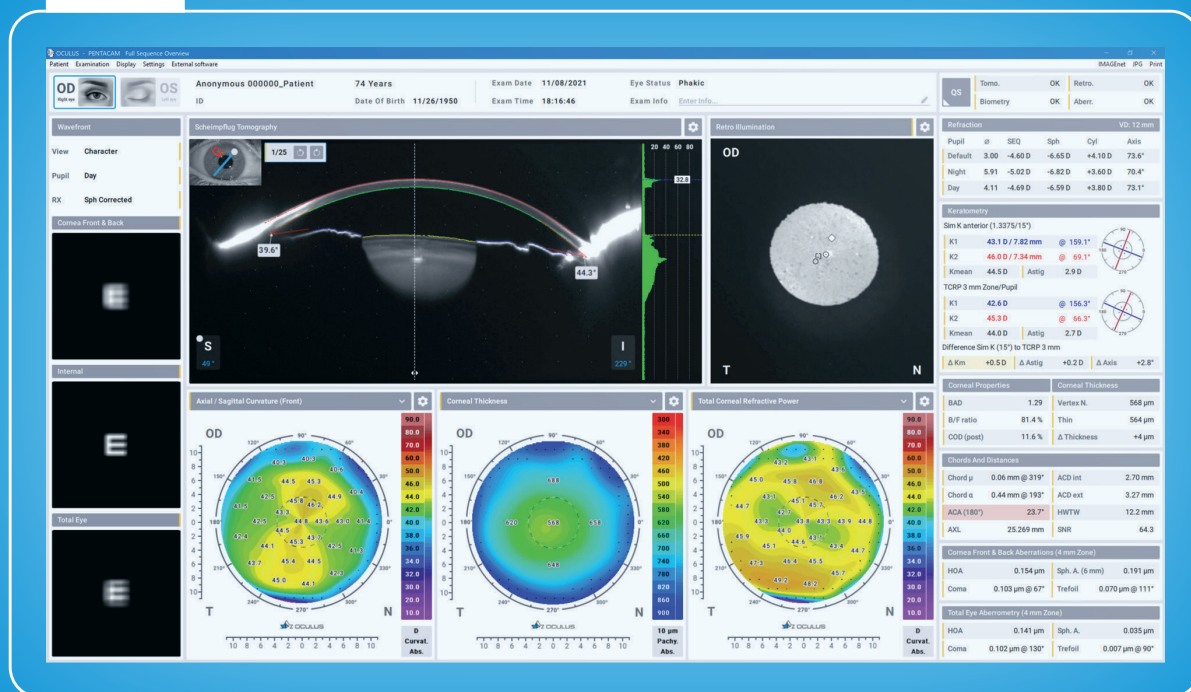
JARED SONNERS

299 Market St. 2 Gateway Center - 4th Floor

Newark NJ 07102

Clarity for You and Your Cataract Patients

NEW



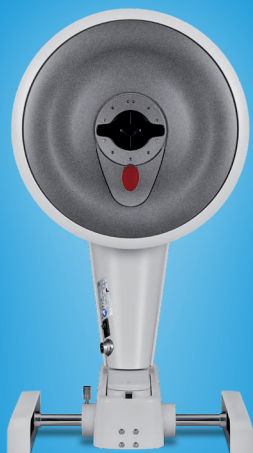Save time



Highlight abnormalities



Educate patients



Streamline Premium IOL Selection & Education with the Pentacam® AXL Wave

Assess corneal optical quality and show patients the benefits of premium IOLs with one display (**Full Sequence Overview**), improving workflow, establishing expectations, and boosting satisfaction with outcomes.

To empower informed decisions and increase premium IOL conversions, learn more at www.pentacam.com



Toll free 888-519-5375
ads@oculususa.com www.oculususa.com



FEATURES

Vol. XXXI, No. 7 • July 2024

Catch Up on the Latest News
Read Review's weekly newsletter
online at reviewofophthalmology.com.

41

IOL Calculation for Unusual Eyes

Using newer-generation formulas is the key for hitting your refractive targets, surgeons say.

Christine Yue Leonard
Senior Associate Editor

32

Point-Counterpoint: LASIK vs. SMILE

LASIK boasts decades of proven outcomes and versatility but SMILE has its own value, experts debate.

Avneet K. Sodhi-Gaur, MD, and Majid Moshirfar, MD

48

Going Green in Ophthalmology

Pharmaceutical companies and surgeons are working towards more sustainable eye care.


Andrew Beers
Associate Editor

53

New Approaches to the Cataract Drug Protocol

Proponents say these protocols are less expensive and improve patient compliance.

Michelle Stephenson
Contributing Editor



DEPARTMENTS

July 2024

3 News

14 EDITOR'S PAGE

Recycled Promises

Walter Bethke
Editor in Chief

17 THE FORUM

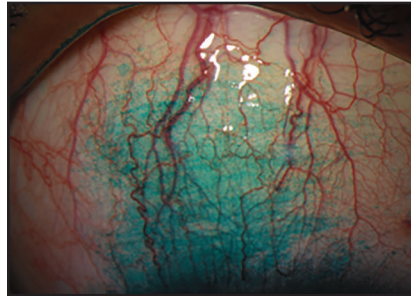
The Holy Grail

Musings on life, medicine and the practice of ophthalmology.

Mark H. Blecher, MD
Chief Medical Editor

18 RESEARCH REVIEW

Prophylactic CTR Use in Surgery on High Myopes



23 CORNEA/ANTERIOR SEGMENT

Keys to Superior Limbic Keratoconjunctivitis

Expert advice for diagnosing and managing this inflammatory condition.

Christine Yue Leonard
Senior Associate Editor

27 REFRACTIVE/CATARACT RUNDOWN

The Moving Target of Hyperopia

Correcting hyperopes comes with its own unique challenges. Here's advice on treatment strategies.

Liz Hunter
Senior Editor

37 AD INDEX

57 GLAUCOMA MANAGEMENT

Exploring Anesthesia Options

The safest approaches for tubes, trabs and MIGS, and how verbal anesthesia can help.

Reza Razeghinejad, MD

60 RETINAL INSIDER

Best Practices for Treating CSCR

Tips for diagnosing and managing this common, yet challenging, condition.

Yu Jeat Chong, MD, Noa Gilead, MD, and Gemmy Cheung, MD

65 WILLS EYE RESIDENT CASE SERIES

An 81-year-old female is referred to Wills Eye Hospital for photophobia and decreasing vision.

Sunidhi Ramesh, MD, and James P. Dunn, MD

VISIT US ON SOCIAL MEDIA

Facebook	facebook.com/RevOphth
twitter/X	twitter.com/RevOphth
Instagram	@revophth

From the makers of the #1-prescribed dry eye brand in Europe*

Covering the spectrum of

Dry Eye Relief

Over-the-counter iVIZIA® lubricant eye drops protect the ocular surface and deliver a unique combination of immediate and long-lasting relief in a **preservative-free** formulation.

- A unique formulation—including povidone (active), trehalose (inactive), and hyaluronic acid (inactive)
- Proprietary, multi-dose preservative-free (MDPF) bottle

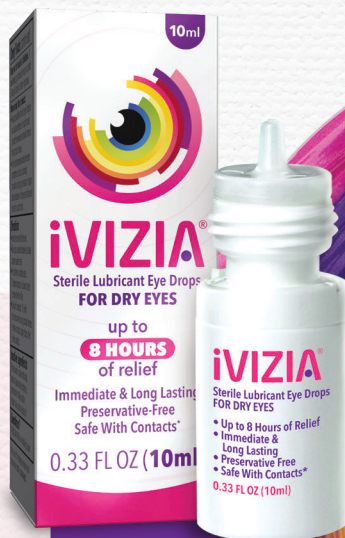Chronic Dry Eye Patient Usage Study†:

Up to
8 hours
of relief

as well as improved comfort during computer work, reading, and driving¹

84%

of users reported iVIZIA worked better than their previous eye drops¹



Safe for use with contact lenses‡



Recommend iVIZIA and request samples by visiting [iVIZIA.com/ECP](https://www.iVIZIA.com/ECP)

Scan here.

*Prescription market data, Dec. 2022 – S01K without cyclosporine.

†In a chronic dry eye patient usage study, participants from a variety of socioeconomic backgrounds answered questions about their experience with iVIZIA lubricant drops. In the study, 203 chronic dry eye patients, 28-80 years old, switched from their dry eye artificial tears to iVIZIA for a month.¹

‡To limit blurriness when using contact lenses, remove contacts, apply drops, then insert contacts.

Reference: 1. Thea Data on File.

Copyright ©2024 Thea Pharma Inc. | All Rights Reserved. | PRC-IED-1030-v4 1.2024

 **Thea**
let's open our eyes

prevent DR onset and progression.” Additionally, “These findings highlight the importance of optimizing

blood pressure control in individuals with diabetes mellitus even prior to the onset of DR,” they noted.

1. Huang BB, Fawzi AA. Hypertension likely drives arteriolar wall thickening in preclinical diabetic retinopathy while diabetes drives wall thickness in clinical retinopathy. *Transl Vis Sci Technol.* 2024;13(6):8.

SLT's Popularity as a First-line Treatment Grows

A recent survey was conducted to assess the practice preferences of ophthalmologists for the initial management of glaucoma.¹ The researchers hypothesized that the multitude of options and accumulated evidence for primary open-angle glaucoma treatment in the past decade will reflect a different preference pattern than reflected in a retrospective claims analysis of data from 2007 to 2014 that selected patients with their first open-angle glaucoma diagnosis in 2010. Their study, which was published in the *Journal of Glaucoma*, revealed that, for the first-line treatment of primary open-angle glaucoma, selective laser trabeculoplasty was more likely to be preferred over topical drops by U.S. physicians who are relatively new in practice, who have a larger glaucoma patient base and who perform more minimally invasive glaucoma surgeries.

The study determined to characterize primary treatment preferences (topical medication vs. laser trabeculoplasty or intracameral sustained release implants) in primary open-angle glaucoma patients and determine factors related to primary intervention selection. A 33-question survey was distributed to an American

Society of Cataract and Refractive Surgery database on treatment choices made by ophthalmologists for POAG. Data collected included country of practice, years of practice, completion of glaucoma fellowship training, type of practice and preference for first-line treatment of POAG. A total of 252/19,246 (1.3 percent) of surveys were returned.

Multiple logistic regression determined that about 73.6 percent of respondents used topical medication as first-line of treatment for POAG, while 26.4 percent preferred to start with laser treatment. Significant variables associated with the selection of laser (vs. drops) are practicing in the US (odds ratio [OR]: 2.85), more recent completion of ophthalmology residency (OR: 1.95), greater volume of MIGS (OR: 1.68) and a glaucoma patient base greater than 25 percent (OR: 2.21).

For doctors preferring laser treatment as the first-line of treatment, the leading indications for using Durysta (bimatoprost SR, Allergan), a prostaglandin analog, are for patients that show intolerance to drops (about 19 percent), are non-responsive to selective laser trabeculoplasty (17 percent) or wish to reduce medication

dependence (17 percent). For doctors preferring drops/topical treatment as the first-line of treatment for primary open-angle glaucoma, the leading indications for using bimatoprost SR are for drop intolerance (about 25 percent), noncompliance (about 26 percent) or as an alternative to medication dependence (17.5 percent).

“It was also observed that the majority of either group, laser or topical drops first, preferred a trabecular meshwork bypass stent in cases of moderate primary open-angle glaucoma and visually significant cataract,” the study authors wrote in their paper. “Although this questionnaire was not designed to ascertain the reason for this finding, it is likely reflective of a shift in preferred practice and community standards based on the relative safety and efficacy of this combined approach.”

“The results of this survey demonstrate a continuing unmet need to educate our colleagues on evidence-based treatment results for primary open-angle glaucoma,” they concluded.

1. Rhee DJ, Sancheti H, Rothman AL, et al. Primary practice patterns for the initial management of open angle glaucoma. *J Glaucoma.* June 17, 2024. [Epub ahead of print].

Surgery for Adult-onset Strabismus Proven Effective

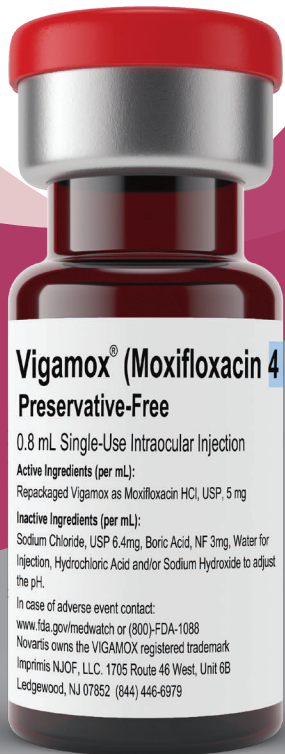Recent studies have shown that the incidence of strabismus in adults is on the rise, possibly attributable to factors such as age-related anatomical changes, increased use of digital devices, certain neurologic conditions or systemic diseases and improved

diagnostic techniques and awareness among healthcare professionals. The estimated lifetime risk of developing adult-onset strabismus currently hovers around 4 percent, with esotropia accounting for about a quarter of these cases.

Most previous studies on esotropia grouped all adults together, which complicates surgical outcome analysis considering the pathophysiology of esotropia may differ in younger and

(Continued on p. 16)

Coming Soon!



Repackaged **Vigamox**[®]

(moxifloxacin HCl ophthalmic solution) 0.5% as base*


Repackaged Vigamox[®] is conveniently packaged in a sterile, single-use injectable vial.

Moxifloxacin Single-Use Vial

Accessible through our
503B FDA-Registered
Outsourcing Facility

\$490
(20 vials)
5mg/mL (4mg/0.8mL)

SCAN TO
PRE-ORDER



*For professional use only. ImprimisRx specializes in customizing medications to meet unique patient and practitioner needs. No compounded medication is reviewed by the FDA for safety and efficacy. ImprimisRx does not compound essential copies of commercially available products. These ingredients carry risks. Visit imprimisrx.com/productinformation for full product details. References available upon request. Novartis owns the VIGAMOX registered trademark and the VIGAMOX logo trademark. Harrow IP, LLC owns the ImprimisRx logo trademark. ©2024 ImprimisRx. All Rights Reserved. OI-00003 5/24

imprimis ^{Rx}
A HARROW COMPANY

EDITORIAL STAFF

Editor in Chief
Walter Bethke

(610) 492-1024
wbethke@jobson.com

Senior Editor
Liz Hunter

(610) 492-1025
ehunter@jobson.com

Senior Associate Editor

Christine Leonard

(610) 492-1008
cleonard@jobson.com

Associate Editor
Leanne Spiegle

(610) 492-1026
lspiegle@jobson.com

Associate Editor
Andrew Beers

(570) 856-5156
abeers@jobson.com

Chief Medical Editor
Mark H. Blecher, MD

Art Director

Lynne O'Connor

(267) 566-6007
lyoconnor@jobson.com

Graphic Designer
Jaine Kopala

(609) 969-0694
jkopala@jobson.com

Business Offices

19 Campus Boulevard, Suite 101
Newtown Square, PA 19073
(610) 492-1000
Fax: (610) 492-1039

Subscription inquiries:

United States – (877) 529-1746
Outside U.S. – (845) 267-3065
E-mail:

revophthalmology@cambeywest.com
Website: www.reviewofophthalmology.com



WALTER C. BETHKE, EDITOR IN CHIEF

EDITOR'S PAGE

Recycled Promises

While reading this month's feature on sustainability in ophthalmology (p. 48), it was encouraging to see what the specialty is doing to "go green." Unfortunately, multiple recent reports call into question the validity of plastic recycling and, even worse, suggest that the by-products of recycling plastics may be doing harm to us. One step forward, two steps back.

In one scathing report, released in February by The Center for Climate Integrity,¹ the authors note that, "The vast majority of these plastics cannot be 'recycled'—meaning they cannot be collected, processed, and remanufactured into new products.² As of 2021, the U.S. recycling rate for plastic is estimated to be only 5 to 6 percent ...³ Despite decades of industry promises, plastic recycling has failed to become a reality due to long-known technical and economic limitations."⁴

To make matters worse, plastic recycling plants appear to be releasing microplastics (MP), which have been proven to be a danger to marine life and may cause health problems in humans. A recent article in the online U.K. journal *Quillette*, authored by *Review* alum, Frank Celia, took a closer look at the problem.

The report describes a recent journal article that measured the amount of MP released by a recycling facility in the U.K.⁵ The researchers were surprised to find that the facility was releasing 75 billion particles of MP per cubic meter. Even with a new filtration system in place, the discharge amounted to 1,366 metric tons per year. "More troubling was the size of the microplastics ..." the article states.

"... In some samples, they found 95 percent of particles were under ten microns (the size of a human blood cell) and 85 percent were under five microns. Ingesting particles smaller than 10 microns is known to be hazardous to marine life, and scientists believe it may pose risks to humans as well. Further, Brown believes that numerous particles smaller than 1.6 microns—many of which are nano-plastics—probably eluded measurement altogether."⁵ They also found high levels of MP in the air around the plant of a size that can enter the lungs and cause disease. Finally, in one of the more shocking figures discussed in the article, on a global scale, plastic recycling could be releasing 2 million tons of MP waste per year, which would represent two-thirds of the global total.

Obviously, I have no ready answer for the problem, though continuing on the current course doesn't seem viable. Ultimately, as one report says, the petrochemical bloc will need to stop backing plastic recycling and allow us to move to other solutions that are "currently out of reach." Otherwise, we just get recycled promises.

— Walter Bethke
Editor in Chief

1. Allen D, Linsley C, Spoelman N, Johl A. The fraud of plastic recycling. <https://climateintegrity.org/uploads/media/Fraud-of-Plastic-Recycling-2024.pdf>

2. U.S. EPA, The U.S. Recycling System. <https://www.epa.gov/circulareconomy/us-recycling-system>

3. Beyond Plastics & The Last Beach Cleanup, The Real Truth About the U.S. Plastics Recycling Rate 3 (2022). <https://tinyurl.com/mvy2w9xh>


4. Circular Claims Fall Flat: Comprehensive U.S. Survey of Plastics Recyclability 7 (2020). <https://www.greenpeace.org/usa/wp-content/uploads/2020/02/Greenpeace-Report-Circular-Claims-Fall-Flat.pdf>

5. Celia F. Recycling plastics is a dangerous waste of time. <https://quillette.com/2024/06/17/recycling-plastic-is-a-dangerous-waste-of-time-microplastics-health/>




CLAREON®
COLLECTION

THE CLAREON® COLLECTION PROVIDES MORE OPTIONS FOR MORE PATIENTS.



CLAREON® VIVITY® The first and only non-diffractive wavefront shaping PCIOL with exceptional clarity,^{1,2*} monofocal-quality distance visual acuity, excellent intermediate vision, and functional near vision.^{3†}



CLAREON® PANOPTIX®
A full range of vision with exceptional clarity that lasts.^{4,5*}

Alcon's unique PCIOL portfolio helps you offer patients full range of vision with both diffractive and non-diffractive IOLs.

Learn more at [ClareonIOL.com](https://www.clareoniol.com)

* Defined as modified Miyata grade 0, <25mv/mm² over 3 years (n=138), and over 9 years (n=20), respectively. PCIOL=Presbyopia Correcting IOL.
† Results from a prospective, randomized, parallel group, subject- and assessor-masked, multisite trial of 107 subjects bilaterally implanted with the AcrySof® IQ Vivity® Extended Vision IOL and 113 with the AcrySof® IQ IOL with 6 months follow-up.
‡ Snellen VA was converted from logMAR VA. A Snellen notation of 20/20-2 or better indicates a logMAR VA of 0.04 or better, which means 3 or more of the 5 ETDRS chart letters in the line were identified correctly.

IMPORTANT PRODUCT INFORMATION: CLAREON® FAMILY OF IOLS

CAUTION: Federal law restricts these devices to sale by or on the order of a physician.

INDICATION: The family of **Clareon® intraocular lenses (IOLs)** includes the **Clareon® Aspheric Hydrophobic Acrylic** and **Clareon® Aspheric Toric IOLs**, the **Clareon® PanOptix® Trifocal Hydrophobic IOL**, **Clareon® PanOptix® Toric**, **Clareon® Vivivity® Extended Vision Hydrophobic Posterior Chamber IOL** and **Clareon® Vivivity® Toric IOLs**. Each of these IOLs is indicated for visual correction of aphakia in adult patients following cataract surgery. In addition, the **Clareon® Toric IOLs** are indicated to correct pre-existing corneal astigmatism at the time of cataract surgery. The **Clareon® PanOptix®** lens mitigates the effects of presbyopia by providing improved intermediate and near visual acuity, while maintaining comparable distance visual acuity with a reduced need for eyeglasses, compared to a monofocal IOL. The **Clareon® Vivivity®** lens mitigates the effects of presbyopia by providing an extended depth of focus. Compared to an aspheric monofocal IOL, the lens provides improved intermediate and near visual acuity, while maintaining comparable distance visual acuity. All of these IOLs are intended for placement in the capsular bag.

WARNINGS / PRECAUTIONS:

General cautions for all Clareon® IOLs: Careful preoperative evaluation and sound clinical judgment should be used by the surgeon to decide the risk/benefit ratio before implanting any IOL in a patient with any of the conditions described in the Directions for Use that accompany each IOL. Physicians should target emmetropia, and ensure that IOL centration is achieved.

For the **Clareon® Aspheric Toric**, **PanOptix® Toric** and **Vivivity® Toric IOLs**, the lens should not be implanted if the posterior capsule is ruptured, if the zonules are damaged, or if a primary posterior capsulotomy is planned. Rotation can reduce astigmatic correction; if necessary lens repositioning should occur as early as possible prior to lens encapsulation.

For the **Clareon® PanOptix® IOL**, some visual effects may be expected due to the superposition of focused and unfocused multiple images. These may include some perceptions of halos or starbursts, as well as other visual symptoms. As with other multifocal IOLs, there is a possibility that visual symptoms may be significant enough that the patient will request explant of the multifocal IOL. A reduction in contrast sensitivity as compared to a monofocal IOL may be experienced by some patients and may be more prevalent in low lighting conditions. Therefore, patients implanted with multifocal IOLs should exercise caution when driving at night or in poor visibility conditions. Patients should be advised that unexpected outcomes could lead to continued spectacle dependence or the need for secondary surgical intervention (e.g., intraocular lens replacement or repositioning). As with other multifocal IOLs, patients may need glasses when reading small print or looking at small objects. Posterior capsule opacification (PCO), may significantly affect the vision of patients with multifocal IOLs sooner in its progression than patients with monofocal IOLs.

For the **Clareon® Vivivity® IOL**, most patients implanted with the **Vivivity® IOL** are likely to experience significant loss of contrast sensitivity as compared to a monofocal IOL. Therefore, it is essential that prospective patients be fully informed of this risk before giving their consent for implantation of the **Clareon® Vivivity® IOL**. In addition, patients should be warned that they will need to exercise caution when engaging in activities that require good vision in dimly lit environments, such as driving at night or in poor visibility conditions, especially in the presence of oncoming traffic. It is possible to experience very bothersome visual disturbances, significant enough that the patient could request explant of the IOL. In the parent AcrySof® IQ Vivivity® IOL clinical study, 1% to 2% of AcrySof® IQ Vivivity® IOL patients reported very bothersome starbursts, halos, blurred vision, or dark area visual disturbances; however, no explants were reported.

Prior to surgery, physicians should provide prospective patients with a copy of the Patient Information Brochure available from Alcon informing them of possible risks and benefits associated with these IOLs.

ATTENTION: Reference the Directions for Use labeling for each IOL for a complete listing of indications, warnings and precautions.

REFERENCES: 1. Oshika T, Fujita Y, Inamura M, Miyata K. Mid-term and long-term clinical assessments of a new 1-piece hydrophobic acrylic IOL with hydroxyethyl methacrylate. *J Cataract Refract Surg.* 2020 May;46(5):682-687. 2. Maxwell A, Suryakumar R. Long-term effectiveness and safety of a three-piece acrylic hydrophobic intraocular lens modified with hydroxyethyl-methacrylate: an open-label, 3-year follow-up study. *Clin Ophthalmol.* 2018;12:2031-2037. 3. Clareon® Vivivity® Extended Vision Hydrophobic IOL (CNWET0) Directions for Use – US. 4. Clareon® PanOptix® Trifocal Hydrophobic Acrylic IOL Model: CNWTO DFU. 5. Lehmann R, Maxwell A, Lubeck DM, Fong R, Walters TR, Fakadej A. Effectiveness and Safety of the Clareon® Monofocal Intraocular Lens: Outcomes from a 12-Month Single-Arm Clinical Study in a Large Sample. *Clin Ophthalmol.* 2021;15:1647-1657. Published 2021 Apr 20.

(Continued from p. 12)

older individuals. One type of esotropia occurring almost exclusively in younger adults is acute acquired comitant esotropia, associated with a moderate to large angle, diplopia, full ocular motility and lack of neurologic or anatomic etiology. In a new study, researchers attempted to analyze how certain characteristics, such as age, affect surgical outcomes in this patient population.¹

The retrospective case series analyzed medical records of adults aged 18 to 60 who underwent strabismus surgery at a tertiary care hospital for comitant non-accommodative esotropia. The majority of patients were female (64 percent) and the mean age was 36.7 years. Nearly three-quarters (72 percent) of the cohort were myopic and 80.3 percent had diplopia. To distinguish between etiologies, patients were classified into three groups based on the disparity between near-distance angles of deviation: basic esotropia (ETBA), esotropia divergence insufficiency pattern (ETDI) and esotropia convergence excess pattern (ETCE).

The study found that the ETCE group had the largest mean deviations at both distance and near, while the ETBA group had the largest ranges at both distances. The two most popular surgical procedures, performed at equal frequency (both 48 percent of the cohort), were bilateral medial rectus recession (BMR) and unilateral recess-resect (R&R). The surgical outcome analysis showed that the latter procedure had higher motor and sensory success rates than BMR. However, all groups achieved excellent surgical success, regardless of surgical approach or esotropia pattern.

Though the pathophysiology of different patterns of esotropia remains largely unclear, one unique finding the researchers highlighted in their paper, published in the *American Journal of Ophthalmology*, “was the presence of anisometropia in approximately 13 percent of the cases. It is possible the disparate accommodative effort may be an unrecognized or underrecognized contributor to the development of esotropia.”

By analyzing demographic and clinical information from patients’ medical records, the researchers were able to characterize the typical patient with acute comitant esotropia undergoing surgery. “These patients tend to be younger adults, female and have moderate myopia,” as well as present with moderate angle basic type esodeviations, the researchers summarized in their paper. They added, “Surgical success in this group of patients is high regarding both motor and sensory outcomes,” which agrees with prior literature. ◀

1. Cavuoto KM, Tibi C, Rosa PR, Capo H. Characteristics and surgical outcomes of comitant esotropia in an adult population between 18 and 60 years old. *Am J Ophthalmol.* 2024. [Epub ahead of print].



The Holy Grail

Musings on life, medicine and the practice of ophthalmology.

MARK H. BLECHER, MD
CHIEF MEDICAL EDITOR

An old man gets hit by a car. He's lying in the street and a woman runs over and puts her coat under his head. She asks, "Are you comfortable?"

He replies, "I make a living."

I'm here all week folks! Jokes aside, are YOU comfortable? Do you make a living or do you make a fortune? Who decides the difference? One person's comfortable life is another's bare existence. It's all relative and it's all personal. Which is great. I totally support everyone working for the resources they need to achieve their definition of comfortable. However over-the-top it may appear to you. Or do I? Is there a point at which it's not really understandable, much less realistic and necessary? The answer is yes, but I doubt we'll reach a consensus on what that point is. OK, actually we can. No one, and I literally mean no one, thinks Elon Musk needs or should have that much money. So why does he do it? I think a lot of us have been disabused of the notion that he does it to better mankind. And it's too easy to say it's greed, a word that covers a lot of ground—and motivations. It's more complex than that and often comes subtly wrapped in less

pejorative terms.

I work with and have met a number of people who chase the dollar not because they actually have a plan for it, such as a bigger house or a nicer car, but because they can. That, or they feel the need to. It's that act of achieving, of raising the bar over and over



again. It's the pursuit itself that has enthralled them. In addition to a sense of accomplishment, they get a high. I would posit this isn't entirely unlike a drug high. It's a short-acting one that drives them to repeat and repeat. It's the finance version of cocaine. It's a phenomenon that seems to occur in a subset of people where the more money they have, the more they have to have.

People of modest means work hard because they have to, to pay their bills for starters. They may like their work,

or they might like to work. At more stratospheric income levels, relatively speaking of course, it takes on a life of its own. Or, more correctly, it owns its owner. Again, like an addiction. It's an addiction to the process and the feeling it brings. It doesn't bring satisfaction, but a high based on an abstract concept.

I probably shouldn't be so demeaning of feeling "high." Or of extreme happiness either. We all should be chasing the latter. If constantly pushing to make more and more money, to accumulate more and more wealth simply for the hell of it makes you feel that way, why should I care? Because, as with drug addiction, it takes over your life. It changes you in ways obvious and subtle. It makes you care less about the world around you and more about the world inside you—your head, your needs. It's not pretty. It can be tough for that person to see that part of themselves, see how that colors their personality and their interactions with others. Many years ago I had a couple of friends who developed a meth addiction. They thought they were in control, that it didn't make them bad or less-civilized

people. But it did. They were clueless. And while the analogy may be perhaps a tad over the top, some people who are consumed with winning every last dollar because doing so makes them feel good aren't that dissimilar. They can cloak it in their dedication to capitalism. Or exceptionalism. Or they may call it a reward for working harder than everyone else. And it may be, in part, a little of all of that. However, it's often more abstract and instead it becomes a game of chasing a carrot they will never get. ◀

Prophylactic CTR Use in Surgery on High Myopes

Scientists assessed the effectiveness of prophylactic capsular tension ring implantation during cataract surgery in highly myopic eyes, as part of a prospective cohort study.

Consecutive highly myopic patients treated with cataract surgery were recruited and randomized to undergo CTR implantation or not. The outcomes compared between the two groups included axial lens position (ALP), intraocular lens decentration and tilt, area of anterior capsule opening, severity of anterior capsular opacification and posterior capsular opacification at one year after surgery.

A total of 55 highly myopic eyes with CTRs implanted and 55 without were included in the analysis. Here are some of the findings at one year after surgery:

- No significant differences were detected between CTR and non-CTR groups for the mean ALP, IOL decentration or tilt (all $p > 0.05$).

- The CTR group had a significantly larger area of anterior capsule opening ($23.62 \pm 3.30 \text{ mm}^2$ vs. $21.85 \pm 2.30 \text{ mm}^2$; $p = 0.003$), and less severe ACO ($p = 0.033$) and PCO (PCO-3 mm: 0.06 ± 0.13 vs. 0.13 ± 0.20 ; $p = 0.038$; PCO-C: 0.15 ± 0.18 vs. 0.25 ± 0.26 , $p = 0.026$) than the non-CTR group.

- The corrected distance visual acuity, prediction error and higher-order aberrations didn't differ between the two groups (all $p > 0.05$).

Scientists wrote, in highly myopic

eyes, although prophylactic capsular tension ring implantation reduced the severity of capsular contraction and opacification, it didn't significantly affect postoperative IOL stability or visual outcomes.

J Cataract Refract Surg 2024; May 29. [Epub ahead of print].
Hu X, Qi J, Cheng K, et al.

Accuracy of New IOL Formulas

Scientists evaluated the accuracy of a new intraocular lens power calculation formula using segmental refractive index-based axial length (AL), as part of a retrospective observational study.

The study included patients undergoing preoperative examination for cataract surgery with the new Barrett True AL (BTAL) and Emmetropia Verifying Optical (EVO) formulas using segmental refractive index, and conventional Barrett Universal II (BU II) formula using equivalent refractive index. The predicted refractive error of each formula was compared with the postoperative subjective spherical equivalent.

Here are some of the findings:

- The mean prediction error in the short AL group ($\leq 22 \text{ mm}$; 44 eyes) was:

- $-0.32 \pm 0.40 \text{ D}$ for BU II;
- $-0.22 \pm 0.37 \text{ D}$ for BTAL; and
- $-0.10 \pm 0.37 \text{ D}$ for EVO

($p < 0.0001$).

- Mean prediction error in the long AL group ($\geq 26 \text{ mm}$; 92 eyes) was:

- $-0.01 \pm 0.32 \text{ D}$ for BU II;
- $-0.04 \pm 0.32 \text{ D}$ for BTAL; and
- $-0.09 \pm 0.32 \text{ D}$ for EVO

($p < 0.0001$).

- In patients with an AL $\geq 28 \text{ mm}$, BU II showed a myopic trend in 57.1 percent of cases, while BTAL and EVO showed a hyperopic trend in 71.4 percent.

- The mean prediction error for patients with an AL $\geq 28 \text{ mm}$ was:
 - $-0.16 \pm 0.34 \text{ D}$ for BU II;
 - $-0.18 \pm 0.33 \text{ D}$ for BTAL; and
 - $-0.16 \pm 0.32 \text{ D}$ for EVO

($p < 0.0001$).

Scientists reported the new Emmetropia Verifying Optical and Barrett True AL formulas showed higher accuracy than Barrett Universal II in short eyes, while no difference was found in long eyes.

J Cataract Refract Surg 2024; May 1. [Epub ahead of print].
Kato Y, Ayaki M, Tamaoki A, et al.

Different Ways to Assess GA Analyzed

Investigators compared the intermodality and -reader agreement of manual and semiautomated geographic atrophy area measurements in eyes with GA due to age-related macular degeneration using conventional blue and ultra-widefield (UWF) green light fundus autofluorescence (FAF) systems.

FAF images of eyes with GA were obtained during a single visit using the Spectralis HRA+OCT2 device and the Optos California device. Images were exported for masked analysis by two independent masked graders. The area of the GA lesions was segmented and quantified (mm^2) with a fully manual approach while the lesions were outlined using Optos Advance and Heidelberg Eye Explorer (HEYEX) software. For the Heidelberg blue FAF images, GA lesions were also measured using the instrument's semi-automated software (Region Finder 2.6.4). To compare modalities/grading, mean

TECNIS
Odyssey™ IOL

Precise vision. Every distance. Any lighting.

Elevate your practice with TECNIS Odyssey™, the high-quality*, continuous full visual range IOL^{1§**}. Discover its optimized, freeform surface designed to deliver:

- High tolerance to refractive error²
- Better dysphotopsia profile³
- Unmatched range of vision⁴
- Best-in-class contrast⁵⁻⁶

Johnson & Johnson

LEARN MORE



*Based on bench testing

**According to ISO 11979-7:2024, based on the clinical study of the parent IOL.

¹Compared to PanOptix® based on objective pre-clinical halo performance

²Compared to PanOptix® based on bench testing

³Compared to leading competitor full range of vision IOLs based on bench testing

⁵20/25 or better based on bench testing

REFERENCES:

1. Data on File. 2024DOF4002 2. Data on File. DOF2023CT4052 3. Data on File. 2024DOF4005 4. Data on File. DOF2023CT4023 5. Data on File. DOF2023CT4007 6. Data on File. DOF20190TH4002

INDICATIONS AND IMPORTANT SAFETY INFORMATION FOR TECNIS ODYSSEY™ IOL WITH TECNIS SIMPLICITY™ DELIVERY SYSTEM, MODEL DRN00V.

Rx Only.

INDICATIONS: The TECNIS SIMPLICITY™ Delivery System is used to fold and assist in inserting the TECNIS Odyssey™ IOL, which is indicated for primary implantation for the visual correction of aphakia in adult patients, with less than 1 diopter of pre-existing corneal astigmatism, in whom a cataractous lens has been removed. Compared to an aspheric monofocal lens, the TECNIS Odyssey™ IOLs mitigate the effects of presbyopia by providing improved visual acuity at intermediate and near distances to reduce eyeglass wear, while maintaining comparable distance visual acuity. The lens is intended for capsular bag placement only.

WARNINGS: Intraocular lenses may exacerbate an existing condition, may interfere with diagnosis or treatment of a condition or may pose an unreasonable risk to the eyesight of patients. Patients should have well-defined visual needs and be informed of possible visual effects (such as a perception of halo, starburst or glare around lights), which may be expected in nighttime or poor visibility conditions. Patients may perceive these visual effects as bothersome, which, on rare occasions, may be significant enough for the patient to request removal of the IOL. The physician should carefully weigh the potential risks and benefits for each patient. Patients with a predicted postoperative residual astigmatism greater than 1.0 diopter may not fully benefit in terms of reducing spectacle wear. The lens and delivery system should be discarded if the lens has been folded within the cartridge for more than 10 minutes. Not doing so may result in the lens being stuck in the cartridge. Do not attempt to disassemble, modify, or alter the delivery system or any of its components, as this can significantly affect the function and/or structural integrity of the design.

PRECAUTIONS: Interpret results with caution when using autorefractors or wavefront aberrometers that utilize infrared light, or when performing a duochrome test. Confirmation of refraction with maximum plus manifest refraction technique is strongly recommended. The ability to perform some eye treatments (e.g., retinal photocoagulation) may be affected by the IOL optical design. The surgeon should target emmetropia, as this lens is designed for optimum visual performance when emmetropia is achieved. The TECNIS Odyssey™ IOLs should not be placed in the ciliary sulcus. Patients with a predicted postoperative astigmatism greater than 1.0 D may not be suitable candidates for implantation with the TECNIS Odyssey™ IOLs, as they may not obtain the benefits of reduced spectacle wear or improved intermediate and near vision seen in patients with lower predicted postoperative astigmatism.

ATTENTION: Reference the Directions for Use for a complete listing of Indications and Important Safety Information.

Third party trademarks are the property of their respective owners.

© Johnson & Johnson and its affiliates 2024 | 2024PP11319

values of the two graders were used. Intraclass correlation coefficients (ICC) were computed to judge the agreement between graders.

A total of 72 eyes of 50 patients were included. Here are some of the findings:

- Nearly perfect agreement was found between graders for the measurement of GA area for all three modalities (ICC=0.996 for manual Optos Advance, 0.996 for manual Heidelberg HEYEX and 0.995 for Heidelberg Region Finder).
- The measurement of GA area was strongly correlated between modalities, with Spearman correlation coefficients of:
 - 0.985 ($p < 0.001$) between manual Heidelberg and manual Optos; 0.991 ($p < 0.001$) for Region Finder vs. manual Heidelberg; and
 - 0.985 ($p < 0.001$) for Region Finder vs. manual Optos.
- The absolute mean area differences were ($p < 0.001$ for all three):
 - 1.61 mm² for Heidelberg manual vs. Region Finder;
 - 0.90 mm² for manual Optos vs. Region Finder; and
 - 0.71 mm² for manual Optos vs. manual Heidelberg.

Investigators observed excellent inter-reader agreement for geographic atrophy measurement using either 30-degree blue FAF or UWF green FAF, establishing the reliability of UWF imaging for macular GA assessment. However, though the absolute measurements between devices were strongly correlated, they differed significantly, highlighting the importance of using the same device for a given patient for the duration of a study.

Ophthalmol Retina 2024; Apr 24. [Epub ahead of print].
Abbasgholizadeh R, Habibi A, Emamverdi M, et al.

Deep Learning for Analyzing Glaucoma Progression

Researchers developed a deep learning

(DL) algorithm to detect glaucoma progression using optical coherence tomography images, in the absence of a reference standard, as part of a retrospective cohort study.

Glaucomatous and healthy eyes with ≥ 5 reliable peripapillary OCT (Spectralis, Heidelberg) circle scans were included. A time-series learning model, called Noise Positive-Unlabeled (Noise-PU) DL, was developed to classify whether sequences of OCT B-scans showed glaucoma progression. The model used two learning schemes, one to identify age-related changes by differentiating test sequences from glaucoma vs. healthy eyes, and the other to identify test-retest variability based on scrambled OCTs of glaucoma eyes. Both models' bases were convolutional neural networks (CNN) and long short-term memory (LSTM) networks combined to form a CNN-LSTM model. Model features were trained to identify glaucoma progression, accounting for age-related loss. The DL model's outcomes were compared with ordinary least squares regression of retinal nerve fiber layer thickness over time, matched for specificity. The researchers used the hit ratio as a proxy for sensitivity.

A total of 8,785 follow-up sequences of five consecutive OCT tests from 3,253 eyes (1,859 subjects) were included. Mean follow-up time was 3.5 ± 1.6 years. In the test sample, the hit ratio of the DL method was 0.498; CI, 0.470 to 0.526; and the hit ratio of the ordinary least squares was 0.284; CI, 0.258 to 0.309 ($p < 0.001$) when the specificities were equalized to 95 percent.

Researchers wrote that a deep learning model was able to identify longitudinal glaucomatous structural changes in OCT B-scans using a surrogate reference standard for progression.

Am J Ophthalmol. 2024 May 2. [Epub ahead of print].
Mandal S, Jammal AA, Malek D, et al.

Image-guidance Systems Used With FLACS Studied

Scientists evaluated the effectiveness of corneal astigmatism correction using the Alcon Image Guidance system vs. manual marking in the orientation of femtosecond laser-assisted astigmatic keratotomy incisions, as part of a retrospective review of patients undergoing femtosecond laser-assisted cataract surgery from January 2018 to June 2022.

Patients who underwent FLACS with and without image guidance (IG) were investigated. Variables including preoperative K values, cylinder, spherical equivalent (SE) and visual acuity were collected, as well as the cyclorotation angle delta registered by image guidance, postoperative refractive cylinder, SE and VA. The primary outcome was postoperative refractive cylinder in patients with IG vs. those without IG.

A total of 160 eyes were included; 103 eyes had IG, and 57 eyes didn't.

- Postoperative cylinder was similar in those with image guidance (0.31 ± 0.36 D) compared to those without image guidance (0.31 ± 0.37 D) ($p = 0.97$).
- Average cyclorotation in the image guidance group was 2.82 ± 3.03 degrees.
- When cyclorotation was stratified into three groups (<2.8 degrees, 2.8 to 8.5 degrees, >8.5 degrees), no differences were found in postoperative refractive cylinder ($p = 0.35$).

Scientists wrote that patients who underwent femtosecond laser-assisted cataract surgery with image guidance had similar postoperative cylinder outcomes compared to those without image guidance.

The researchers noted the findings suggested the accommodation of cyclotorsion using an advanced image guidance system in FLACS was similar to that obtained with manual marking techniques in cataract patients having 2 D or less of astigmatism corrected. ◀

J Cataract Refract Surg 2024; May 9. [Epub ahead of print].
Yalamanchili SP, Cleary SM, Sell SS, et al.

INTRODUCING

THE RYZUMVI™ DIFFERENCE

Reverse dilation and reimagine
the post-dilation experience
for patients.^{1,2}

REDEFINE
the PATIENT
EXPERIENCE
POST-DILATION



 **Ryzumvi**™
(phentolamine
ophthalmic solution) 0.75%



1

RYZUMVI is the first and only relatively non-selective alpha-1 and alpha-2 adrenergic antagonist approved to reverse pharmacologically-induced mydriasis.¹



RYZUMVI reversibly binds to alpha-1 adrenergic receptors on the radial iris dilator muscle, thereby reducing pupil diameter, and indirectly reverses mydriasis induced by muscarinic antagonist effects on the iris sphincter muscle.¹



The onset of action after administration of RYZUMVI generally occurs in 30 minutes, with the maximal effect seen in 60 to 90 minutes, and the effect lasting at least 24 hours.¹

INDICATION

RYZUMVI™ (phentolamine ophthalmic solution) 0.75% is indicated for the treatment of pharmacologically-induced mydriasis produced by adrenergic agonists (e.g., phenylephrine) or parasympatholytic (e.g., tropicamide) agents.

IMPORTANT SAFETY INFORMATION

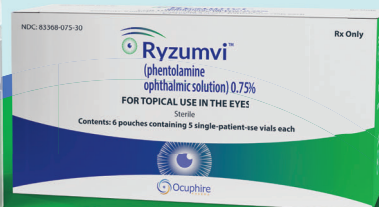
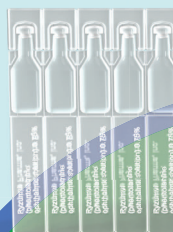Warnings and Precautions

- **Uveitis:** RYZUMVI is not recommended to be used in patients with active ocular inflammation (e.g., iritis).
- **Potential for Eye Injury or Contamination:** To avoid the potential for eye injury or contamination, care should be taken to avoid touching the vial tip to the eye or to any other surface.
- **Use with Contact Lenses:** Contact lens wearers should be advised to remove their lenses prior to the instillation of RYZUMVI and wait 10 minutes after dosing before reinserting their contact lenses.

Adverse Reactions

The most common adverse reactions that have been reported are instillation site discomfort (16%), conjunctival hyperemia (12%), and dysgeusia (6%).

Please see Brief Summary of Prescribing Information on the adjacent page and the full Prescribing Information at RYZUMVI.com.



Visit RYZUMVI.com



Ryzumvi™

(phentolamine
ophthalmic solution) 0.75%

BRIEF SUMMARY: Consult the full Prescribing Information for complete product information available at www.RYZUMVI.com

INDICATIONS AND USAGE: RYZUMVI is indicated for the treatment of pharmacologically-induced mydriasis produced by adrenergic agonists (e.g., phenylephrine) or parasympatholytic (e.g., tropicamide) agents.

CONTRAINDICATIONS: None.

WARNINGS AND PRECAUTIONS

- **Uveitis:** RYZUMVI is not recommended when active ocular inflammation (e.g., iritis) is present because adhesions (synechiae) may form between the iris and the lens.
- **Potential for Eye Injury or Contamination:** To avoid the potential for eye injury or contamination, care should be taken to avoid touching the vial tip to the eye or to any other surface.
- **Use with Contact Lenses:** Contact lens wearers should be advised to remove their lenses prior to the instillation of RYZUMVI and wait 10 minutes after dosing before reinserting their contact lenses.

ADVERSE REACTIONS

Clinical Trials Experience: Because clinical trials are conducted under widely varying conditions, adverse reaction rates observed in the clinical trials of a drug cannot be directly compared to rates in the clinical trials of another drug and may not reflect the rates observed in practice.

RYZUMVI was evaluated in 642 subjects in clinical trials across various subject populations. The most common ocular adverse reactions reported in >5% of subjects were instillation site discomfort including pain, stinging, and burning (16%) and conjunctival hyperemia (12%). The only non-ocular adverse reaction reported in >5% of subjects was dysgeusia (6%).

USE IN SPECIFIC POPULATIONS

Pregnancy: *Risk Summary:* There are no available data with RYZUMVI administration in pregnant women to inform a drug-associated risk. In animal toxicology studies, when phentolamine was administered orally to pregnant mice and rats during the period of organogenesis skeletal immaturity and decreased growth was observed in the offspring at doses at least 24-times the recommended clinical dose. Additionally, a lower rate of implantation was seen in pregnant rats treated with phentolamine administered at least 60-times the recommended clinical dose. No malformations or embryofetal deaths were observed in the offspring of pregnant mice, rats, and rabbits administered phentolamine during the period of organogenesis at doses of at least 24-, 60-, and 20-times, respectively, the recommended clinical dose (see Data). RYZUMVI should only be used during pregnancy if the potential benefit justifies the potential risk to the fetus.

Data Animal Data Oral administration of phentolamine to pregnant rats and mice at doses at least 24-times the recommended clinical dose (based on a body weight per surface area (mg/m²) comparison with a 60-kg human)

References: 1. RYZUMVI (phentolamine ophthalmic solution). Prescribing Information. Ocuphire. 2. Boyd K. Mendoza O. What are dilating eye drops? American Academy of Ophthalmology. Available at: <https://www.aao.org/eye-health/drugs/dilating-eyedrops>. Accessed February 8, 2024.

resulted in slightly decreased growth and slight skeletal immaturity of the fetuses. Immaturity was manifested by increased incidence of incomplete or unossified calcanei and phalangeal nuclei of the hind limb and of incompletely ossified sternebrae. At oral phentolamine doses at least 60-times the recommended clinical dose (based on a mg/m² comparison with a 60-kg human), a slightly lower rate of implantation was found in rats. Phentolamine did not affect embryonic or fetal development in rabbits at oral doses at least 20-times the recommended dose (based on a mg/m² comparison with a 60-kg human). No malformations or embryofetal deaths were observed in the rat, mouse or rabbit studies.

Lactation: *Risk Summary:* There is no information regarding the presence of phentolamine in human milk, the effects on the breastfed infants, or the effects on milk production during lactation to inform risk of phentolamine ophthalmic solution 0.75% to an infant. The developmental and health benefits of breastfeeding should be considered along with the mother's clinical need for RYZUMVI and any potential adverse effects on the breastfed child from RYZUMVI.

Pediatric Use: The safety and effectiveness of RYZUMVI have been established in pediatric patients aged 3 to 17 years. No overall differences have been observed between pediatric and adult subjects.

Geriatric Use: No overall differences in safety and effectiveness have been observed between elderly and younger adult subjects.

OVERDOSAGE

No deaths due to acute poisoning with phentolamine have been reported. Overdosage with parenterally administered phentolamine is characterized chiefly by cardiovascular disturbances, such as arrhythmias, tachycardia, hypotension, and possibly shock. In addition, the following might occur: excitation, headache, sweating, visual disturbances, nausea, vomiting, diarrhea, or hypoglycemia. There is no specific antidote; treatment consists of appropriate monitoring and supportive care. Substantial decreases in blood pressure or other evidence of shock-like conditions should be treated vigorously and promptly.

CARCINOGENESIS, MUTAGENESIS, IMPAIRMENT OF FERTILITY

Carcinogenesis: Carcinogenicity studies with RYZUMVI have not been conducted.

Mutagenesis: Phentolamine was not mutagenic in the in-vitro bacterial reverse mutation (Ames) assay. In the in-vitro chromosomal aberration study in Chinese hamster ovary cells, numerical aberrations were slightly increased after a 4-hour exposure to phentolamine without metabolic activation, and structural aberrations were slightly increased after a 4-hour exposure to phentolamine with metabolic activation only at the highest concentrations tested, but neither numerical nor structural aberrations were increased after a 20-hour exposure without metabolic activation. Phentolamine was not clastogenic in two in-vivo mouse micronucleus assays.

Impairment of Fertility: The effect of phentolamine on female fertility has not been studied. Male rats treated with oral phentolamine for nine weeks (four weeks prior to mating, 3 weeks during the mating period and 2 weeks after mating) were mated with untreated females. At doses up to 648-times human therapeutic exposure levels at the C_{max}, no adverse effects on male fertility parameters or on reproductive parameters in the untreated females mated with the treated males were observed.

Marketed by: Oyster Point Pharma, Inc., a Viatrix company





EDITED BY THOMAS JOHN, MD

CORNEA/ANTERIOR SEGMENT

Keys to Superior Limbic Keratoconjunctivitis

Expert advice for diagnosing and managing this inflammatory condition.

CHRISTINE YUE LEONARD
SENIOR ASSOCIATE EDITOR

Superior limbic keratoconjunctivitis is a chronic, often underdiagnosed inflammatory condition affecting the superior bulbar conjunctiva adjacent to the limbus. When patients aren't responding to treatments for dry eye and blepharitis, clinicians should consider SLK. Here, ocular surface experts share how they diagnose and manage this condition.

Presentation

"SLK typically originates from chronic friction between the superior tarsal and bulbar conjunctiva," explains Sezen Karakus, MD, of the Wilmer Eye Institute at Johns Hopkins. "Patients usually complain of a foreign body sensation that worsens with blinking. This chronic friction may be due to irregularities on the tarsal conjunctiva, such as scars or papillae, or redundant bulbar conjunctiva that moves and causes irritation with every blink."

Dr. Karakus says that SLK can originate from or be exacerbated by dryness, such as when there's an inadequate quantity or quality of tears to lubricate conjunctival surfaces in contact. "Conjunctival redundancy, or chalasis, can also stem from chronic friction if it wasn't the original reason that initiated the irritation," she says.

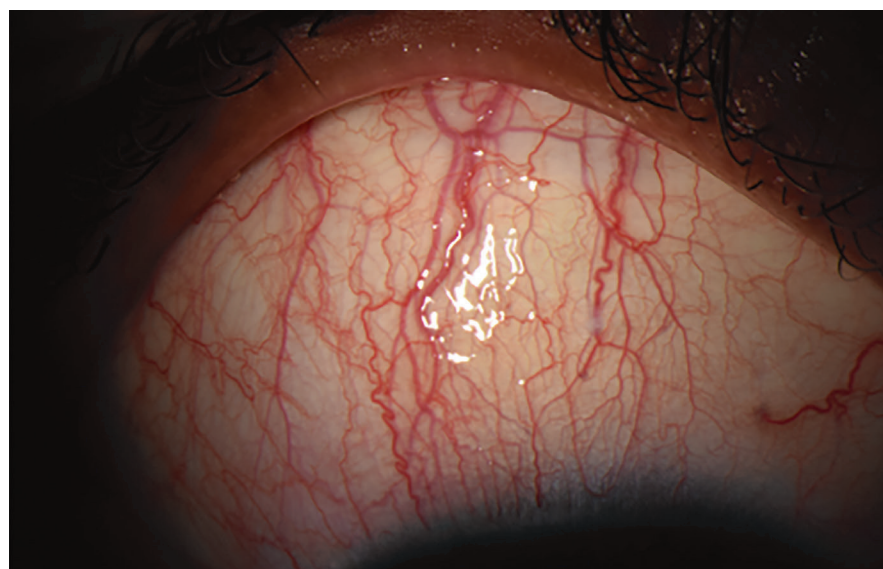"Initially, redness may be limited to this area and might not be noticeable unless the upper lid is lifted to examine the region. However, inflammation can spread to the adjacent limbus and superior cornea as the condition worsens, causing epithelial changes, filaments and abrasions. This leads to a worsened foreign body sensation, light sensitivity and more redness that's apparent in other quadrants. SLK can affect one eye or both eyes, though in bilateral cases, the severity is usually asymmetrical."

Making the Diagnosis

SLK presents with distinctive clinical features, although its diagnosis can be challenging due to similarities with other ocular surface diseases. "Redness, irregularities, papillae, follicles, scars, or vital dye staining of the tarsal conjunctiva help diagnose the ocular surface disease correctly," Dr. Karakus says.

When evaluating suspected SLK in the clinic, a slit lamp exam using vital dyes is essential for making the diagnosis (*Figure 1*). "The involved area of abnormal conjunctiva in SLK is always from 11:00 to 1:00 and may extend pretty far superiorly depending on the severity," says Christopher J. Rapuano, MD, of Wills Eye Hospital in Philadelphia. "The conjunctiva in SLK will stain with fluorescein or lissamine green. It's also rather thickened, loose and mobile. There may be some extension onto the superior cornea, possibly with some filaments. Upper lid eversion may demonstrate a velvety pattern."

"Redness of the superior conjunctiva can be referred to as the hallmark of



Sezen Karakus, MD

Figure 1A. A patient with SLK showing injection of the superior bulbar conjunctiva with engorgement of vertically oriented blood vessels.

This article has no commercial sponsorship.

Dr. John is a clinical associate professor at Loyola University at Chicago and is in private practice in Oak Brook, Tinley Park and Oak Lawn, Illinois. He can be reached at 708-429-2223; email: tjconference@gmail.com.

this condition,” Dr. Karakus says. “This can be observed sometimes macroscopically without using the slit lamp. Conjunctival blood vessels may appear radialized in this area, stretching towards the limbus. Lissamine green staining is particularly helpful for visualizing the affected area, especially in the early stages [before conjunctival injection develops]. This stage can be easier to miss if one looks only for conjunctival redness, but it’s also easier to treat as the inflammation may not be severe yet, allowing for a simpler disruption of the inflammatory cycle. Using lissamine green dye, affected superior bulbar conjunctiva and superior tarsal conjunctiva in contact with it can be easily identified in a mildly symptomatic patient before conjunctival injection appears.

“Lissamine green dye is also helpful in examining lid margins to visualize keratinization, observe the Marx line, and identify lid wiper epitheliopathy, often present with SLK,” she continues. “These patients frequently complain of significant burning, and the cornea may not show considerable dryness explaining the symptoms. The only finding may be lissamine green staining of the lid wiper area and superior bulbar conjunctiva.”

Fluorescein staining may reveal punctate epithelial erosions, minor abrasions, and filaments, according to Dr. Karakus. She notes that “in patients with SLK, the superior limbal area would look swollen and bumpy and stain with fluorescein that would become more apparent after a few minutes.”

Dr. Rapuano says that having the patient look down and examining the superior conjunctiva is a key part of making an SLK diagnosis. “Whenever I examine a patient with the broad category of ocular surface complaints, I always examine the upper conjunctiva

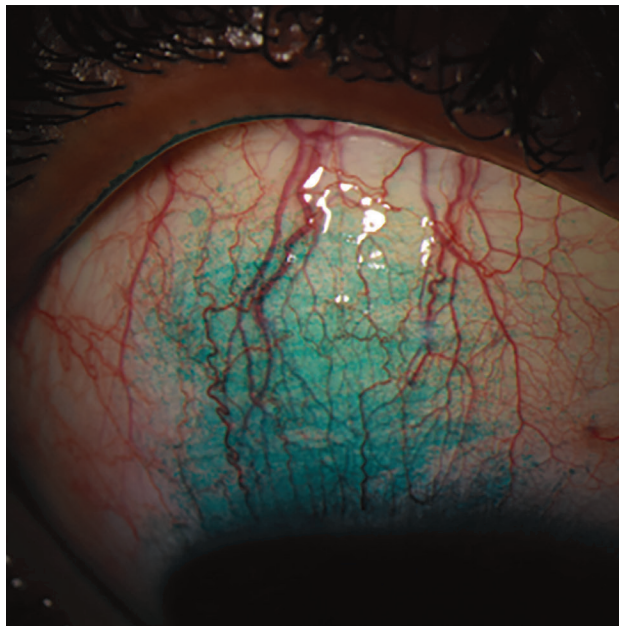


Figure 1B. The affected area is visualized with lissamine green staining.

while holding their upper lid up and always evert the upper lid and lower lid. Even if you aren’t suspecting SLK, by always examining the upper conjunctiva, you won’t miss it. If you always examine the fornices and flip the lids, you also won’t miss giant papillary conjunctivitis, floppy eyelid syndrome and mucous membrane pemphigoid. As an added bonus, you might save someone’s life by diagnosing the rare but potentially fatal sebaceous carcinoma.”

Dr. Karakus adds that SLK has been associated with thyroid disease, so it’s essential to rule this out. “If there’s no apparent local reason, such as a tarsal conjunctival scar, chronic allergies resulting in redundant conjunctiva or papillae causing chronic friction in the area and inducing inflammation, a workup should be done to rule out autoimmune diseases causing keratoconjunctivitis sicca and conjunctival inflammation, such as Sjogren’s disease or rheumatoid arthritis.”

Medical Management

Successful management of SLK involves a combination of medical and sometimes surgical interventions

aimed at alleviating symptoms, reducing inflammation and improving ocular surface health.

“My main goal of management is improved comfort,” says Dr. Rapuano, who uses a step-wise approach to treatment. “I start with lubrication with preservative-free tears, gels and ointments. Cyclosporine 0.05 to 1% q.i.d. and topical allergy drops are often helpful. If the eyes are dry, punctal plugs may be helpful. If filaments are present, you can use acetylcysteine 10% drops q.i.d. Rarely, I’ll use a short course of topical steroids. I used to use an application of silver nitrate solution 0.5% to the involved area for about 30 seconds, but

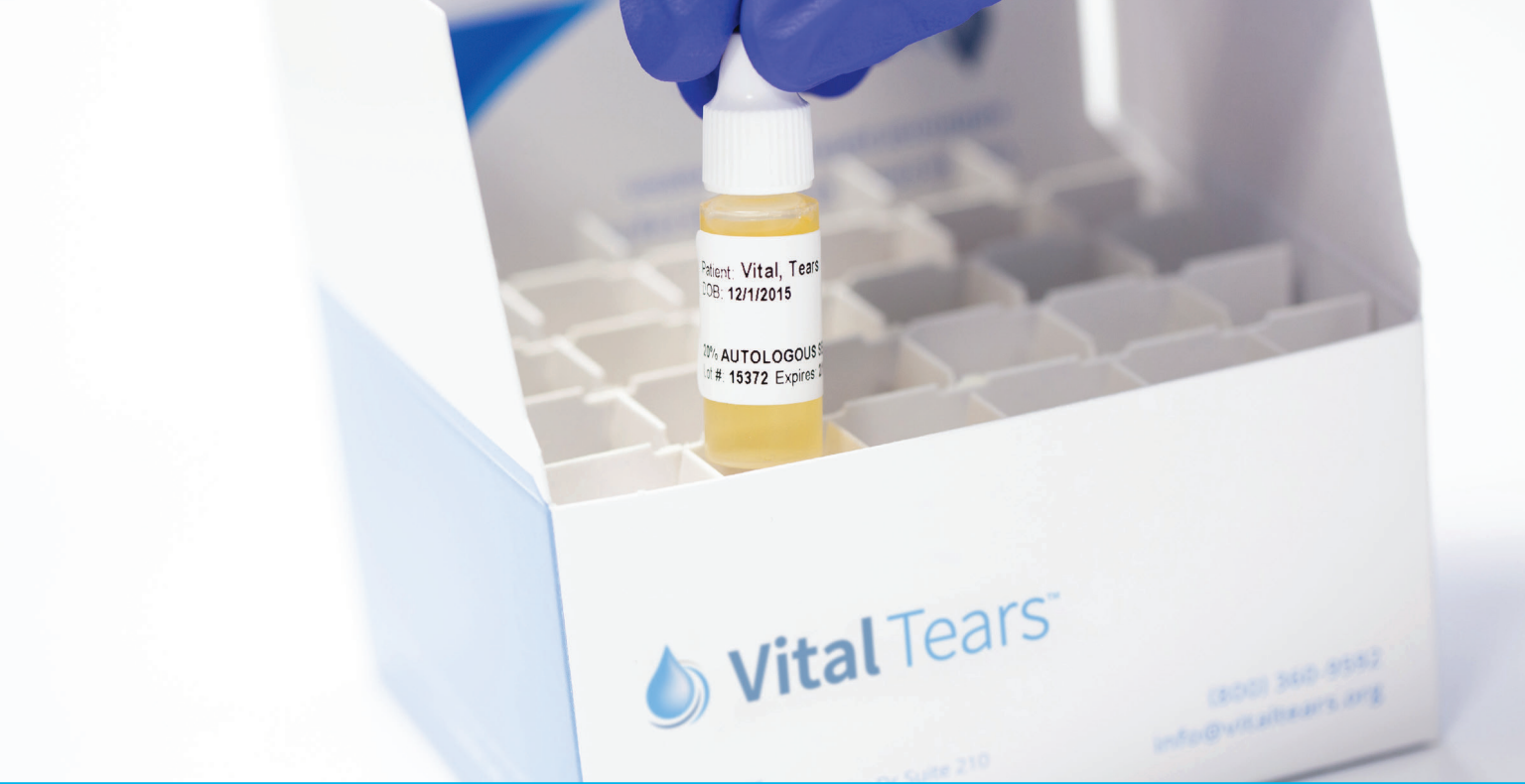I haven’t used this in years since silver nitrate solution is no longer readily available.”

Dr. Karakus says she also starts with lubrication using preservative-free tears and ointments as well as punctal plugs. “I prefer vitamin A eye ointment due to its lubricating properties and positive effects on epithelial cell regeneration,” she says. “It also provides support for the goblet cells, which are essential for mucin production.

“In severe cases involving the cornea, a bandage contact lens may be beneficial,” she continues. “If filaments are present, they should be removed before placing the bandage contact lens. Soft steroids are usually helpful in calming the eye in the short term, while immunomodulatory eye drops such as cyclosporine or lifitegrast are typically necessary for long-term management. This condition is often associated with chronic inflammation, and long-term steroid use isn’t preferred.

“If chronic friction and irritation are due to a tarsal scar, a scleral lens or PROSE (Prosthetic Replacement of the Ocular Surface Ecosystem) device may be considered as a long-term treatment option,” she explains.

Saezen Karakus, MD



Serum Tears Made **Easy, Fast & Safe**

We make it easy for you and your patients to get a **six-month supply of serum tears** from a single blood draw, with **turnaround times as quick as 48 hours** from the blood draw appointment.

Simply place your order online and then Vital Tears takes care of the rest.

1

We contact the patient to schedule the blood draw and collect payment.

2

Blood is drawn at one of our 400+ contracted facilities or by a mobile phlebotomist.

3

Serum tears are processed using rigorous, validated safety procedures then shipped directly to the patient.



Learn more about incorporating serum tears into practice from a panel of eye care leaders.

 **Vital Tears™**

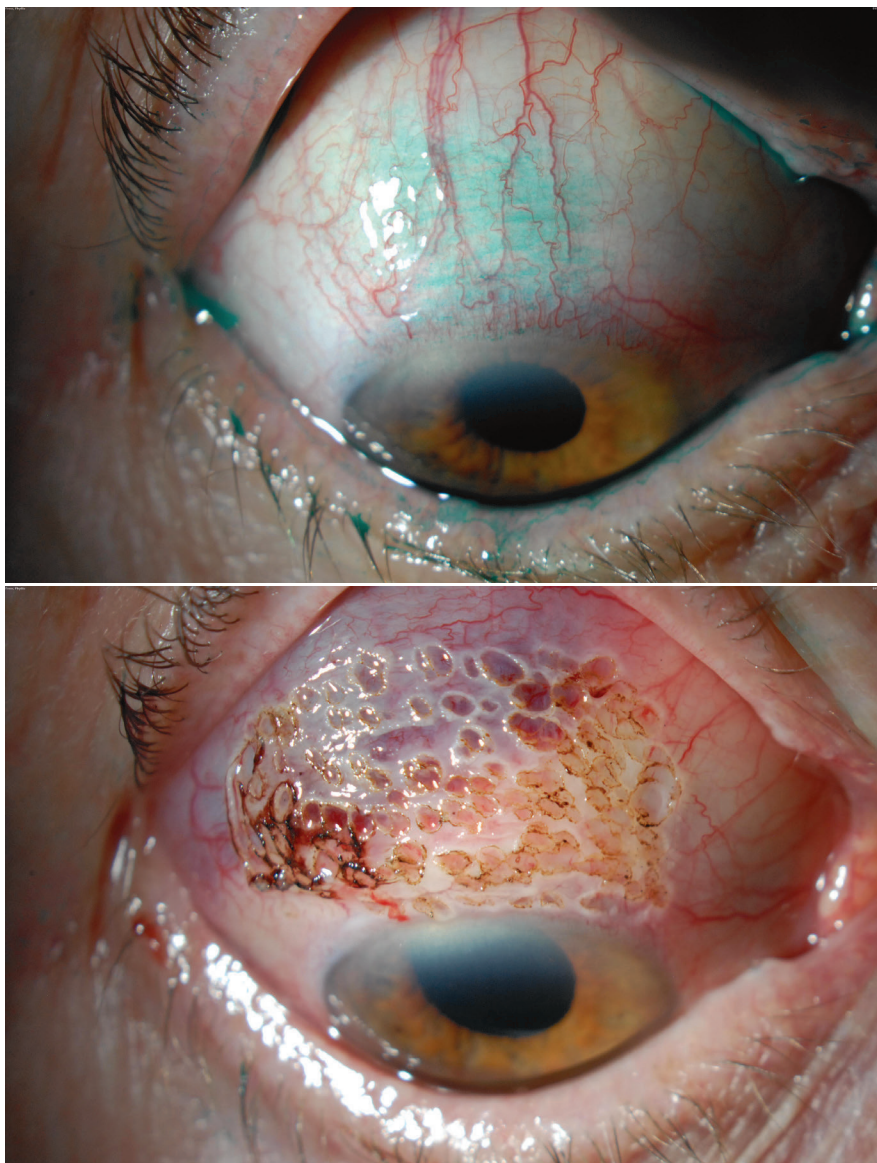


Figure 2. Top: The right eye with SLK demonstrates a thickened, injected leash of superior conjunctiva that stains with lissamine green. Bottom: The same eye has undergone a localized conjunctival cautery procedure to shrink and tighten up the superior conjunctiva. The conjunctival epithelial defects resolved within one week, and the patient's SLK symptoms greatly improved.

“In some cases, a surgical approach to smooth the tarsal conjunctiva, possibly using a mucosal graft, can be considered. Doxycycline is a helpful systemic agent to address inflammation, benefiting from its anti-matrix metalloproteinase-9 effect. In severe cases, I prefer using it at higher doses if tolerated.”

Surgical Management

Surgical intervention is warranted if

patients remain symptomatic despite medical treatment or if there's frequent recurrence of the condition. Dr. Rapuano typically performs localized cautery to the involved area to shrink and tighten up the tissue (*Figure 2*). “In the office, I inject local anesthetic under the superior conjunctiva and then very carefully apply cautery to the involved conjunctiva,” he says. “I find it very helpful about 75 percent of the time. It may need to be repeated.

Other surgical treatments include conjunctival resection or recession, but I don't typically need to do those as conjunctival cautery works pretty well.”

For these patients, Dr. Karakus says she performs surgical resection of the superior bulbar conjunctiva with placement of an amniotic membrane. “Some patients also benefit from using autologous serum eye drops in conjunction with or without surgical approaches,” she adds.

Long-term Management

Regular follow-up visits are needed to monitor and assess treatment efficacy and make any necessary adjustments. “Patients should be seen frequently initially to ensure proper response to treatment and to manage any side effects,” Dr. Karakus says. “Once the condition is stabilized, follow-up intervals can be extended, but patients should still be monitored for recurrences or new symptoms. Educating patients about the chronic nature of the condition and the importance of adherence to treatment and follow-up schedules is crucial for long-term success.”

The Bottom Line

A thorough examination of the ocular surface to investigate the underlying cause is the key to successful SLK management. “In advanced cases, ongoing irritation and friction cause the conjunctiva to become more redundant, inducing more friction and inflammation,” Dr. Karakus says. “Reversing structural changes such as keratinization and scarring of the conjunctiva becomes more challenging at later stages, making early diagnosis crucial. Therefore, early detection and intervention are essential to prevent the progression of the condition and to manage it effectively before significant structural changes occur.” ◀

DISCLOSURES

Dr. Rapuano and Dr. Karakus have no related financial disclosures.



EDITED BY ARTURO CHAYET, MD

REFRACTIVE/CATARACT RUNDOWN

The Moving Target of Hyperopia

Correcting hyperopes comes with its own unique challenges. Here's advice on treatment strategies.

LIZ HUNTER
SENIOR EDITOR

In the realm of refractive surgery, much of the conversation and research is centered on correcting myopia, largely due to its epidemic-like prevalence in the general population. Recent statistics estimate that myopia affects approximately 40 percent of the population in the United States, while only about 10 percent have hyperopia.¹⁻² Refractive surgeons may also be hesitant to treat hyperopes—at least surgically—because of the anatomical variations inherent to these eyes, including short axial length, a small anterior segment and a higher incidence of angle closure glaucoma,³ which make them prone to regression and unpredictability.⁴

In spite of these challenges—and with managed patient expectations—hyperopes are able to receive treatment with corneal refractive surgery or intraocular procedures such as refractive lens exchange. We spoke with a few surgeons about how they approach these candidates and the variables that influence their decision.

Hyperopia's Challenges

Hyperopes commonly accommodate naturally early on in their life and it's not until mid-life that they become bothered by it.

“Patients who are presenting for hyperopia are typically entering the

presbyopic phase of life, or they have latent hyperopia,” says Jennifer Loh, MD, a comprehensive ophthalmologist who practices in South Florida. “Often, when they were in their 20s and 30s, they didn't need glasses. As they start entering their 40s and get into the presbyopic phase, they start losing that accommodative ability, which at first affects their near—which they work through—but then it starts to affect distance because the hyperopia keeps getting stronger and their accommodative amplitude is decreasing.”

Thomas M. Harvey, MD, a refractive surgeon with a practice in Eau Claire, Wisconsin, calls hyperopia a “challenging refractive status.” “Hyperopic patients often show up in our laser centers asking for laser vision correction, such as LASIK. However, I think the solution may not always be laser,” Dr. Harvey says. “For most I think it may be better to use different surgical approaches. It's certainly a challenge and we always have to think about the associated hidden issues with hyperopia. Sometimes there can be mild amblyopia that's unrecognized, as well as decreased stereopsis. That's really important to recognize with a refractive patient long in advance because we have great lasers and lenses but they can't restore the wiring.”

Dr. Loh notes that hyperopia is a moving target. “Their prescription is

constantly evolving and changing,” she says. “Performing LASIK on a mild hyperope is difficult because in a year or two, their lens continues to change and their hyperopia keeps changing, even though you may have corrected them in the moment with LASIK. I've experienced referral patients who are only six months post LASIK and are already hyperopic again.”

Visual outcomes are improving, however, as reflected in at least one study that compared hyperopic LASIK performed on a wavefront platform vs. the outcomes on excimer lasers from previous literature.

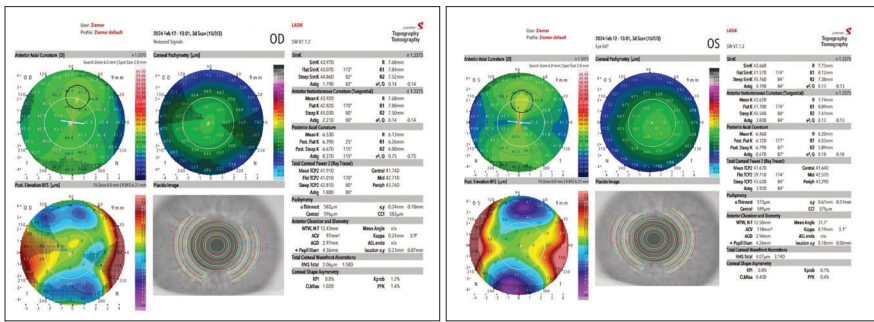
A total of 379 eyes underwent hyperopic LASIK on the Allegretto EX500 laser and at three and 12 months postoperatively, 66 percent and 69 percent of eyes had a UDVA of 20/20 or better and 96 percent and 97 percent had a UDVA of 20/40 or better, respectively. The mean refractive spherical equivalent was -0.52 ± 0.78 D at three months and -0.46 ± 0.79 D at 12 months. At a year, 96 percent of eyes achieved a spherical equivalent within ± 1 D of the intended target. The authors noted a significant difference in UDVA rates of 20/20 or better in studies published before and after 2005: 32 percent vs. 68 percent, respectively. They concluded that the safety, efficacy, stability and accuracy of hyperopic LASIK has greatly improved in the past two decades.⁵

Treatment Considerations

It's well-known that, whereas myopic patients only need corrections to see at distance, hyperopes are more complicated because they require both their near and distance vision corrected. Discussing the patient's goals can help in the decision-making process,

This article has no commercial sponsorship.

Dr. Chayet is considered a pioneer in refractive and cataract surgery, and is the medical director of the Codet Vision Institute in Tijuana, Mexico. He is a clinical investigator for RxSight, LensGen and ForSight Vision6.



This 43-year-old male patient was interested in spectacle independence. His preop manifest refraction was OD +2.50 -2.25 x 005 corrected to 20/20 and OS +6.00 -5.00 x 173 corrected to 20/25. Although the potential for the left eye was limited, the patient had realistic expectations and was treated with wavefront-optimized LASIK: OD +2.00 -2.25 x 179; OS +5.00 - 4.00 x 173. At two months the patient had 20/15 uncorrected OD and 20/30 uncorrected OS. The patient did report a slight blur in the left eye but said it didn't affect his life or require additional treatment. His residual refractive error that day was: OD +0.50 -0.25 x 150; OD +1.25 -1.00 x 160.

say surgeons.

“You have to look at the patient’s age and needs,” says Peter Hersh, MD, FACS, who is the director of the Cornea and Laser Eye Institute in New Jersey and a clinical professor of ophthalmology and director of the Cornea and Refractive Surgery Division at Rutgers Medical School. “Are they more concerned with distance vision or are they more concerned with close vision?”

Consider younger patients, he continues. “Whereas a 20-year-old who’s +2 will be functioning very well, a +2, 38-year-old is going to start to notice decreased near vision with premature presbyopia, decreased distance vision and will also experience difficulties in their focus because they have to exert accommodative effort at all distances,” Dr. Hersh says. “Now, a lot of these patients will want their near vision as well, and I would say up until around age 50 or so, in those cases, we’ll consider laser vision correction, but often we’ll add a little bit of monovision. For instance, if a patient’s already a +2.5, we’ll do +2.5 on their dominant eye and +3.25 to +3.5 on their non-dominant eye.

“It’s always important when considering monovision or other techniques that you initially make sure that the patient is tolerant of a disparity between their two eyes,” he continues.

“For that we’ll use a lens test using a +1 or +1.5 D in a trial frame. If that doesn’t give us a clear-cut enough result then we’ll fit the patient with a plus contact lens (+1.25 D or so) in their non-dominant eye to see if they’ll be tolerant of something like that. In fact, I’ve had very good success using either LASIK or PRK in younger patients with even higher degrees of hyperopia,” Dr. Hersh states. “For instance, I once treated my nephew, who was +6 at age 25 with a +4 PRK and he’s now older and really still enjoying excellent vision.”

SMILE is another technique to consider for patients with hyperopia up to 3 to 4 D, he adds. A study of 374 hyperopic eyes with and without astigmatism reported 81 percent of eyes treated were within ±0.5 D and 93 percent were within ±1 D of intended correction at the 12-month postop visit. Of the 219 eyes with a plano target, 68.8 percent had an uncorrected distance visual acuity of 20/20 or better and 88 percent were at least 20/25 uncorrected at 12 months.⁶

“As the patient gets older into their sixth and seventh decades, then I think we’re dealing with a lens that really can’t focus at all and if there’s any degree of nuclear sclerotic change or certainly cataractous change, then I would probably prefer a refractive lens

exchange,” continues Dr. Hersh.

Dr. Loh takes a more conservative approach and avoids laser vision correction whenever possible. “I typically don’t do laser vision correction (LASIK or PRK) on hyperopes, even though it’s approved,” she says. “I don’t like the ablation profile that it creates. Often, I noticed the ablation patterns were somewhat irregular; they tend to change a little bit over time and, again, combined with that and the changing hyperopia, patients can be dissatisfied. You usually end up having to do monovision on them to achieve a reduction in glasses use for distance and near and it may not be an ideal situation for the patient.”

She opts for a refractive lens in most cases. “There are a lot of surgeons who will do hyperopic LASIK and it seems to work for some people but again, my concern is the longevity of it,” says Dr. Loh. “I explain that to patients. If a patient’s in their 40s or 50s, I think it’s probably better to do a refractive lens exchange because that way you’ve removed the issue of the continued changing prescription due to the evolving lens dysfunction issue. You’ve taken out their lens and you’ve created a stable refractive profile.”

But what if a patient is insistent on having LASIK? “I usually discourage it,” she continues. “I tell them about the risks and benefits. I’ll recommend they wait a few more years until there’s a better solution. I’d consider LASIK if someone was a mild hyperope and they really understood the risks, but I want them to understand that they’re going to spend money and potentially in six months to a year not be happy if their prescription changes. They also have to be willing to undergo a monovision treatment in order to reduce the need for glasses in most situations.

“I also don’t want to give them a hyperopic treatment and then in 15 to 20 years when they need cataract surgery they’re no longer candidates for a multifocal,” Dr. Loh says. “I’m pretty cautious for those reasons.”

This is where patient education

CONTOURA[®]
VISION

More than 20/20 vision.^{1,*}

More than stunning quality.²

More than patient satisfaction.^{2,†}

MORE THAN A
NUMBER^{1,2,†}



Discover patient outcomes even better than 20/20 with the only true topography-guided laser vision correction—CONTOURA[®] Vision.¹ Now with advanced analytics to alleviate guesswork, CONTOURA[®] Vision delivers spectacular acuity and quality^{1,2,†}—making it possible to take **your patients from 20/20 to 20/More.**



CONTACT YOUR ALCON
SALES REPRESENTATIVE
TO LEARN MORE.

*Clinical results from a matched group of 317 manifest eyes and 323 analytic eyes. Using the Phorcides Analytic Engine for topography-guided surgery, 41.3% of the manifest group and 62.5% of the analytic group achieved 20/16 or better UDVA.

†Out of 124 patients from the clinical study, 122 responded that they would have LASIK again.

References

1. Lobanoff M, Stonecipher K, Tooma T, et al. Clinical outcomes after topography-guided LASIK: comparing results based on a new topography analysis algorithm with those based on manifest refraction. *J Cataract Refract Surg.* 2020;46(6):814-819. doi:10.1097/jjcrs.000000000000176.

2. Stulting RD, Fant BS; T-CAT Study Group. Results of topography-guided laser in situ keratomileusis custom ablation treatment with a refractive excimer laser. *J Cataract Refract Surg.* 2016;42(1):11-18. Study description: Prospective, nonrandomized, multicenter study of 249 eyes with myopia (up to -9D) or myopic astigmatism of 6.0 D or less. Outcome measures included manifest refraction, UDVA, CDVA and visual symptoms up to 12 months.

For Important Product Information about Contoura[®] Vision, please refer to the adjacent page.

© 2022 Alcon Inc. 1/22 US-WLC-2100031

Alcon

WAVELIGHT[®] EXCIMER LASER SYSTEMS IMPORTANT PRODUCT INFORMATION

This information pertains to all WaveLight[®] Excimer Laser Systems, including the WaveLight[®] ALLEGRETTO WAVE[®], the ALLEGRETTO WAVE[®] Eye-Q and the WaveLight[®] EX500. **Caution:** Federal (U.S.) law restricts the WaveLight[®] Excimer Laser Systems to sale by or on the order of a physician. Only practitioners who are experienced in the medical management and surgical treatment of the cornea, who have been trained in laser refractive surgery (including laser calibration and operation) should use a WaveLight[®] Excimer Laser System. **Indications:** FDA has approved the WaveLight[®] Excimer Laser systems for use in laser-assisted in situ keratomileusis (LASIK) treatments for: the reduction or elimination of myopia of up to -12.00 D and up to 6.00 D of astigmatism at the spectacle plane; the reduction or elimination of hyperopia up to +6.00 D with and without astigmatic refractive errors up to 5.00 D at the spectacle plane, with a maximum manifest refraction spherical equivalent of +6.00 D; the reduction or elimination of naturally occurring mixed astigmatism of up to 6.00 D at the spectacle plane; and the wavefront-guided reduction or elimination of myopia of up to -7.00 D and up to 3.00 D of astigmatism at the spectacle plane. In addition, FDA has approved the WaveLight[®] ALLEGRETTO WAVE[®] Eye-Q Excimer Laser System, when used with the WaveLight[®] ALLEGRO Topolyzer[®] and topography-guided treatment planning software for topography-guided LASIK treatments for the reduction or elimination of up to -9.00 D of myopia, or for the reduction or elimination of myopia with astigmatism, with up to -8.00 D of myopia and up to 3.00 D of astigmatism. The WaveLight[®] Excimer Laser Systems are only indicated for use in patients who are 18 years of age or older (21 years of age or older for mixed astigmatism) with documentation of a stable manifest refraction defined as ≤ 0.50 D of preoperative spherical equivalent shift over one year prior to surgery, exclusive of changes due to unmasking latent hyperopia. **Contraindications:** The WaveLight[®] Excimer Laser Systems are contraindicated for use with patients who: are pregnant or nursing; have a diagnosed collagen vascular, autoimmune or immunodeficiency disease; have been diagnosed keratoconus or if there are any clinical pictures suggestive of keratoconus; are taking isotretinoin (Accutane[®]) and/or amiodarone hydrochloride (Cardarone[®]); have severe dry eye; have corneas too thin for LASIK; have recurrent corneal erosion; have advanced glaucoma; or have uncontrolled diabetes. **Warnings:** The WaveLight[®] Excimer Laser Systems are not recommended for use with patients who have: systemic diseases likely to affect wound healing, such as connective tissue disease, insulin dependent diabetes, severe atopic disease or an immunocompromised status; a history of Herpes simplex or Herpes zoster keratitis; significant dry eye that is unresponsive to treatment; severe allergies; a history of glaucoma; an unreliable preoperative wavefront examination that precludes wavefront-guided treatment; or a poor quality preoperative topography map that precludes topography-guided LASIK treatment. The wavefront-guided LASIK procedure requires accurate and reliable data from the wavefront examination. Every step of every wavefront measurement that may be used as the basis for a wavefront-guided LASIK procedure must be validated by the user. Inaccurate or unreliable data from the wavefront examination will lead to an inaccurate treatment. Topography-guided LASIK requires preoperative topography maps of sufficient quality to use for planning a topography-guided LASIK treatment. Poor quality topography maps may affect the accuracy of the topography-guided LASIK treatment and may result in poor vision after topography-guided LASIK. **Precautions:** The safety and effectiveness of the WaveLight[®] Excimer Laser Systems have not been established for patients with: progressive myopia, hyperopia, astigmatism and/or mixed astigmatism, ocular disease, previous corneal or intraocular surgery, or trauma in the ablation zone; corneal abnormalities including, but not limited to, scars, irregular astigmatism and corneal warpage; residual corneal thickness after ablation of less than 250 microns due to the increased risk for corneal ectasia; pupil size below 7.0 mm after mydriatics were applied for wavefront-guided ablation planning; history of glaucoma or ocular hypertension of > 23 mmHg; taking the medications sumatriptan succinate (Imitrex[®]); corneal, lens and/or vitreous opacities including, but not limited to cataract; iris problems including, but not limited to, coloboma and previous iris surgery compromising proper eye tracking; or taking medications likely to affect wound healing including (but not limited to) antimetabolites. In addition, safety and effectiveness of the WaveLight[®] Excimer Laser Systems have not been established for: treatments with an optical zone < 6.0 mm or > 6.5 mm in diameter, or an ablation zone > 9.0 mm in diameter; or wavefront-guided treatment targets different from emmetropia (plano) in which the wavefront calculated defocus (spherical term) has been adjusted; In the WaveLight[®] Excimer Laser System clinical studies, there were few subjects with cylinder amounts > 4 D and ≤ 6 D. Not all complications, adverse events, and levels of effectiveness may have been determined for this population. Pupil sizes should be evaluated under mesopic illumination conditions. Effects of treatment on vision under poor illumination cannot be predicted prior to surgery. **Adverse Events and Complications Myopia:** In the myopia clinical study, 0.2% (2/876) of the eyes had a lost, misplaced, or misaligned flap reported at the 1 month examination. The following complications were reported 6 months after LASIK: 0.9% (7/818) had ghosting or double images in the operative eye; 0.1% (1/818) of the eyes had a corneal epithelial defect. Hyperopia: In the hyperopia clinical study, 0.4% (1/276) of the eyes had a retinal detachment or retinal vascular accident reported at the 3 month examination. The following complications were reported 6 months after LASIK: 0.8% (2/262) of the eyes had a corneal epithelial defect and 0.8% (2/262) had any epithelium in the interface. Mixed Astigmatism: In the mixed astigmatism clinical study, two adverse events were reported. The first event involved a patient who postoperatively was subject to blunt trauma to the treatment eye 6 days after surgery. The patient was found to have an intact globe with no rupture, inflammation or any dislodgement of the flap. UCVA was decreased due to this event. The second event involved the treatment of an incorrect axis of astigmatism. The axis was treated at 60 degrees instead of 160 degrees. The following complications were reported 6 months after LASIK: 1.8% (2/111) of the eyes had ghosting or double images in the operative eye. Wavefront-Guided Myopia: The wavefront-guided myopia clinical study included 374 eyes treated; 188 with wavefront-guided LASIK (Study Cohort) and 186 with Wavefront Optimized[®] LASIK (Control Cohort). No adverse events occurred during the postoperative period of the wavefront-guided LASIK procedures. In the Control Cohort, one subject undergoing traditional LASIK had the axis of astigmatism programmed as 115 degrees instead of the actual 155 degree axis. This led to cylinder in the left eye. The following complications were reported 6 months after wavefront-guided LASIK in the Study Cohort: 1.2% (2/166) of the eyes had a corneal epithelial defect; 1.2% (2/166) had foreign body sensation; and 0.6% (1/166) had pain. No complications were reported in the Control Cohort. Topography-Guided Myopia: There were six adverse events reported in the topography-guided myopia study. Four of the eyes experienced transient or temporary decreases in vision prior to the final 12 month follow-up visit, all of which were resolved by the final follow-up visit. One subject suffered from decreased vision in the treated eye, following blunt force trauma 4 days after surgery. One subject experienced retinal detachment, which was concluded to be unrelated to the surgical procedure. **Clinical Data Myopia:** The myopia clinical study included 901 eyes treated, of which 813 of 866 eligible eyes were followed for 12 months. Accountability at 3 months was 93.8%, at 6 months was 91.9%, and at 12 months was 93.9%. Of the 782 eyes that were eligible for the uncorrected visual acuity (UCVA) analysis of effectiveness at the 6-month stability time point, 98.3% were corrected to 20/40 or better, and 87.7% were corrected to 20/20 or better. Subjects who responded to a patient satisfaction questionnaire before and after LASIK reported the following visual symptoms at a "moderate" or "severe" level at least 1% higher at 3 months post-treatment than at baseline: visual fluctuations (28.6% vs. 12.8% at baseline). Long term risks of LASIK for myopia with and without astigmatism have not been studied beyond 12 months. Hyperopia: The hyperopia clinical study included 290 eyes treated, of which 100 of 290 eligible eyes were followed for 12 months. Accountability at 3 months was 95.2%, at 6 months was 93.9%, and at 12 months was 69.9%. Of the 212 eyes that were eligible for the UCVA analysis of effectiveness at the 6-month stability time point, 95.3% were corrected to 20/40 or better, and 69.4% were corrected to 20/20 or better. Subjects who responded to a patient satisfaction questionnaire before and after LASIK reported the following visual symptoms as "much worse" at 6 months post-treatment: halos (6.4%); visual fluctuations (6.1%); light sensitivity (4.9%); night driving glare (4.2%); and glare from bright lights (3.0%). Long term risks of LASIK for hyperopia with and without astigmatism have not been studied beyond 12 months. Mixed Astigmatism: The mixed astigmatism clinical study included 162 eyes treated, of which 111 were eligible to be followed for 6 months. Accountability at 1 month was 99.4%, at 3 months was 96.0%, and at 6 months was 100.0%. Of the 142 eyes that were eligible for the UCVA analysis of effectiveness at the 6-month stability time point, 97.3% achieved acuity of 20/40 or better, and 69.4% achieved acuity of 20/20 or better. Subjects who responded to a patient satisfaction questionnaire before and after LASIK reported the following visual symptoms at a "moderate" or "severe" level at least 1% higher at 3 months post-treatment than at baseline: sensitivity to light (52.9% vs. 43.3% at baseline); visual fluctuations (43.0% vs. 32.1% at baseline); and halos (42.3% vs. 37.0% at baseline). Long term risks of LASIK for mixed astigmatism have not been studied beyond 6 months. Wavefront-Guided Myopia: The wavefront-guided myopia clinical study included 374 eyes treated; 188 with wavefront-guided LASIK (Study Cohort) and 186 with Wavefront Optimized[®] LASIK (Control Cohort). 166 of the Study Cohort and 166 of the Control Cohort were eligible to be followed at 6 months. In the Study Cohort, accountability at 1 month was 96.8%, at 3 months was 96.8%, and at 6 months was 93.3%. In the Control Cohort, accountability at 1 month was 94.6%, at 3 months was 94.6%, and at 6 months was 92.2%. Of the 166 eyes in the Study Cohort that were eligible for the UCVA analysis of effectiveness at the 6-month stability time point, 99.4% were corrected to 20/40 or better, and 93.4% were corrected to 20/20 or better. Of the 166 eyes in the Control Cohort eligible for the UCVA analysis of effectiveness at the 6-month stability time point, 99.4% were corrected to 20/40 or better, and 92.8% were corrected to 20/20. In the Study Cohort, subjects who responded to a patient satisfaction questionnaire before and after LASIK reported the following visual symptoms at a "moderate" or "severe" level at least 1% higher at 3 months post-treatment than at baseline: light sensitivity (47.8% vs. 37.2% at baseline) and visual fluctuations (20.0% vs. 13.8% at baseline). In the Control Cohort, the following visual symptoms were reported at a "moderate" or "severe" level at least 1% higher at 3 months post-treatment than at baseline: halos (45.4% vs. 36.6% at baseline) and visual fluctuations (21.9% vs. 18.3% at baseline). Long term risks of wavefront-guided LASIK for myopia with and without astigmatism have not been studied beyond 6 months. Topography-Guided Myopia: The topography-guided myopia clinical study included 249 eyes treated, of which 230 eyes were followed for 12 months. Accountability at 3 months was 99.2%, at 6 months was 98.0%, and at 12 months was 92.4%. Of the 247 eyes that were eligible for the UCVA analysis at the 3-month stability time point, 99.2% were corrected to 20/40 or better, and 92.7% were corrected to 20/20 or better. Subjects who responded to a patient satisfaction questionnaire before and after LASIK reported the following visual symptoms as "marked" or "severe" at an incidence greater than 5% at 1 month after surgery: dryness (7% vs. 4% at baseline) and light sensitivity (7% vs. 5% at baseline). Visual symptoms continued to improve with time, and none of the visual symptoms were rated as being "marked" or "severe" with an incidence of at least 5% at 3 months or later after surgery. Long term risks of topography-guided LASIK for myopia with and without astigmatism have not been studied beyond 12 months. **Information for Patients:** Prior to undergoing LASIK surgery with a WaveLight[®] Excimer Laser System, prospective patients must receive a copy of the relevant Patient Information Booklet, and must be informed of the alternatives for correcting their vision, including (but not limited to) eyeglasses, contact lenses, photorefractive keratectomy, and other refractive surgeries. **Attention:** Please refer to a current WaveLight[®] Excimer Laser System Procedure Manual for a complete listing of the indications, complications, warnings, precautions, and side effects.

*Trademarks are the property of their respective owners.

is really important, says Dr. Harvey. “Generally the lasers we have in the United States do a pretty good job of correcting normal corneas up to +3 D. However, we have plenty of corneas that are either already too steep or are irregular and that would push us into other options, such as refractive lens exchange that works in a variety of situations,” he says. “This is off-label and should only be done by experienced surgeons and those who have good rapport with the patients and have educated them about all the risks that go along with intraocular surgery. This is a discussion that usually starts in the presbyopia age. I’m not doing refractive lens exchange on those who are pre-presbyopic, unless their refractive error is so massive and they’re effectively outside the range of accommodation anyway.”

Dr. Harvey has several IOLs in his arsenal. “For those who have minimal astigmatism and require a power less than 3 D, I’ll choose a ClearView 3 multifocal IOL (Lenstec) to give the patient correction not only for distance but also intermediate and near,” he says. “When there’s astigmatism and the patient requires some element of presbyopia correction with it then I’ll frequently lean on the Symphony OptiBlue IOL (Johnson & Johnson Vision) at this point in time because it does offer a pretty broad range of compensation for corneal astigmatism. That’s nice because with these astigmatism-correcting lenses that have EDOF-multifocal optics, they can benefit from the larger central optical zone present in the Symphony

group of IOLs.”

“When I do refractive lens exchanges, I want to make sure the patient is a candidate for a multifocal lens because they’re young and that’s what they’re coming in for,” explains Dr. Loh. “They’re expecting to be glasses-free. To do that you usually need a multifocal. Another option could be the Light-Adjustable Lens or Light-Adjustable Lens Plus and do a blended monovision. You’d of course have to make sure that they were a monovision candidate by either the history of monovision or a contact lens trial in the office, but that’s another option as well.”

Dr. Harvey isn’t sure if the LAL is right for this population. “The problem I see with the LAL is just the logistics of having a patient who’s a young working person having to come back to the clinic multiple times for dilated exams with refraction and adjustments,” he says. “And ultimately the lock-in is for a long time—for the rest of the patient’s life—and these patients are frequently only 40 years old. For these reasons, we haven’t been using that lens in the RLE population.”

Discussions might even include procedures that are approved in other countries, continues Dr. Harvey. “Sometimes we have people who are looking to be glasses-free with everything, but we know that the hyperopic-presbyope is perhaps better served to have refractive lens exchange or a hyperopic phakic lens implantation overseas (that may or may not offer some presbyopia cor-

rection). When we have patients who are slightly younger and outside of the respective manufacturer’s sweet spot for hyperopic LASIK, then that can be used a lot more frequently,” he says.

“We occasionally have patients who are on the +4 D and above spectrum that just can’t bear contact lenses, can’t afford a refractive lens exchange and are willing to accept a mild amount of potential contrast impact to have a better refractive error when not wearing glasses/contacts,” Dr. Harvey says. “We’re living in a pretty global world and it’s not a ‘big ask’ for those appropriate patients who are younger to have a hyperopic phakic IOL overseas. For U.S.-based surgeons, we have both Canada and Mexico as our sites for referral.”

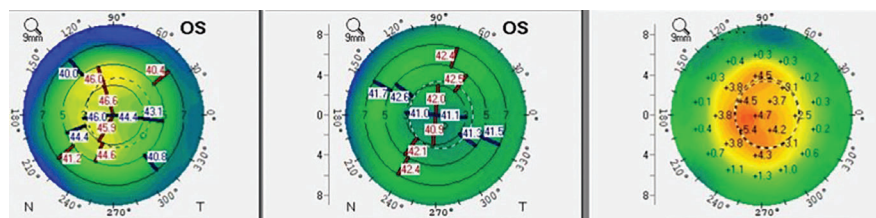
Ocular Pathology

Before proceeding with any treatment, surgeons say careful attention should be paid to screening for any ocular pathology, especially dry-eye disease.

“It’s important to note that these patients frequently get bad dry eye with laser vision correction because we’re ablating so far in the periphery,” says Dr. Harvey. “You shouldn’t ablate a preoperative dry eye and then expect the patient to be happy postoperatively because laser vision correction will make them a lot drier at least for a year.”

“It’s extremely important, especially if one is considering a lens exchange for refractive correction, or any of the corneal procedures, that the corneal surface be in pristine condition,” notes Dr. Hersh. “The reason is that any perturbation of light coming through will scatter light rays and cause aberrations. If they don’t have a perfectly smooth corneal lens, it can result in visual static. In combination with a procedure that’s working by making a cornea hyperprolate in the case of an EDOF lens or a multifocal lens, the optical result isn’t going to be good. So we’d have to perform a thorough analysis of the tear film, treat

(Continued on pg 40)



Peter Hersh, MD, FACS

Although performing LASIK on hyperopes can be challenging, outcomes are improving. Surgeons say it’s important to take time to discuss expectations with patients to find out which is more important to them: distance or near vision. Mini-monovision is a technique often used in these patients, but a trial run should be conducted to ensure the patient’s tolerance.

POINT:

LASIK BOASTS DECADES OF PROVEN OUTCOMES AND VERSATILITY

LASIK: TIME-TESTED AND SOPHISTICATED TECHNOLOGY

LASIK's precision and customization can improve vision for a wider range of patients.



AVNEET K. SODHI-GAUR, MD
LOS ANGELES

Since its introduction in the 1990s, LASIK has gone through several generations. LASIK's origins stem from the use of a microkeratome to manually cut a thin-hinged corneal flap, which was quite thick at the time—much thicker than what they are now—and an unguided excimer laser would sculpt the cornea.

The next iteration of LASIK involved the use of an Intralase femtosecond laser to create a microscopically thin flap, which helped preserve more corneal tissue and made the procedure a more viable option for many who were once deemed poor candidates. I'd say the third generation began with the Contoura (Alcon), approved in 2015, which gave us more advanced techniques for sculpting the cornea using topography to guide and customize patients' vision. We're moving even further in the scope of the technology now with wavefront-guided LASIK that can capture thousands of points on your eye to create a precise treatment plan.

With these advancements, the outcomes are getting better and studies prove this. In the FDA trials for the Contoura platform, 68.8 percent of patients achieved 20/16 or better UCVA at three months post-surgery, and 31.6 percent achieved 20/12.5 or better.¹ The iDesign Refractive Studio (Johnson & Johnson Vision), approved in 2018, achieved a UDVA of 20/16 in 74.1 percent of eyes in one study.² There have also been fewer postoperative complaints of light

sensitivity, issues with night driving, halos, glare and other visual aberrations that were common in previous generations of LASIK.

Even with LASIK's impressive results, surgeons and patients are always on the lookout for something new with more advantages. The newest contender is SMILE performed with the VisuMax femtosecond laser (Zeiss). Even though SMILE is in its relative infancy as a go-to refractive procedure, it can produce results similar to advanced LASIK—but it's not without its issues and considerations. Understanding the advantages of each procedure is crucial for selecting the best patients for each procedure.

Advantages of LASIK

LASIK can be used to treat a wide variety of patients with myopia, hyperopia and astigmatism. This makes it inherently advantageous because it makes more people eligible for the procedure. Some other advantages of LASIK are:

- **Proven track record.** One of the advantages of LASIK is that it's been around a long time, with tens of
- (Continued on p. 34)

This article has no commercial sponsorship.

Dr. Sodhi-Gaur is a cataract and LASIK specialist and partner at the Assil Gaur Eye Institute of Los Angeles.

COUNTERPOINT:

REFRACTIVE SURGEONS SHOULD CONSIDER SMILE'S VALUE

SMILE: HOLDING ITS OWN AGAINST LASIK

Direct comparisons of SMILE's first-generation technology to the advanced LASIK platforms are unfair.

Small-incision lenticule extraction is one type of refractive lenticule extraction (ReLex). It's also the newest laser vision correction technique, and was approved by the FDA in 2016 for the correction of myopia ranging from -1 D to -8 D and astigmatism up to 3 D in individuals aged 22 years or older. The procedure involves the creation of a thin disc of tissue on the cornea with the femtosecond laser (Zeiss VisuMax platform). This lenticule is then removed through a small incision.

Studies have shown that SMILE produces comparable visual results to femtosecond LASIK, as well as better outcomes in terms of dry eye, contrast sensitivity and induced aberrations at three months. In 2016, a single-center, prospective, randomized study of patients with myopia who underwent either FS-LASIK or SMILE had an equal amount of eyes in each group (84 percent) achieve a UCVA of 20/20 at three months, while 12 percent of eyes in the SMILE group and 4 percent in the LASIK group achieved 20/15. Higher order aberrations were higher in the LASIK group at three months, and postop

dry eye and glare were more common following LASIK, according to the study.¹

Along with my co-authors, we published a study in 2018 comparing SMILE to the different generations of LASIK.² We looked at 68 eyes that underwent SMILE surgery and collected their preop and postop UDVA, CDVA, manifest sphere, manifest cylinder, intraoperative complications, and preop and postop visual symptoms. We compared these to three early generation LASIK platforms (1999 to 2000) and three of the most recent at the time (2013 to 2016).

SMILE had significantly more eyes seeing 20/20 or better UDVA (74 percent), and 20/40 UDVA (98 percent), compared to 51 percent and 91 percent, respectively, in the early LASIK group. The numbers were better in the updated excimer laser group, with 89 percent seeing 20/20 or better and 99 percent seeing at least 20/40. That shows how close SMILE was coming to LASIK even as a brand-new technology.

To me, this demonstrates the fault in comparing SMILE directly to LASIK, which has had further



MAJID MOSHIRFAR, MD
DRAPER, UTAH

evolution into topography- and wavefront-guided technology. LASIK is a mature technology. SMILE is still young. That would be like comparing a chef who has just graduated from culinary school to a renowned and experienced chef who has received a Michelin star. It's just not a fair comparison.

(Continued on p. 35)

This article has no commercial sponsorship.

Dr. Moshirfar is the medical research director at Hoopes Vision Research Center in Draper, Utah, and director of the Refractive Surgery Program at the John A. Moran Eye Center, University of Utah.

POINT:

LASIK

(Continued from p. 32)

millions of procedures having been performed. It has had a chance to evolve and mature in its technology translating into different generations of LASIK offered throughout the years. Also, when you combine its familiarity with the solid long-term data of risk and complications and how to deal with those, it's not surprising that the majority of refractive surgeons continue to gravitate to LASIK technology. Granted, even though SMILE was approved in the United States in 2016, it has made large, advantageous strides in the advancements in its technology since then.

- **Faster vision recovery.** LASIK patients are typically seeing at their full visual potential one day after surgery. When SMILE was initially approved in the United States, there were higher femtosecond energy levels used, which therefore equated to significantly slower vision recovery and took a few weeks to get patients to their visual endpoint. However, in 2018, Zeiss adjusted the energy levels to where the lenticule creation didn't cause as much of an OBL (opaque bubble layer); therefore, allowing more ease of lenticule dissection and providing significant improvement in vision recovery. Although SMILE doesn't provide as consistent postoperative day one vision as LASIK does, it has made significant improvement over the years since its introduction.

- **Versatility is wider with LASIK.** Currently LASIK can correct a wide range of refractive errors, including myopia, hyperopia and higher degrees of astigmatism. SMILE is currently only approved for patients with -1 to -10 D of myopia and -0.75 to -3 D of astigmatism in the United States, however up to -5 D of astigmatism outside the U.S. Even though SMILE can be performed in low refractions, some refractive surgeons have found the lenticule can be so thin it can easily tear when trying to remove it, leaving higher risk of lenticule debris

and hindering visual outcomes.

- **Refractive results/enhanced precision.** Because LASIK is performed with the excimer laser which is designed for precise sculpting, versus the femtosecond laser in SMILE, designed for cutting, the excimer laser combined with wavefront technology delivers highly customized vision correction treatments coupled with reproducible results.

“When you combine its familiarity with the solid long-term data of risk and complications and how to deal with those, it's not surprising that the majority of refractive surgeons continue to gravitate to LASIK technology.”

In a 2023 study looking at patient-reported quality of vision in a prospective randomized contralateral-eye trial comparing LASIK and SMILE, it demonstrated that, of 40 patients who underwent wavefront-guided LASIK in one eye and SMILE in the fellow eye, there were slightly better outcomes with wavefront-guided LASIK compared to the SMILE surgery. Additionally, there were greater gains of lines of best-corrected visual acuity in the wavefront-guided LASIK group compared to the SMILE group and subjectively at the postoperative month 12 visit, 17 of 37 participants preferred the vision from the eye that underwent LASIK compared with seven of 37 who underwent SMILE.³

The advanced LASIK technologies, such as wavefront-guided or wavefront-optimized treatments, allow for highly customized corneal reshaping with iris registration and adjustment for cyclotorsion, all of which improve refractive outcomes by reducing glare

and starburst and hone in on reducing higher order aberrations.

However, with SMILE there were concerns with the machine's limitation in the United States with post-docking adjustments, accounting for cyclotorsion and centration leading to decentered treatments. In response to industry and surgeon feedback, Zeiss incorporated adjustments into its next generation Zeiss VisuMax 800 that was FDA approved in January 2024. The VisuMax 800 will have the ability to center over the pupil to prevent decentered treatments and account for cyclotorsion to improve its astigmatism correction.

- **Simplicity of LASIK enhancements.** In LASIK, it's easy and familiar to do a touch-up. We just lift the flap when possible and perform a retreatment. However, in SMILE, you simply can't repeat the SMILE surgery. There are few enhancement techniques possible after SMILE, and the decision to choose which to perform is dependent not only on what can be performed but also the surgeon's comfort. In the United States, the SMILE cap thickness is defaulted at 120 μm , so you can make an ultra thin LASIK flap between 90 to 95 μm in the SMILE cap, however, it only gives you approximately 25 to 30 μm of corneal tissue to sculpt with the excimer laser, which is very limited. Another choice is to perform a side cut and open up the original 120- μm SMILE cap and convert that into a LASIK flap.

A final choice is to perform PRK on top of the SMILE cap. We frequently resort to PRK enhancement in these situations, especially since many of our SMILE enhancement patients actually come from China where the technology differs, including the SMILE cap not having a default preset as it is in the United States. Therefore, the desire to do a LASIK enhancement becomes less straightforward in these patients.

(Continued on p. 36)

COUNTERPOINT:

SMILE

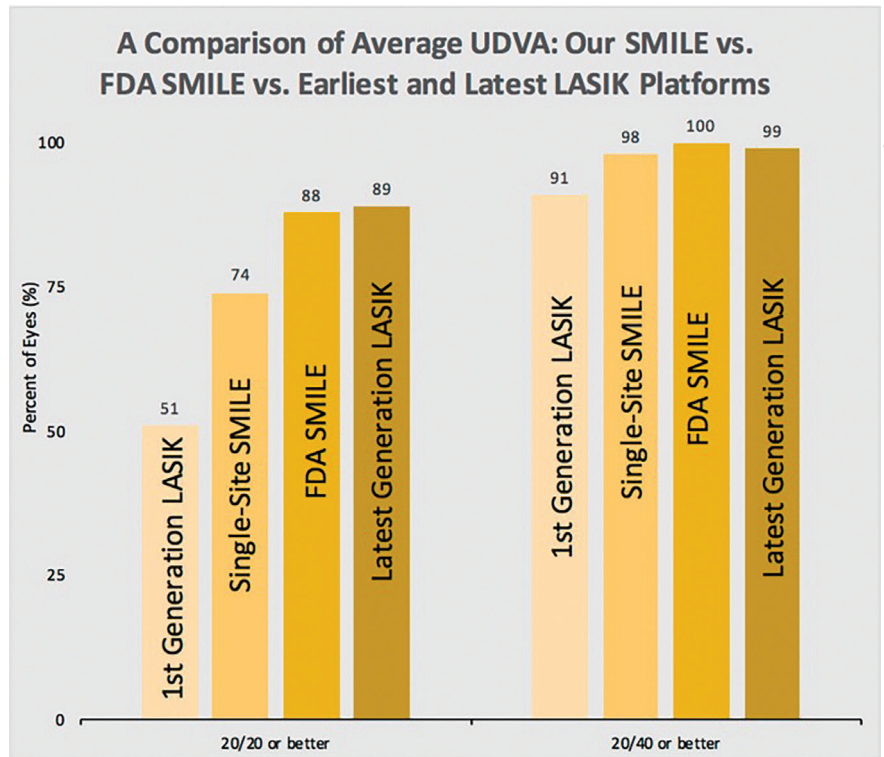
(Continued from p. 33)

In the United States, it hasn't even been a decade since SMILE's approval. If someone says that LASIK is better than SMILE, then they must be talking about topography-guided LASIK, which we know has spectacular results and achieves 20/15 and 20/10 vision for patients. We know that contrast sensitivity and higher order aberrations are reduced with topography-guided platforms, but in the first- and second-generation LASIK platforms, there was a tenfold increase in higher order aberrations. LASIK can't claim that it doesn't induce any higher order aberrations now, but it does induce much less. It's not quite fair to compare the latest, state-of-the-art LASIK platforms with SMILE. However, the younger SMILE is doing quite well and I believe it will surpass topography-guided LASIK in some ways in a matter of the next few years. Here's why:

Statistical Similarities

We recently conducted a contralateral study of 42 patients who underwent Contoura LASIK (Alcon) in one eye and SMILE on the Visumax 500 (Zeiss) in the other and presented data at ASCRS Boston 2024. In terms of safety index, efficacy, three-months uncorrected visual acuity, three-months best corrected visual acuity and gain/loss of vision, SMILE and LASIK are statistically the same.

But keep in mind, this study used the SMILE Visumax 500 platform that was the only one available in the United States at the time, which has a lot of limitations. This platform can't do centration, cyclotorsion, iris registration or pupil tracking. However, all of those capabilities exist with topo-guided LASIK, not to mention vertex compensation and 3D mapping that has the ability to correct for higher- and lower-order aberrations. LASIK can also correct for 0.25 and 0.50 of cylinder, yet SMILE can't do any of those things. So here we have



We compared the average UDVA between our single-site SMILE results to the results of the FDA SMILE trial and the earliest and latest excimer platforms for LASIK. As a first-generation technology, SMILE outperformed the first generation of LASIK and overall its results were competitive with the latest LASIK platform at the time.

a SMILE platform that's still at its young stage, but is going head to head with topography-guided LASIK.

Many people mention that LASIK has a faster recovery time than SMILE, and when we look at our data at one day and one week postop, it's true LASIK patients recover more quickly. Yet there's no difference at one month and three months. So why don't SMILE patients recover as quickly? Well, we've been limited in the energy we can use in this country. The ability to optimize the energy, change the spot size or the line separation would—I believe—help SMILE surpass LASIK. Yet, my hands are tied. I can't correct for astigmatism that's less than 0.75. I can't do iris registration or cyclotorsion, or track the pupil. There's no tracking mechanism and we have to trust that the patient is looking at the light.

This past January, the FDA approved the Visumax 800. The new platform creates the lenticule in less than 10 seconds and has more energy, plus enhancements that include centration, cyclotorsion adjustment and user nomograms. We've been refining LASIK nomograms for years. I have close to 12,000 eyes in my LASIK nomogram, ranging from age 20 to age 55, so I can tweak the sphere, reduce the cylinder, etc., all of those factors based on years of results. We know how to treat a 40-year-old who needs a -6 D correction with 2 D of astigmatism. On the other hand, I only have about 1,200 eyes for SMILE, so there's not as much ability to refine it with regard to regression over time, the longevity of the refractive error, etc. We need more data to create nomograms based on patients'

(Continued on p. 36)

Photo Credit: Majid Moshirfar, MD

POINT:

LASIK

(Continued from p. 34)

Recognizing SMILE's Potential

SMILE is certainly a procedure to watch. As it evolves in the future, it will find its niche in the refractive world and will have a more widespread adoption among refractive surgeons. But I think it still has some more finessing to do. SMILE is a good form of refractive surgery for simple forms of myopia and limited astigmatism. We're more limited in the United States with it because internationally they can treat some hyperopic prescriptions and higher astigmatism prescriptions. Still, I'd say SMILE is for a certain niche of patients who might not be candidates for an ICL, don't want to deal with the long recovery of PRK or have a history of dry eye.

One area where SMILE may outperform LASIK is with the dry eye aspect. We know SMILE patients experience less postoperative dry eye because it disrupts fewer corneal nerves and patients heal faster than LASIK, however, when followed for six months, there's no difference in dryness symptoms in the two groups.⁴

In addition, the newest generation of LASIK technology, which we're using in our practice, addresses some of the dry eye symptoms by customizing the flap size, hinge length and hinge position to disrupt fewer corneal nerves. Developed by Kerry Assil, MD, EAGLE (Elliptical flap aberrometry-guided laser enhanced) Vision LASIK incorporates iDesign wavefront technology and a customized elliptical-flap for each individual eye. Because each eye is different, we believe the flap should be different for each patient, and this allows us to customize the positioning of the flap hinge and where it's located. Some smaller studies suggest that flap hinges positioned temporally or nasally preserve corneal nerves, and therefore decrease dry-eye rates.⁵

There needs to be a large study to validate this data.

While LASIK remains the dominant procedure in the United States due to its extensive history, proven outcomes and versatility, SMILE presents a promising alternative with its flapless approach and potential benefits in corneal biomechanics and dry-eye management. And as femtosecond technology continues to improve so will its refractive results with SMILE.

Ultimately, I think the adoption of SMILE in the United States has been slow due to two reasons: Firstly, the limitation of the current technology's ability to customize treatment plans compared to outside the United States; and, secondly, because the technology is evolving rather quickly with SMILE, for refractive surgeons it's difficult to stomach the cost of a technology that could possibly be deemed obsolete in a matter of a year.

Therefore, since SMILE is still in its infancy compared to LASIK, it's truly not a fair comparison as it still needs to mature the way LASIK did over 30 years, with various refinements and technological advancements. ◀

1. FDA Clinical Trials. Allegretto Wave Eye-Q Addendum Procedure Manual T-CAT Topography-Guided Treatments. http://www.accessdata.fda.gov/cdrh_docs/pdf2/P020050S012d.pdf. Accessed June 13, 2024.

2. Johnson & Johnson Vision Launches Next Generation of Personalized LASIK Treatment, iDESIGN Refractive Studio Now Available. Sept., 6, 2018. <https://www.jjvision.com/press-release/johnson-johnson-vision-launches-next-generation-personalized-lasik-treatment-idesign>. Accessed June 13, 2024.

3. Ma KK, Manche EE. Patient-reported quality of vision in a prospective randomized contralateral-eye trial comparing LASIK and small-incision lenticule extraction. *J Cataract Refract Surg* 2023;1:49:4:348-353.

4. Wong AHY, Cheung RKY, Kua WN, Shih KC, Chan TCY, Wan KH. Dry eyes after SMILE. *Asia Pac J Ophthalmol (Phila)* 2019;8:5:397-405.

5. Feng YF, Yu JG, Wang DD, Li JH, Huang JH, Shi JL, Ye T, Wang QM, Zhao YE. The effect of hinge location on corneal sensation and dry eye after LASIK: A systematic review and meta-analysis. *Graefes Arch Clin Exp Ophthalmol* 2013;251:1:357-66.

COUNTERPOINT:

SMILE

(Continued from p. 35)

age and correction.

I think all of the corneal refractive technology platforms are great, and I use all of them, but when you look at SMILE, you can understand that we've only been using its first-generation technology. We haven't even gone to the second generation. Imagine what's going to happen when we have more refinement.

Advantages of SMILE

Putting all of that aside, SMILE has several advantages over LASIK.

- **No flap.** SMILE creates a cap that's only about 7 or 7.5 mm, and the incision itself is only about two to three clock hours. The LASIK flap is 8 to 8.5 mm and the incision goes all the way around 11 clock hours. You're violating the anterior corneal architecture more tangibly. With SMILE, there's a lesser degree of protrusion into the anterior one-third of the cornea than with LASIK because we don't create that flap with 10 or 11 clock hours of side cut with a hinge of two or one clock hours. In SMILE, we just make a cap and go underneath this cap through a very small incision to remove the lenticule.

- **A better effective optical zone.** When comparing the ablation of the excimer laser vs. the lenticule you create with SMILE, the effective optical zone is slightly better with SMILE. When you look at the topographies of SMILE patients weeks, months or years later, the effective optical zone area is bigger.

- **Better visual outcomes for high myopia.** Study after study has shown that SMILE has slightly better visual outcomes than LASIK when it comes to high myopia.³ Many of the topo-guided LASIK platforms can't correct for high myopia, but SMILE can correct up to -13 D.

- **One machine.** LASIK requires a femtosecond machine and an excimer laser. SMILE just uses one femtosecond laser for both cuts. This helps save space in a surgical suite. Also, from a mainte-

nance point of view or for surgeons in developing countries, it's much more attractive to have one platform.

• **Patient selection.** Patients who are involved with contact sports such as martial arts are often not candidates for LASIK because of the risk of blunt injury and flap dislocation. SMILE is stronger biomechanically and suits that lifestyle more appropriately. Additionally, patients who have lagophthalmos do better with SMILE. There's less risk of developing dry eyes because there's no flap exposed by the eyelid. I've also treated a patient with Bell's palsy who never recovered and I recommended SMILE in the Bell's palsy eye.

Why Learn SMILE?

One of the things I hear people say is "I'm happy with my LASIK results, why do I need to offer SMILE?" It reminds me of when cataract incisions became smaller and people wondered why they needed to go from 3.2 mm to 2.4 mm. The fact is, we're always refining our surgical technique and we should have all surgical options in our armamentarium. If you're truly a corneal refractive surgeon as your primary focus, you need to advocate for ReLex procedures. If someone argues that they don't want to use SMILE for myopic astigmatism or hyperopic astigmatism, and they only want to use LASIK, I feel that's not a good mindset because this technology is going to influence so many facets and they need to have their hands in it.

Lenticule surgery and femtosecond lenticule creation aren't going away. As a matter of fact, in the future we may have the ability to do corneal augmentation with this same type of platform. We may be able to take the lenticule of someone who is -6 and use it in an individual who is +6. I truly believe that the principles of lenticule removal and harvesting will not only impact corneal refractive practices, but will impact the eye-bank industry.

Ultimately, nothing is black and white. There are some patients for whom I truly believe SMILE is by far the better option, and there are some patients for whom I'll choose LASIK. Any good clinician who wants to dedicate their practice to refractive surgery should not only be able to do LASIK, but also SMILE, PRK and other techniques that we have access to. ◀

1. Ganesh S, Gupta R. Comparison of visual and refractive outcomes following femtosecond laser-assisted LASIK with SMILE in patients with myopia or myopic astigmatism. *J Refract Surg* 2014;30:9:590-6.
2. Moshirfar M, Murri MS, Shah TJ, Linn SH, Ronquillo Y, Birdsong OC, Hoopes PC Jr. Initial single-site surgical experience with SMILE: A comparison of results to FDA SMILE, and the earliest and latest generation of LASIK. *Ophthalmol Ther* 2018;7:2:347-360.
3. Qian Y, Chen X, Naidu RK, Zhou X. Comparison of efficacy and visual outcomes after SMILE and FS-LASIK for the correction of high myopia with the sum of myopia and astigmatism from -10.00 to -14.00 dioptres. *Acta Ophthalmol* 2020;98:2:e161-e172.

ADVERTISER INDEX

This index is published as a convenience and not as part of the advertising contract. Every care will be taken to index correctly. No allowance will be made for errors due to spelling, incorrect page number, or failure to insert.

Alcon	15, 16	www.clareonol.com
Alcon	29, 30	www.alcon.com
Apellis	69-Cover 3	www.apellis.com
Bausch + Lomb	Cover 2	866-246-8245 https://www.bausch.com/products/otc-eye-care-supplements/vitamins/
Glaukos	Cover 4	(800) 452-8567 www.glaukos.com
Harrow	5, 6	https://www.harrow.com/
Harrow	13	https://www.harrow.com/
Icare USA	Cover Tip	(888) 422-7313 www.icare-world.com/USA
Johnson & Johnson Surgical Vision, Inc.	19	http://surgical.jvision.com
Nextgen	43	www.nextgen.com/1-ophth
Ocular Therapeutix	45, 46	www.ocutx.com
Oculus, Inc.	8	(888) 519-5375 www.pentacam.com
OSRX	55	781-832-3664 https://www.osrxpharmaceuticals.com
Oyster Point	38, 39	https://oysterpointrx.com/
Thea Pharma	11	781-832-3664 https://www.ivizia.com/
Viatriis	21, 22	https://www.viatriis.com/en

tyrvaya[®]
(varenicline solution)
nasal spray 0.03 mg

FOR THE SIGNS
& SYMPTOMS OF
DRY EYE DISEASE

SHE'S LOOKING TO YOU FOR A
DIFFERENT APPROACH WHEN
ARTIFICIAL TEARS ARE NOT ENOUGH.¹

BEFORE ANOTHER DROP

ACTIVATE REAL TEARS

WITH THE FIRST AND ONLY NASAL
SPRAY FOR DRY EYE²



Tyrvaya[®] is not another drop

It's an **ocular surface-sparing** nasal spray.²



Activates real, basal tears

Tyrvaya[®] is believed to work by activating the trigeminal parasympathetic pathway resulting in **basal tear production**.^{2*}



Real tears, real fast

In 2 clinical trials with **mild, moderate, and severe** dry eye disease patients, Tyrvaya increased tear production from baseline by **≥10 mm in Schirmer's Test Score (STS) in nearly 50% of patients at week 4**, with increased tears seen as early as the first dose and over 12 weeks.^{2-8†}

SEE WHAT
TYRVAYA
CAN DO



*The exact mechanism of action is unknown.

†Tyrvaya was evaluated across 3 randomized, vehicle-controlled, double-masked studies in which adults aged ≥22 years diagnosed with dry eye disease received 1 spray of either active drug or vehicle in each nostril twice daily. Primary endpoint: % of patients with mean change from baseline in STS of ≥10 mm at week 4 in ONSET-1: 52% with Tyrvaya (n=48) vs 14% with vehicle (n=43) and in ONSET-2: 47% with Tyrvaya (n=260) vs 28% with vehicle (n=252). Onset of action: mean change from baseline in STS ~5 minutes after first dose (not a prespecified endpoint) in ONSET-1 was 17.2 mm with Tyrvaya (n=48) vs 4.0 mm with vehicle (n=43) and in ONSET-2 was 16.5 mm with Tyrvaya (n=260) vs 6.9 mm with vehicle (n=251). Observed data. On Day 1 in clinical studies, a baseline anesthetized Schirmer's test was performed. Tyrvaya was then administered concurrently with Schirmer's test. Schirmer's test results were measured at ~5 minutes. Mean change from baseline in STS at week 12 in the MYSTIC study was 10.8 mm with Tyrvaya vs 6.0 mm with vehicle. Limitations: Ex-US, single-center study. All subjects were Hispanic or Latino. Tyrvaya group mean baseline STS 5.5 mm (n=41); vehicle group mean baseline STS 5.3 mm (n=41). All randomized and treated patients were included in the analysis and missing data were imputed using last-available data.²⁻⁸
See references on next page.

Indication

Tyrvaya[®] (varenicline solution) nasal spray is indicated for the treatment of the signs and symptoms of dry eye disease.

Important Safety Information

The most common adverse reaction reported in 82% of patients was sneezing. Events that were reported in 5-16% of patients were cough, throat irritation, and instillation-site (nose) irritation.

Please see Brief Summary of Prescribing Information on the next page and the full Prescribing Information at Tyrvaya-pro.com.

BRIEF SUMMARY: Consult the full Prescribing Information for complete product information available at www.tyrvaya-pro.com.

INDICATIONS AND USAGE

TYRVAYA® (varenicline solution) nasal spray is a cholinergic agonist indicated for the treatment of the signs and symptoms of dry eye disease.

ADVERSE REACTIONS

Clinical Trials Experience: Because clinical trials are conducted under widely varying conditions, adverse reaction rates observed in the clinical trials of a drug cannot be directly compared to rates in the clinical trials of another drug and may not reflect the rates observed in practice.

In three clinical trials of dry eye disease conducted with varenicline solution nasal spray, 349 patients received at least 1 dose of TYRVAYA. The majority of patients had 31 days of treatment exposure, with a maximum exposure of 105 days.

The most common adverse reactions reported in 82% of TYRVAYA treated patients was sneezing. Other common adverse reactions that were reported in >5% of patients include cough (16%), throat irritation (13%), and instillation-site (nose) irritation (8%).

USE IN SPECIFIC POPULATIONS

Pregnancy: Risk Summary: There are no available data on TYRVAYA use in pregnant women to inform any drug associated risks. In animal reproduction studies, varenicline did not produce malformations at clinically relevant doses.

All pregnancies have a risk of birth defect, loss, or other adverse outcomes. In the US general population, the estimated background risk of

major birth defects and miscarriage in clinically recognized pregnancies is 2% to 4% and 15% to 20%, respectively.

Data: Animal Data: Pregnant rats and rabbits received varenicline succinate during organogenesis at oral doses up to 15 and 30 mg/kg/day, respectively. While no fetal structural abnormalities occurred in either species, maternal toxicity, characterized by reduced body weight gain, and reduced fetal weights occurred in rabbits at the highest dose (4864 times the MRHD on a mg/m² basis).

In a pre- and postnatal development study, pregnant rats received up to 15 mg/kg/day of oral varenicline succinate from organogenesis through lactation. Maternal toxicity, characterized by a decrease in body weight gain, was observed at 15 mg/kg/day (1216 times the MRHD on a mg/m² basis). Decreased fertility and increased auditory startle response occurred in offspring at the highest maternal dose of 15 mg/kg/day.

Lactation: Risk summary: There are no data on the presence of varenicline in human milk, the effects on the breastfed infant, or the effects on milk production. In animal studies varenicline was present in milk of lactating rats. However, due to species-specific differences in lactation physiology, animal data may not reliably predict drug levels in human milk.

The lack of clinical data during lactation precludes a clear determination of the risk of TYRVAYA to an infant during lactation; however, the developmental and health benefits of breastfeeding should be considered along with the mother's clinical need for TYRVAYA and any potential adverse effects on the breastfed child from TYRVAYA.

Pediatric Use: Safety and efficacy of TYRVAYA in pediatric patients have not been established.

Geriatric Use: No overall differences in safety or effectiveness have been observed between elderly and younger adult patients.

References: 1. Jones L, Downie LE, Korb D, et al. *Ocul Surf.* 2017;15(3):575-628. 2. Tyrvaya. Prescribing Information. Oyster Point Pharma; 2021. 3. Oyster Point Pharma. Data on file. OPP-002 (ONSET-1) Clinical Study Report. August 4, 2019. 4. Oyster Point Pharma. Data on file. OPP-101 (ONSET-2) Interim Clinical Study Report. October 13, 2020. 5. Quiroz-Mercado H, Hernandez-Quintela E, Chiu KH, Henry E, Nau JA. *Ocul Surf.* 2022;24:15-21. 6. Wirta D, Torkildsen GL, Boehmer B, et al. *Cornea.* 2022;4(10):1207-1216. 7. Wirta D, Vollmer P, Paauw J, et al. *Ophthalmology.* 2021;0(0):379-387. 8. Oyster Point Pharma. Data on file. OPP-004 (MYSTIC) Clinical Study Report. March 19, 2020.

Manufactured for Oyster Point Pharma, Inc. 202 Carnegie Center, Suite 106, Princeton NJ 08540. For more information, visit www.tyrvaya-pro.com. To report an adverse event, contact 1-877-EYE-0123.

© 2023 Viatrix Inc. and/or its affiliates. All rights reserved. VIATRIS and the Viatrix Logo are trademarks of Mylan Inc., a Viatrix Company. Oyster Point®, Tyrvaya®, and the Tyrvaya logo are trademarks of Oyster Point Pharma, Inc., a Viatrix company, in the United States and certain jurisdictions. OP-TYR-002308 7/23

(Continued from pg 31)

any blepharitis, certainly treat any basement membrane dystrophy. In fact, I think we'd prefer using a PRK procedure on hyperopes with epithelial basement membrane dystrophy because that in essence corrects two things: It smooths the surface, removing the EBMD, and also corrects their hyperopia or presbyopia at the same time."

Dr. Hersh recommends an in-depth examination of the ocular surface including staining, measuring tear breakup time, looking at the lids for blepharitis or meibomitis, checking the tear film for osmolarity and other indicators, and treating the patient beforehand, especially for patients who are 50 or older.

The other area of concern is the retina. "If one is considering either a corneal procedure or a lens exchange procedure, especially in patients who are getting on in years, it's very important to do a good macula assessment because any changes that one might have in the retina are going to lead to a poorer result," Dr. Hersh says.

Managing Patient Expectations

Every refractive surgeon knows the delicate balance between choosing the right procedure and making patients happy, and it's important to have these conversations in advance.

Dr. Hersh bluntly tells patients that perfect vision isn't always likely. "No matter what we do, there's always going to be a compromise between distance vision and near vision," he says. "The better we get their distance in both eyes, the more they're going to need reading glasses, so there are trade-offs and the patient needs to make a decision. Do they want to optimize distance, do they want to optimize near or do they want something in between?"

Patients also have to understand aberrations that may result from changing the corneal shape or implanting IOLs. "Such aberrations can cause effects, such as diminished quality of

vision, glare, halo and monocular multiplopia, for example," Dr. Hersh says. "I explain it to them by comparing the situation to a TV. If we take their eye and we do a procedure and get every ray in perfect focus for distance, they're going to have excellent distance visual acuity just like a high-definition TV. If there's some irregularity of the surface that might be induced from a corneal or lens procedure, that will add a little bit of aberration or what we call visual static, somewhat like an older TV. Certainly if there's any significant irregularity that occurs, that can be like a much older TV because it could be a lot of static.

"But I do tell them nowadays the risk of glare, halo and monocular multiplopia are far less than in the early days," he continues. "However, the important thing is to have an understanding, especially as you get older, about your near and distance function because it's not really possible to get vision at age 55 like you had when you were 20. There's always a trade-off between distance and near vision if you don't want to use glasses."

Dr. Loh says treating hyperopia has become an art in some ways. "It really depends on the age of the patient, and this is what I've been learning," she says. "It's really critical to check preoperative uncorrected near vision in these patients undergoing refractive lens exchange because if they're still in the early part of the journey to presbyopia, there's a chance that even with the current technology of multifocal lenses, they may not be 100 percent satisfied with their near. Although they might end up being J1 or J1+, which we'd think is a success, they'll still say it's just not as good as they expected.

"I learned this from my colleagues as well," continues Dr. Loh. "It probably is better to be a little more cautious and make sure that these patients are in the more moderate to advanced presbyopia stage because then they're really going to appreciate that difference and that improvement."

Dr. Harvey suggests speaking to

patients about the alternatives to LVC or intraocular surgery. "I think that some of the presbyopia-correcting drops do offer the ability to temperize things a little bit and perhaps delay surgery temporarily until patients have reached a more suitable age," he says. "That's something that can be really helpful. When meeting with hyperopic patients, it's also an opportunity for them to become educated about contact lenses. Many of them are extremely hesitant to try contact lenses, as opposed to myopes who seem to 'eat up' contact lenses like they're going out of style. With appropriate education and training, hyperopes can actually benefit and learn about some of the advantages of multifocality, too."

Ultimately, chair time is essential, says Dr. Loh. "The most important thing when dealing with hyperopic patients and refractive surgery is lots of education: understanding their needs; understanding their desires; understanding where they are in the presbyopia journey," she concludes. "Usually they're coming to us in their 40s and 50s thinking they'll just get LASIK. You have to be willing to spend time discussing and educating them on other options." ◀

1. Vitale S., Sperduto R.D., Ferris F.L., 3rd Increased prevalence of myopia in the United States between 1971–1972 and 1999–2004. *Arch Ophthalmol* 2009;127:1632–1639.

2. Hyperopia. <https://eyewiki.org/Hyperopia>. Accessed May 29, 2024.

3. Kohnen T. Advances in the surgical correction of hyperopia (editorial). *J Cataract Refract Surg* 1998;24:1–2.

4. McGhee CN, Anastas CN, Jenkins L, et al. The surgical and laser correction of hypermetropia. In: McGhee CNJ, Taylor HR, Trokel S, Gartry D, eds. *Excimer lasers in ophthalmology: Principles and practice*. London: Martin Dunitz 1997:273–94.

5. Moshirfar M, Megerdichian A, West WB, Miller CM, Sperry RA, Neilsen CD, Tingey MT, Hoopes PC. Comparison of visual outcome after hyperopic LASIK using a wavefront-optimized platform versus other excimer lasers in the past two decades. *Ophthalmol Ther* 2021;10:3:547–563.

6. Reinstein DZ, Sekundo W, Archer TJ, Stodulka P, Ganesh S, Cochener B, Blum M, Wang Y, Zhou X. SMILE for hyperopia with and without astigmatism: Results of a prospective multicenter 12-month study. *J Refract Surg* 2022;38:12:760–769.

DISCLOSURES

Dr. Harvey is a medical monitor for Lenstec and a consultant with Johnson & Johnson Vision and Visus Therapeutics.

Dr. Hersh is a consultant for Allotex. **Dr. Loh** is a consultant and speaker for Alcon, Bausch + Lomb and Johnson & Johnson Vision.

IOL CALCULATION FOR UNUSUAL EYES

Using newer-generation formulas is the key for hitting your refractive targets, surgeons say.

CHRISTINE YUE LEONARD
SENIOR ASSOCIATE EDITOR

Navigating intraocular lens calculation in patients with atypical eyes presents a unique challenge for cataract surgeons. Since these eyes deviate from the norm, standard formulas aren't sufficient to factor in the many anatomical differences. In this article, experts discuss how the latest formulas can help surgeons achieve accurate IOL power calculation in eyes with keratoconus, post-refractive eyes and eyes with extreme axial lengths.

Modern Formulas

Variations in ocular anatomy impact the accuracy of traditional formulas. Experts say that the newer-generation formulas available today, which incorporate more anatomical parameters, are helping surgeons get closer to their targets. "When you have an average eye with normal axial length and normal Ks, all the formulas seem to work well and converge into a good number," says William B. Trattler, MD, of Bascom

Palmer Eye Institute. "But as the axial length increases or shortens, there's more opportunity for errors in the formulas because the anatomy isn't always the same.

"The effective lens position can differ more in unusual eyes," he continues. "For example, a shorter eye could still have a normal anterior chamber depth and therefore the lens is back a bit farther. Or, you could have a patient with a short axial length and a very narrow anterior chamber, and therefore the effective lens position after surgery will be farther forward, closer to the cornea. The modern formulas that take into account other parameters such as anterior chamber depth, corneal shape and keratometry, for example, are more likely to be on target because they're using multiple anatomical features to try to estimate where the effective lens position will be after surgery."

Unusual eyes typically include those with unusual corneas—such as keratoconus or post-refractive eyes—and those with unusual axial lengths. "There are specialized formulas that have been developed for

each of these scenarios," Dr. Trattler says. "Many biometers have some of the formulas integrated into them. For example, the Argos and IOLMaster700 both have formulas integrated for the post-LASIK patients. You have to select whether it's post-myopic or post-hyperopic LASIK. Then, you just toggle that and get the integrated printout. There's no risk of transcription errors this way."

Preoperative Measurements

Precise imaging is a crucial step for ensuring accurate IOL power calculation, particularly in unusual eyes. Divya Srikumaran, MD, of the Wilmer Eye Institute at Johns Hopkins University, says that all of her patients with corneal problems who are having cataract surgery undergo corneal tomography with Pentacam, in addition to biometry with a LenStar or IOLMaster. "[Corneal tomography] gives us information about the regularity of the patient's astigmatism and total corneal power," she says. "It's especially helpful for patients who are post-refractive surgery or who have keratoconus.

This article has no commercial sponsorship.

Dr. Raviv is a consultant for Johnson & Johnson. Dr. Trattler is a consultant for RxSight, Johnson & Johnson, Bausch + Lomb, Rayner and Zeiss. Dr. Srikumaran and Dr. Tonk have no related financial disclosures.

BARRETT TRUE K FORMULA - FOR PRIOR MYOPIC OR HYPEROPIC LASIK/PRK/RK + KC

Patient Data Universal Formula Formula Guide K INDEX 1.3375 K INDEX 1.332

Calculate Reset Form ENTER DATA AND CALCULATE

Doctor Name Patient Name Patient ID

Lens Factor (-2.0-5.0) or A Constant (112-125) Personal Constant

History OD: Myopic Lasik History OS: Keratoconus

Pre-Lasik Ref. (R) Post-Lasik Ref. (R) Pre-Lasik Ref. (L) Post-Lasik Ref. (L)

Measurements:	OD	OS
Axial Length (R)	<input type="text"/> (12-38 mm)	Axial Length (L) <input type="text"/> (12-38 mm)
Measured K1 (R)	<input type="text"/> (30-60 D)	Measured K1 (L) <input type="text"/> (30-60 D)
Measured K2 (R)	<input type="text"/> (30-60 D)	Measured K2 (L) <input type="text"/> (30-60 D)
Optical ACD (R)	<input type="text"/> (0-6 mm)	Optical ACD (L) <input type="text"/> (0-6 mm)
Target Ref. (R)	<input type="text"/> 0 (-10-10 D)	Target Ref. (L) <input type="text"/> 0 (-10-10 D)

Optional:

Lens Thickness (R) (2-8 mm) Lens Thickness (L) (2-8 mm)

WTW (R) (8-14 mm) WTW (L) (8-14 mm)

APACRS.org

that you can predict the posterior cornea based on the anterior cornea using a standard index, gets thrown out. These eyes are more prone to refractive surprises because of that altered ratio.

“The second challenge of keratoconus eyes is the effective lens position prediction error, since traditional methods of estimating ELP may fall short in these unusual corneas. The third challenge is the difficulty in obtaining accurate measurements of true central corneal power,” he continues. “The combination of all three of those things typically leads to very reduced refractive accuracy, and frequently, hyperopic surprises for patients.”

Experts say that one of the best tools surgeons can use when calculating IOL power in keratoconus eyes is to use the most recent keratoconus formulas: the Barrett True K and Kane Keratoconus. “Up until about five years ago, the long-standing SRK/T formula seemed to be the best in keratoconus, but in recent years, we now have keratoconus-specific formulas, and they’re the most accurate,” says Tal Raviv, MD, of Eye Center of New York. “They can be found online for free (see sidebar “Links to Online Formulas”). You just check off the keratoconus box, put in the case, and those are your best chances of coming pretty close.

“Studies show that with Ks up until 50, you can target a little bit below plano and will usually do pretty well with those formulas,” he continues. “But once you go above 50, even the best keratoconus formulas start to fall short. I usually target more myopia the higher the Ks are, just to err on the side of myopia and not hyperopia. That’s my trick for keratoconus.”

It’s important that surgeons know about these new formulas, stresses Dr. Tonk. To enhance calculation accuracy, he uses the IOLMaster’s total keratometry measurement. Dr. Tonk, who has no financial inter-

The Barrett True K formula is one of the most up-to-date formulas for keratoconus.

Tomography is critical.”

“For imaging of patients [with unusual eyes], I typically like to have a Placido disc-based topography as well as Scheimpflug tomography (Pentacam),” says Rahul Tonk, MD, MBA, of Bascom Palmer Eye Institute. “I prefer to have two separate instruments looking at the corneal shape and curvature. I also like to have an IOL biometry device such as the IOLMaster700, which measures total keratometry, and preoperative OCT of the retina to evaluate for any posterior segment pathology that might limit certain IOL choices.”

Addressing any ocular surface issues, such as dry eye and meibomian gland dysfunction, before obtaining preoperative measurements helps to ensure accurate assessments and successful outcomes. “We’ve all come to recognize the importance of making sure that the ocular surface is optimized,” Dr. Srikumaran says. “[The ocular surface] impacts astigmatism measurements and the outcomes of all of our keratometry readings, which can have a significant impact on IOL calculation. I can’t under-

state the importance of that. If the ocular surface isn’t optimized prior to your measurements, don’t hesitate to repeat them.”

Dr. Trattler agrees. “I’m a big fan of doing a second measurement. I don’t do it for every case, but if patients have unusual anatomy or keratoconus or are post-LASIK, their measurements can be more aberrant. We typically treat patients for some presumed ocular surface disease, which is quite common, and bring them back for a second set of readings. They get two sets of readings because we think there may be some variability in the keratometry.”

Keratoconus

There are three challenges with keratoconus eyes, according to Dr. Tonk. “One is that there’s an altered anterior-posterior corneal curvature ratio,” he explains. “In most devices, the front surface of the cornea is measured and then some standard index is used to predict the characteristics of the posterior cornea. In an eye with keratoconus, and in any eye with an abnormal cornea, that ratio is altered. So, the assumption

THE POWER OF **CARE**

You're there for them. We're here for you.

Care is everything. Integrated EHR/PM software makes healthcare better for everyone.

- Ophthalmology-specific workflows
- Robust revenue cycle management
- Hands-free mobile documentation
- Frictionless interoperability

NextGen.com/Power-OPH

iolfomula.com

Experts caution that when using total keratometry in formulas such as the Kane Keratoconus, the anterior and posterior corneal values must be inputted separately.

est in Zeiss, says “total keratometry measures the curvature of both the front and the back surface of the cornea directly, rather than just measuring the front surface and predicting the back surface. The developments of new formulas that take total keratometry into account have really improved our refractive accuracy for patients with keratoconus.”

In a 2023 multicenter study¹ of 87 eyes of 67 patients with keratoconus by Dr. Tonk and his colleagues, the Barrett True K with total keratometry (measured posterior corneal astigmatism) achieved 35.4 percent of eyes within 0.5 D and 72.7 percent within 1 D, which was significantly better than formulas that used standard keratometry (predicted posterior astigmatism) alone. The group reported that without total keratometry, Barrett True K-K performed reasonably well, as did the Kane Keratoconus-K for eyes with severe keratoconus (steep K < 50 D).

“If you have total keratometry, then your very best option across the board is to use the Barrett True K-TK,” Dr. Tonk says. “Not everyone has total keratometry, however,

so if you don’t have it, you can use the Barrett True K with standard keratometry.”

He adds it’s important to note that you can’t substitute total keratometry values for standard keratometry values in online calculators. “If you’re going to use total keratometry, you have to separately input the anterior corneal values, i.e., your standard keratometry, and separately input your posterior corneal values, which are on a separate column of the IOL-Master device.”

Many surgeons run their calculations through multiple formulas and compare them. “We tend to get hyperopic errors in keratoconus patients, and these errors aren’t well tolerated,” explains Dr. Srikumaran. “These patients are used to being very myopic their entire lives and it’s quite disturbing to suddenly end up hyperopic. I compare all the formulas and then take the highest power IOL because that’s going to have less chance of ending up with a hyperopic error. I’d rather err on the side of myopia. There isn’t always agreement [among the formulas] unfortunately, because they all have different strategies for adjusting for corneal power.”

Surgeons say that when it comes to IOL selection in keratoconus patients, their preferred lenses include the Light-Adjustable Lens, small aperture IOLs and monofocals. “If the patient’s astigmatism is regular and they’ve had stable corneas for years and aren’t wearing RGPs, I try to treat the astigmatism,” says Dr. Raviv. “For keratoconus patients wearing glasses, any reduction in astigmatism is helpful, so I do believe in using monofocal torics for keratoconus. In irregular keratoconic eyes, we can consider small aperture IOLs, but I’m hesitant to use these lenses in very irregular keratoconic eyes with 7 or 8 D of astigmatism because that pinhole optic is still not enough to address all that.”

Dr. Raviv says the Light-Adjustable Lens is another good option, with “the limitation that we can only adjust maybe 1 or 2 D, maximum 3 D of astigmatism postop. We want to use it in keratoconic eyes that are going to be within that range—not the super high astigmatic ones, at least not by itself. There are a few surgeons who do piggyback IOLs with LALs and other lenses, but we aren’t yet sure how efficacious that is in the long term. All the issues of piggyback lenses come into play when we do that, including interlenticular opacification and iris chafing if the lens is put in the sulcus.”

“For keratoconus, I typically use a neutral asphere monofocal lens,” says Dr. Trattler. “The LAL is my other go-to.”

Post-refractive Eyes

As with keratoconus, the latest formulas tailored for post-refractive eyes, including the EVO 2.0, Barrett True K, Pearl DGS and Hoffer QST, seem to offer the most accuracy, surgeons say. “We’ve found that the combination of one of these modern formulas and total keratometry is the best way to predict IOL power for patients who have had myopic laser vision correction,” says Dr. Tonk, citing a 576-eye study he

To treat ocular inflammation and pain following ophthalmic surgery or ocular itching associated with allergic conjunctivitis.

DEXTENZA KEEPS PATIENTS

COMPLIANT

AND SATISFIED^{1-3*}

A hands-free advancement in ophthalmic steroid treatment.^{1,4}

Easy-to-insert[†] and preservative-free intracanalicular DEXTENZA offers patients a satisfying post-op experience—providing up to 30 days of sustained steroid coverage.¹⁻⁵

INDICATIONS

DEXTENZA is a corticosteroid indicated for:

- The treatment of ocular inflammation and pain following ophthalmic surgery.
- The treatment of ocular itching associated with allergic conjunctivitis.

IMPORTANT SAFETY INFORMATION

CONTRAINDICATIONS

DEXTENZA is contraindicated in patients with active corneal, conjunctival or canalicular infections, including epithelial herpes simplex keratitis (dendritic keratitis), vaccinia, varicella; mycobacterial infections; fungal diseases of the eye, and dacryocystitis.

WARNINGS AND PRECAUTIONS

Intraocular Pressure Increase - Prolonged use of corticosteroids may result in glaucoma with damage to the optic nerve, defects in visual acuity and fields of vision. Steroids should be used with caution in the presence of glaucoma. Intraocular pressure should be monitored during treatment.

Bacterial Infections - Corticosteroids may suppress the host response and thus increase the hazard for secondary ocular infections. In acute purulent conditions, steroids may mask infection and enhance existing infection.

Viral Infections - Use of ocular steroids may prolong the course and may exacerbate the severity of many viral infections of the eye (including herpes simplex).

Fungal Infections - Fungus invasion must be considered in any persistent corneal ulceration where a steroid has been used or is in use. Fungal culture should be taken when appropriate.

Delayed Healing - Use of steroids after cataract surgery may delay healing and increase the incidence of bleb formation.

Other Potential Corticosteroid Complications - The initial prescription and renewal of the medication order of DEXTENZA should be made by a physician only after examination of the patient with the aid of magnification, such as slit lamp biomicroscopy, and, where appropriate, fluorescein staining. If signs and symptoms fail to improve after 2 days, the patient should be re-evaluated.

ADVERSE REACTIONS

Ocular Inflammation and Pain Following Ophthalmic Surgery

The most common ocular adverse reactions that occurred in patients treated with DEXTENZA were: anterior chamber inflammation including iritis and iridocyclitis (10%), intraocular pressure increased (6%), visual acuity reduced (2%), cystoid macular edema (1%), corneal edema (1%), eye pain (1%), and conjunctival hyperemia (1%). The most common non-ocular adverse reaction was headache (1%).

Itching Associated with Allergic Conjunctivitis

The most common ocular adverse reactions that occurred in patients treated with DEXTENZA were: intraocular pressure increased (3%), lacrimation increased (1%), eye discharge (1%), and visual acuity reduced (1%). The most common non-ocular adverse reaction was headache (1%).

Please see adjacent Brief Summary of full Prescribing Information.

* 93% (187/201) of DEXTENZA patients were satisfied with the insert in the third Phase 3 Study for the treatment of ocular inflammation and pain following ophthalmic surgery.³

† 73.6% of physicians in Study 1, 76.4% in Study 2, and 79.6% in Study 3, for the treatment of ocular inflammation and pain following ophthalmic surgery, rated DEXTENZA as easy to insert.^{2,5}

References: 1. DEXTENZA [package insert]. Bedford, MA: Ocular Therapeutix, Inc; 2021. 2. Tyson SL, et al. *J Cataract Refract Surg.* 2019;45(2):204-212 [erratum in: 2019;45(6):895]. 3. Data on File 00837. Ocular Therapeutix, Inc. 4. Sawhney AS, et al., Inventors, Incept, LLC, Assignee. Drug Delivery Through Hydrogel Plugs. US patent 8,409,606 B2. April 2, 2013. 5. Walters T, et al. *J Clin Exp Ophthalmol.* 2016;7(4):1-11.

Dextenza[®]
(dexamethasone ophthalmic insert) 0.4mg
for intracanalicular use

Dextenza®

(dexamethasone ophthalmic insert) 0.4 mg
for intracanalicular use

BRIEF SUMMARY: Please see the DEXTENZA Package Insert for full prescribing information (10/2021)

1 INDICATIONS AND USAGE

1.1 Ocular Inflammation and Pain Following Ophthalmic Surgery

DEXTENZA® (dexamethasone ophthalmic insert) is a corticosteroid indicated for the treatment of ocular inflammation and pain following ophthalmic surgery (1.1).

1.2 Itching Associated with Allergic Conjunctivitis

DEXTENZA® (dexamethasone ophthalmic insert) is a corticosteroid indicated for the treatment of ocular itching associated with allergic conjunctivitis (1.2).

4 CONTRAINDICATIONS

DEXTENZA is contraindicated in patients with active corneal, conjunctival or canalicular infections, including epithelial herpes simplex keratitis (dendritic keratitis), vaccinia, varicella; mycobacterial infections; fungal diseases of the eye, and dacryocystitis.

5 WARNINGS AND PRECAUTIONS

5.1 Intraocular Pressure Increase

Prolonged use of corticosteroids may result in glaucoma with damage to the optic nerve, defects in visual acuity and fields of vision. Steroids should be used with caution in the presence of glaucoma. Intraocular pressure should be monitored during the course of the treatment.

5.2 Bacterial Infection

Corticosteroids may suppress the host response and thus increase the hazard for secondary ocular infections. In acute purulent conditions, steroids may mask infection and enhance existing infection [see Contraindications (4)].

5.3 Viral Infections

Use of ocular steroids may prolong the course and may exacerbate the severity of many viral infections of the eye (including herpes simplex) [see Contraindications (4)].

5.4 Fungal Infections

Fungus invasion must be considered in any persistent corneal ulceration where a steroid has been used or is in use. Fungal culture should be taken when appropriate [see Contraindications (4)].

5.5 Delayed Healing

The use of steroids after cataract surgery may delay healing and increase the incidence of bleb formation.

5.6 Other Potential Corticosteroid Complications

The initial prescription and renewal of the medication order of DEXTENZA should be made by a physician only after examination of the patient with the aid of magnification, such as slit lamp biomicroscopy, and, where appropriate, fluorescein staining. If signs and symptoms fail to improve after 2 days, the patient should be re-evaluated.

6 ADVERSE REACTIONS

The following serious adverse reactions are described elsewhere in the labeling:

- Intraocular Pressure Increase [see Warnings and Precautions (5.1)]
- Bacterial Infection [see Warnings and Precautions (5.2)]
- Viral Infection [see Warnings and Precautions (5.3)]
- Fungal Infection [see Warnings and Precautions (5.4)]
- Delayed Healing [see Warnings and Precautions (5.5)]

6.1 Clinical Trials Experience

Because clinical trials are conducted under widely varying conditions, adverse reaction rates observed in the clinical trials of a drug cannot be directly compared to rates in the clinical trials of another drug and may not reflect the rates observed in practice. Adverse reactions associated with ophthalmic steroids include elevated intraocular pressure, which may be associated with optic nerve damage, visual acuity and field defects, posterior subcapsular cataract formation; delayed wound healing; secondary ocular infection from pathogens including herpes simplex, and perforation of the globe where there is thinning of the cornea or sclera [see Warnings and Precautions (5)].

6.2 Ocular Inflammation and Pain Following Ophthalmic Surgery

DEXTENZA safety was studied in four randomized, vehicle-controlled studies (n = 567). The mean age of the population was 68 years (range 35 to 87 years), 59% were female, and 83% were white. Forty-seven percent had brown iris color and 30% had blue iris color. The most common ocular adverse reactions that occurred in patients treated with DEXTENZA were: anterior chamber inflammation including iritis and iridocyclitis (10%); intraocular pressure increased (6%); visual acuity reduced (2%); cystoid macular edema (1%); corneal edema (1%); eye pain (1%) and conjunctival hyperemia (1%). The most common non-ocular adverse reaction that occurred in patients treated with DEXTENZA was headache (1%).

6.3 Itching Associated with Allergic Conjunctivitis

DEXTENZA safety was studied in four randomized, vehicle-controlled studies (n = 154). The mean age of the population was 41 years (range 19 to 69 years), 55% were female and 61% were white. Fifty seven percent had brown iris color and 20% had blue iris color. The most common ocular adverse reactions that occurred in patients treated with DEXTENZA were: intraocular pressure increased (3%); lacrimation increased (1%); eye discharge (1%); and visual acuity reduced (1%).

The most common non-ocular adverse reaction that occurred in patients treated with DEXTENZA was headache (1%).

8 USE IN SPECIFIC POPULATIONS

8.1 Pregnancy

Risk Summary

There are no adequate or well-controlled studies with DEXTENZA in pregnant women to inform a drug-associated risk for major birth defects and miscarriage. In animal reproduction studies, administration of topical ocular dexamethasone to pregnant mice and rabbits during organogenesis produced embryofetal lethality, cleft palate and multiple visceral malformations [see Animal Data].

Data

Animal Data

Topical ocular administration of 0.15% dexamethasone (0.75 mg/kg/day) on gestational days 10 to 13 produced embryofetal lethality and a high incidence of cleft palate in a mouse study. A daily dose of 0.75 mg/kg/day in the mouse is approximately 5 times the entire dose of dexamethasone in the DEXTENZA product, on a mg/m² basis. In a rabbit study, topical ocular administration of 0.1% dexamethasone throughout organogenesis (0.36 mg /day, on gestational day 6 followed by 0.24 mg/day on gestational days 7-18) produced intestinal anomalies, intestinal aplasia, gastroschisis and hypoplastic kidneys. A daily dose of 0.24 mg/day is approximately 6 times the entire dose of dexamethasone in the DEXTENZA product, on a mg/m² basis.

8.2 Lactation

Systemically administered corticosteroids appear in human milk and could suppress growth and interfere with endogenous corticosteroid production; however the systemic concentration of dexamethasone following administration of DEXTENZA is low [see Clinical Pharmacology (12.3)]. There is no information regarding the presence of DEXTENZA in human milk, the effects of the drug on the breastfed infant or the effects of the drug on milk production to inform risk of DEXTENZA to an infant during lactation. The developmental and health benefits of breastfeeding should be considered along with the mother's clinical need for DEXTENZA and any potential adverse effects on the breastfed child from DEXTENZA.

8.4 Pediatric Use

Safety and effectiveness in pediatric patients have not been established.

8.5 Geriatric Use

No overall differences in safety or effectiveness have been observed between elderly and younger patients.

17 PATIENT COUNSELING INFORMATION

Advise patients to consult their eye care professional if pain, redness, or itching develops.

Ocular
Therapeutix®

Ocular Therapeutix, Inc.
Bedford, MA 01730 USA
PP-US-DX-0360

Cover Story IOL CALCULATION

and his colleagues published this year.²

“The best formulas for 2024 for predicting IOL power in post-myopic LVC patients are the EVO 2.0 with posterior keratometry (PK), the Barrett True K-TK and the Pearl DGS-PK. All three of these formulas are new and all three involve posterior or total keratometry,” he says.

“If you don’t have total keratometry, you can still use some of these new formulas with standard keratometry,” he continues. “In those situations, the top two formulas were the Pearl DGS-K and the EVO 2.0-K, which were statistically significantly better than the Barrett True K No History (NH)-K or the Barrett True K-K.”

Dr. Tonk presented an abstract at this year’s ASCRS meeting on 153 post-hyperopic LVC eyes as well. “We found that when using total keratometry, the Barrett True K-TK and EVO 2.0-PK performed the best,” he says.

“Without total keratometry, the EVO 2.0-K and Barrett True K-NH are reasonable performers.”

In eyes with prior radial keratotomy for myopia, the Barrett True-K NH and the ASCRS Maximum power were found to be more accurate than the Humphrey Atlas method, IOLMaster/Lenstar method and ASCRS Average power formulas, according to a 2023 retrospective study³ of 25 eyes that compared the accuracy of IOL power prediction of the formulas available on the ASCRS’ post-refractive calculator.

“The LAL gets the patient all the way to the finish line in these eyes that are more difficult to calculate,” says Dr. Trattler. “I use this lens for most of my patients with a history of previous LASIK now, as well as for post-RK patients.”

Dr. Raviv says that in addition the LAL, he likes to use EDOF lenses such as the Symphony OptiBlue, in post-refractive eyes. “It’s hard to reach exactly plano in these eyes with a standard, non-adjustable lens, so we want to go with one that’s forgiving,” he says.

Extreme Axial Lengths

“For extreme axial lengths, but especially long eyes, one of the big challenges is getting an accurate measurement,” says Dr. Srikumaran. “Sometimes patients have staphylococci, and if they have poor vision, they also have poor fixation. It’s important to try to get the optical biometry when you’re confident that you’re getting good fixation in the fovea. The IOLMaster700, which shows you where it’s fixating on the fovea, can be very helpful.”

Links to Online Formulas

- Barrett True K: <https://www.apacrs.org/disclaimer.asp?info=2>
- Kane KCN: <https://www.iolformula.com/>
- ESCRS Calculator: <https://iolcalculator.escrs.org/>

Surgeons can compare the outputs of multiple formulas using the European Society of Cataract and Refractive Surgery's online calculator. Experts advise choosing the result that leaves the patient either plano or with slight myopia.

“Also be sure to recognize when you have an error in your measurements,” she continues. “Some of these really long eyes, for example, may have been vitrectomized or have buckles if they’ve had prior retinal problems, and those can throw off your measurements. That’s something to keep in mind as you’re doing your measurements.”

Dr. Srikumaran asys her favorite formula is the Barrett Universal II for long and short eyes. “I also really like the Hill RBF formula,” she says. “Over the years, it’s expanded. Before, there were cut-offs and you couldn’t do extreme axial lengths, but now if there’s an expanded range available, you can do the Hill RBF calculator as well on the ASCRS site. I like to compare formulas and make a decision.”

Today’s formulas for long and short eyes are much better, Dr. Trattler says. “I feel very comfortable using Barrett [Universal II] in shorter eyes as well as longer eyes now.”

“Some of the best formulas for very long or very short eyes are the newer generation formulas that many of us don’t have on our biometers,” Dr. Raviv says. “The Pearl DGS, EVO, Hoffer QST and Kane formulas are excellent formulas for long and short eyes. The SRK/T, Holladay and Hoffer fall short in 2024.”

“Short eyes are some of the most challenging eyes to calculate because as we go up in power, the lens implants that we use are in the 30-D range and we have less predictable effective lens position,” Dr. Raviv continues. “Even a millimeter for-

wards or backwards from that plano positioning of these IOLs can affect the refractive outcome. So, these are the most challenging eyes, and for these eyes, I use the latest formulas on the ESCRS website.”

When consulting the various outputs of the different formulas on the ESCRS website, Dr. Raviv says he looks at all the results and picks the one that will leave the patient either plano or with slight myopia. “For example, in a very high myope, I’ll choose one that is either plano or at worse minus 2, as opposed to plano or plus 2.”

“On the hyperopic side, it’s a little trickier,” he adds. “For these patients, patient education is going to be key. It’s good for them to be aware that the smaller axial length, the more the residual refractive error. I sometimes show them the formulas we have on the screen, so they understand how each one shows a different lens. That lets them know that we’re going to get as close as we can. If the LAL is an option, then they understand why the LAL exists, and they may opt for that if they’re really particular or want the best chance of reaching a specific refractive target. I also use ORA in these very long or very short eyes. I find it helps sometimes, but it doesn’t predict ELP.”

“Even with the more advanced formulas, the standard deviation is higher than for normal patients,” Dr. Trattler says. “So, we’re still not as accurate in these unusual eyes. That’s why we consider options like the LAL or discuss with patients that we may need to do a piggyback lens or IOL exchange if it’s not on target.”

1. Heath MT, Mulpuri L, Kimiagarov E, et al. Intraocular lens power calculations in keratoconus eyes comparing keratometry, total keratometry, and newer formulae. *Am J Ophthalmol* 2023;253:206-214.

2. Anter AM, Bleeker AR, Shammass HJ, et al. Comparison of legacy and new no-history IOL power calculation formulas in postmyopic laser vision correction eyes. *Am J Ophthalmol* 2024;264:44-52.

3. Shetty N, Sathe P, Aishwarya, et al. Comparison of intraocular lens power prediction accuracy of formulas in American Society of Cataract and Refractive Surgery post-refractive surgery calculator in eyes with prior radial keratotomy. *Indian J Ophthalmol* 2023;71:9:3224-3228.

GOING GREEN IN OPHTHALMOLOGY

Pharmaceutical companies and surgeons are working towards more sustainable eye care.

ANDREW BEERS
ASSOCIATE EDITOR

Government and non-profit organizations have warned about the role the health-care system plays in climate change. In 2020, the U.S. health-care system attributed to 8.5 percent of greenhouse gas emissions nationally, rising approximately 6 percent between 2010 and 2018.¹ This was and continues to be impacted by hospital care, physician and clinical services and prescription drug usage in America.¹ A large contingent of physicians and companies are calling for sustainability efforts to be enacted to ensure the health and well-being of patients, especially in ophthalmology. Here, we'll look at the shape these efforts are taking.

Ophthalmology's Impact

Surgical procedures and treatments in ophthalmology require the use of multiple instruments, drugs and other surgical materials that ultimately contribute to the carbon footprint of a physician's clinic. Due to differing surgical demands around the world, the carbon footprints of ophthalmology clinics will vary.

"When we think about ophthalmology, our most commonly performed surgical procedure is cataract surgery," says Emily Schehlein, MD, an ophthalmologist at Brighton Vision Center in Michigan. "Carbon footprint is the emissions associated with the full life cycle of a product or event like, for example, cataract surgery, measured in carbon dioxide equivalents. There's a great study that has been done that actually measured the carbon footprint of cataract surgery and compared India to the United Kingdom."²

"In India, the carbon footprint was 6 kg CO₂ equivalents as compared to over 180 in the United Kingdom. What this equals is over 1.16 million kg CO₂ equivalents each year in the U.K., or 250,000 cars driven for one year. This is a really significant amount of waste. So, it's really a responsibility of ophthalmology as an industry and surgeons to take steps to ensure that our surgeries and our clinics are more sustainable locally, and then of course nationally and globally as well."

Surgical interventions and other treatments lead to biohazardous waste, which, when not properly disposed of, can impact the environment negatively.

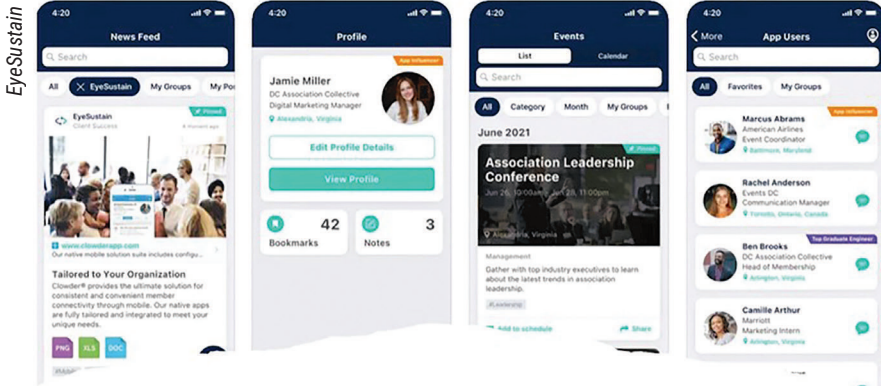
"Hazardous materials are regulated by state and federal law, such that they have to be disposed of in a careful manner and removed from the practice by a licensed company," explains Todd Sack, MD, the executive director of My Green Doctor Foundation. "Hazardous materials can be minimized by putting them in a distinct bag and distinct disposal container and not putting non-hazardous stuff in those bags, because they're very expensive to dispose of."

What Dr. Sack pointed out about putting non-hazardous materials into the disposal bags is the issue that's contributing greatly to waste buildup in clinics. Dr. Schehlein further explains, "This is a complex issue, but the most important part of managing biohazardous waste is properly segregating the waste. It's believed that almost 90 percent of red bag, or hazardous waste, doesn't meet the criteria for 'hazardous waste.' This may be in part due to lack of recycling bins, or bins placed in inaccessible locations.³ Much of the excessive waste in ophthalmology is from a mindset of single-use and a lack of awareness of where our waste goes and what's being thrown away."

"But it's not the hazardous materials

This article has no commercial sponsorship.

Dr. Hovanesian is a consultant for Alcon, AbbVie, Bausch + Lomb and Johnson & Johnson. Dr. Sack and Schehlein have no financial interests to disclose.



Download the EyeSustain app for free from the Apple or Google Play stores to learn more about how to manage and improve ophthalmic sustainability. Simply create an account and stay informed on the latest news in sustainability.

that physicians and nurses need to be so concerned about, because we're going to have hazardous materials, and we can't decrease those," says Dr. Sack. "There's going to be some materials that have blood and other secretions on them. It's through the non-hazardous materials that we can minimize the waste by reusing them."

"Across all ophthalmology, there's many packing designs for materials and drugs that we could change to reduce waste," says Dr. Schelein. One concern in health care is the use of paper Instructions for Use and materials used for shipping and handling. "Intravitreal injections come with a paper IFU. They come with significant drug packaging for individual doses, the need for transportation, and the need for climate-controlled storage and disposal."

EyeSustain (a coalition of organizations working to make ophthalmic care more sustainable), the American Academy of Ophthalmology, the American Society of Cataract and Refractive Surgery and the European Society of Cataract and Refractive Surgery published a position paper on reducing ophthalmic surgical waste by implementing electronic IFUs.⁴ They conducted a survey to assess the pharmaceutical industry's views on eliminating paper IFUs. A total of 32 manufacturers replied to the survey, with 95 percent of them agreeing that switching to electronic IFUs would be an acceptable alternative. However, only

30 percent of these manufacturers had made the effort to implement electronic methods.

This joint paper led to the proposition from the AAO to pass the Prescription Information Modernization Act (H.R. 1503). This is a bipartisan legislation that would allow the U.S. Food and Drug Administration to propose a rule that would allow pharmaceutical companies the opportunity to transmit prescribing information electronically, instead of printing out the instructions, which is currently required. Physicians who want to support the act can visit the AAO's website and fill out a form which will send a letter to their U.S. Representative.

Electronic IFUs may be a drop in the bucket for sustainability in ophthalmology, but other packaging designs are tougher to change. "Any packaging around a surgical product has to be validated for its ability to withstand mechanical trauma, temperature trauma and a variety of external factors that could compromise the product inside," says John Hovanesian, MD, an ophthalmologist at Harvard Eye Associates in Laguna Hills, California. "And if a package is changed, the manufacturer has to go through a lengthy validation process on any new packaging that really is a disincentive from streamlining packaging. And there are standards not just imposed by the FDA, but by groups like ISO, the International Standards Organization, or ANSI, the American

National Standards Institute, that are imposed on manufacturers for validation of these packages. And so, for us to ask them to or for them to initiate downsizing of packaging is much more complicated than most of us know."

Industry Initiatives

Pharmaceutical companies have been putting in effort towards sustainability by implementing green initiatives and helping physicians and patients reduce, reuse and recycle. Here are how various companies are making an impact:

- **Alcon.** "Alcon has an organized effort toward what they call a 'Greenest' movement in the company, where for every new product that's designed, one of the elements in consideration is environmental impact," says Dr. Hovanesian. "And they've incorporated a lot of things to reduce packaging. They've moved to more sustainable packaging like a green cell foam that they're using in some of their products."

Alcon has been pushing for sustainability in ophthalmology with their Global Environmental Sustainability Strategy. This strategy focuses on sustainable products and services, energy efficiency and greenhouse gas reduction, operational waste and water stewardship.

According to Alcon's 2023 Social Impact and Sustainability Report, they were able to continue their efforts towards reusing, recycling or donating medical equipment and reduce their greenhouse gas emissions. In 2021, Alcon was able to reuse, recycle or donate 108 kg of equipment. This continued through 2022 and 2023, with a total of 102 kg of equipment reused, recycled or donated last year alone. Additionally, their greenhouse gas emissions reduced from 309,083 kg CO₂ equivalents in 2021 to 233,482 kg CO₂ equivalents in 2023.

A part of Alcon's sustainability strategy is to reduce 100 percent of non-hazardous waste generated at manufacturing sites by 2030. They were able to divert 95.9 percent of annual waste from landfills in 2023 and were able to reduce the amount of waste generated

by approximately 956 kg.

Water is crucial for a sustainable environment and Alcon has implemented several projects to save on water. Last year, 12 projects were implemented globally, which led to Alcon saving over 110 megaliters of water. Their projects also focused on installing new water treatment systems and decommissioning old product lines for health-care facilities.

• **Bausch + Lomb.** “Bausch + Lomb, in the contact lens space, has put together a recycling program,” says Dr. Hovanesian. “So, both the packaging and the actual contact lenses themselves can be recycled.” Sustainability impact reports aside, Bausch + Lomb has created an initiative that both physicians and their patients can get involved with.

The Biotrue Eye Care Recycling program allows patients and physicians a way to recycle drop-bottle packaging and contact lens cases. Bausch + Lomb teamed up with TerraCycle, an industry leader in all things recyclable, to develop their program. TerraCycle works with businesses, government entities and individuals around the world to ensure proper recycling practices are being employed. Users of the service can recycle products at a TerraCycle recycling center or ship them to a TerraCycle facility where it can be processed properly rather than being wasted.

As a part of the Biotrue Eye Care Recycling program, patients can go to the program’s website to get a step-by-step tutorial on how to recycle contact lens products. First, separate the products that can be traditionally recycled and the products that should be recycled with TerraCycle. For example, Biotrue Hydration Boost lubricant eye drops come in a plastic eye drop bottle with a plastic cap that’s placed into a cardboard box. The cardboard box can be traditionally recycled, while Bausch + Lomb’s bottle and cap are too small and must be sent to a TerraCycle facility. Also, single-use eye droppers and contact lens cases that come in the Biotrue packaging can be recycled with TerraCycle. Fortunately, this program isn’t limited to Bausch +



The NanoDropper adaptor consists of a tip, base and cap. It’s shipped to the patient pre-sterilized, so it can’t be used for more than one medication. Additionally, the tip can get clogged which results in a loss of eye drop solution. Ensure that the eye dropper is properly stored in an upright position and expel the air from the dropper before each use to avoid clogging.

Lomb’s products and they’ve opened it up to allow any brand’s packaging to be recycled.

The next step in the Biotrue Eye Care Recycling program is to create a TerraCycle account, which is free to do. After a patient creates an account, they can collect their recyclable items, place them into a recyclable box, and print out a shipping label on TerraCycle’s website to send the package to a recycling facility.

The One by One Recycling program is another partnering program with TerraCycle, except only contact lenses and blister packs are accepted. Similar to the Biotrue Eye Care Recycling program, the One by One Recycling program allows for patients to recycle any brand’s packaging, so the program isn’t limited to Bausch + Lomb’s products.

Although patients will need to create a TerraCycle account to recycle with the Biotrue Eye Care Recycling program, they won’t need to use it to recycle products with the One by One Recycling program. Instead, patients can visit the TerraCycle website, search for the One by One Recycling program and then plug in their location to find the nearest public TerraCycle facility. Here’s where physicians can get involved.

Ophthalmologists can play their part by adding a TerraCycle public drop-off point at their clinic. By doing so, this’ll allow for more accessible recycling options for patients willing to participate in the One by One Recycling program. Simply create

an account with TerraCycle, request to join the One by One Recycling program, await for TerraCycle to review the request and then start recycling. According to their website, the address for the approved public drop-off point will appear on the TerraCycle public map. Once the location is set, patients can discard contact lenses and blister packs at the public drop-off. The last step is to take the recycled products and ship them to a TerraCycle facility, just like the Biotrue Eye Care Recycling program requires users to do.

• **AbbVie.** As a part of their sustainability efforts, AbbVie has created seven environmental targets that they outlined in their 2023 Environmental, Social and Governance Report. The first target is to reduce greenhouse gas emissions by 42 percent by 2030 from the baseline percentage of emissions recorded in 2021. As of 2023, they have reduced 26.4 percent of their emissions. The next target is to actively bring renewable electricity throughout the company to 100 percent by 2030 from 29.5 percent in 2021. In 2023, they increased their renewable electricity usage to 55.5 percent.

Additionally, AbbVie hopes to work with environmentally friendly suppliers for their products. One target that they aim to achieve is to increase the percentage of suppliers who produce emissions that are regulated by the Science Based Targets initiative, a corporate climate action organization who works with global companies and institutions to assist them in combating climate issues. AbbVie is working towards

Struggling to hire qualified ophthalmic technicians?


If you're frustrated by the hiring game, partner with Eyes On Eyecare® to find qualified candidates for your practice. For more than 10 years, Eyes On Eyecare has helped busy practice owners take the headaches out of hiring with specialized job posting and recruiting services.

SOURCE TALENT MORE EFFICIENTLY WITH OUR:

- ✓ Engaged audience of ophthalmic technicians - including active and passive job seekers
- ✓ Syndication to major job platforms and cross-promotion to our affiliate network
- ✓ Dedicated recruiting team with years of eyecare experience sourcing talent for specialized positions

"I had such a wonderful experience using Eyes On Eyecare. It was so easy to post a job and they walk you through the entire process. I recommend them to everyone I know."

- Ashley Wojcik



PROUD PARTNER OF JOBS ON OPTICAL GROUP

Learn more at eyesoneyecare.com/hire-now

increasing climate-friendly supplier relationships to 79.1 percent by 2027. In 2023, AbbVie suppliers associated with the Science Based Targets initiative increased to 41.6 percent.

In 2025, AbbVie hopes to reduce their absolute water withdrawal and absolute total hazardous and non-hazardous waste generated during manufacturing by 20 percent compared to waste accumulated in 2015. They more than achieved their target of reducing hazardous and non-hazardous waste by achieving a 29 percent waste reduction in 2023. Furthermore, they are currently closing in on their goal for reducing water waste. In 2023, they reduced their absolute water withdrawal by 17 percent.

To continue their efforts into 2025, AbbVie is focusing on achieving and maintaining a combined recycling rate of 50 percent for hazardous and non-hazardous materials. As of 2023, they've increased their efforts by 40 percent. The final target in AbbVie's plan is to achieve complete zero waste to landfill by 2035. This excludes leased office buildings. In 2023, they were able to achieve a 92-percent increase in their efforts towards their goal.

• **Glaukos.** "Glaukos has a strong internal team that's very focused on sustainability through their products and packaging," says Dr. Hovanesian. Currently, Glaukos is working towards establishing standard design guidelines for their latest facilities in order to evaluate energy efficiency and other environmental impacts. Along with this environmental effort, they're also working towards maintaining ISO 14001 Certification, a voluntary standard on environmental management that organizations can certify to, for two of their business and manufacturing facilities.

In 2023, Glaukos established two new product distribution centers in which they were able to reduce costs and shipping travel. They were able to eliminate approximately 6.4 million miles of air travel, which led to an estimated 1,286-ton reduction in carbon emissions.

In a company statement, Glaukos mentioned that they're engineering

biodegradable packaging solutions for preexisting products and are hoping to reduce waste even further by converting from paper IFUs to electronic IFUs.

• **Johnson & Johnson.** "Johnson & Johnson has reduced packaging around many of their commonly used surgical products," says Dr. Hovanesian. Since Johnson & Johnson manufactures products for various medical specialties, their sustainable packaging efforts were focused on recyclable packaging for suture kits and self-injectable devices last year. However, according to their 2023 Health and Humanity Report, they've continued to transition to electronic IFUs for eligible J&J MedTech products.

To further product sustainability, J&J MedTech implemented a hospital recycling program for single-use medical devices. This program allows for physicians to recycle specific metal and plastic components from certain J&J MedTech instruments. For physicians who sign up for the program, Johnson & Johnson sends them the appropriate bin or collection option for the instruments being recycled. Additionally, they'll work with hospital staff to ensure that they're trained on how to properly recycle, handle and transport J&J MedTech instruments. According to the company, this program has diverted approximately 281,000 lbs. of waste from landfills and reduced CO₂ emissions by 171,000 lbs.

• **Zeiss.** In 2015, the United Nations Climate Change Conference established the Paris Agreement, a set of long-term goals to guide nations to adapt to the impacts of climate change. Now, Zeiss is attempting to achieve similar goals towards environmental sustainability by trying to be carbon neutral by 2025. They've created their own step-by-step process on how they intend to achieve the targets set by the Agreement.

According to the UN, the Paris Agreement set three goals: (1) Reduce global greenhouse gas emissions in order to hold the global temperature below 2°C in an attempt to reach a limited baseline temperature of 1.5°C; (2) Reassess the Agreement to ensure all goals are being met; and (3) Provide financial

support to struggling and developing nations to assist in climate change.

Zeiss plans to implement more renewable energy resources, use natural resources in their products, maintain clean supply chains, offset their emissions and more all in an attempt to meet the Agreement's standards. Since they hope to be carbon neutral by 2025, they have put in relative effort to reduce CO₂ emissions. They've noted online that they've successfully reduced 72 percent of CO₂ emissions compared to the 2018/2019 fiscal year.

• **Sight Sciences.** This year, Sight Sciences released their first Sustainability Report. Their report covered sustainability efforts from 2021 to 2023. In the report, they covered how they've transitioned to electronic IFUs for permitted medical products. Since beginning this initiative, they've saved approximately 2,000 lbs. of paper waste. Furthermore, they continued to reduce their environmental impact by consolidating shipments. Rather than shipping products weekly using air travel, they added monthly and bimonthly sea freight shipments. Due to the scope of their business, Sight Sciences noted in their report that they believe their overall environmental impact was small.

Sustainability in Practices

Pharmaceutical companies aren't the only eye-care entities making an environmentally sustainable impact. Physicians are playing their part as well.

"For surgeons who wish to reduce their environmental impact in their surgical practice, they can go to the EyeSustain website and take the EyeSustain pledge," says Dr. Hovanesian. EyeSustain is sponsored by ASCRS, ESCRS and the AAO. Dr. Hovanesian explains that the EyeSustain pledge is a great step-by-step guide to help begin a sustainability initiative for hospitals and institutions.

"One of the examples [from the pledge] is to take a look at what's in our surgical packs and evaluate whether all the products that are available are really used for the vast majority of surgeries

(Continued on pg. 59)

NEW APPROACHES TO THE CATARACT DRUG PROTOCOL

Proponents say these protocols are less expensive and improve patient compliance.

MICHELLE STEPHENSON
CONTRIBUTING EDITOR

Medication non-compliance is one of the biggest obstacles to a successful cataract surgery outcome. Additionally, the required drops are pricey for patients. For these reasons, some surgeons are turning to dropless and less-drops protocols after cataract surgery. Here, physicians who have adopted these strategies detail how they make them work in their practices.

The Rationale

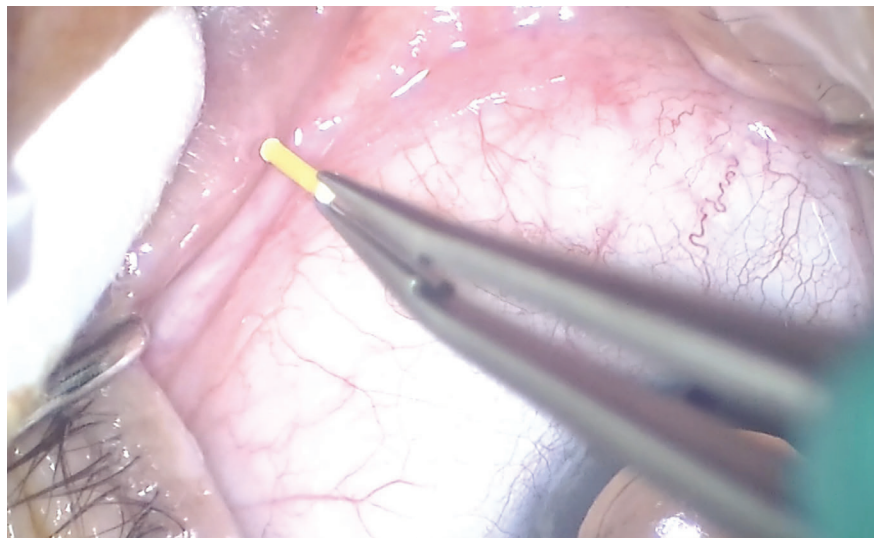
According to Neal Shorstein, MD, who is in practice in Oakland, California, patient compliance is a significant problem. Even patients who remember to instill the drops at the correct times can have poor technique, which can affect surgical outcomes.

A Canadian study found that postoperative cataract patients inexperienced with eye-drop use showed a poor instillation technique by failing to wash their hands, contaminating bottle tips, missing the eye, and using an incorrect amount of drops.¹

Additionally, a large discrepancy was noted between the patients' perceptions and the observed technique of drop administration.

The study included 54 eye-drop-naïve postoperative cataract patients. Subjectively, 31 percent of patients reported difficulty instilling the drops, 69 percent reported always washing their hands before using the drops, 42 percent believed that they never

missed their eye when instilling drops, and 58.3 percent believed they never touched their eye with the bottle tip. Objectively, 50 patients (92.6 percent) showed an improper administration technique, including missing the eye (31.5 percent), instilling an incorrect amount of drops (64 percent), contaminating the bottle tip (57.4 percent) or failing to wash hands before drop instillation (78 percent).



John Hovanesian, MD

Dextenza is placed much like a dissolving punctal plug in the lower lid canaliculus, where it provides about four weeks of a tapering dose of dexamethasone to the eye after surgery.

This article has no commercial sponsorship.

Dr. Hovanesian is a consultant to Ocular Therapeutix and Imprimis Rx. Drs. Ferguson and Shorstein have no financial interests to disclose.

Droplless Techniques

Droplless techniques involve administering medication via injection at the time of surgery and don't require patients to administer drops at home. Dr. Shorstein and his colleagues at Kaiser Permanente use a subconjunctival injection of triamcinolone, 4 mg of the 10 mg/mL product. "We just published a study showing that subconjunctival triamcinolone is better at preventing macular edema and iritis than a combination therapy of topical prednisolone with an NSAID. So, the pros are obvious," he says.

This retrospective, comparative effectiveness cohort study included 69,832 eligible patient eyes.² All eyes received topical prednisolone acetate with or without NSAID and subconjunctival injection of triamcinolone acetonide 10 mg/mL or 40 mg/mL in a low dose (1 to 3 mg) or high dose (3.1 to 5 mg).

Postoperative macular edema occurred in 1.3 percent of eyes in the topical group and in 0.8 percent of eyes in the injection group. Iritis occurred in 0.8 percent of eyes in the topical group and in 0.5 percent of eyes in the injection group, and a glaucoma-related event (e.g., increased intraocular pressure) occurred in 3.4 percent of eyes in the topical group and in 2.8 percent of the eyes in the injection group.

In multivariable analysis, compared

with the prednisolone acetate reference group, the prednisolone acetate plus NSAID group had a lower odds ratio of macular edema. All injection groups had even lower odds, with the high-dose (4 mg) triamcinolone acetonide 10 mg/mL group reaching statistical significance.

A trend of lower odds of a postoperative iritis diagnosis was noted in the high-strength (40 mg/mL) groups. For postoperative glaucoma-related events, compared with prednisolone acetate, the triamcinolone acetonide 10 mg/mL low-dose group (2 mg) showed lower odds, the triamcinolone acetonide 10 mg/mL high-dose group showed similar odds, and the triamcinolone acetonide 40 mg/mL low-dose and high-dose groups showed higher odds of an event occurring. In his experience, with 4 mg triamcinolone of the 10 mg/mL product, an additional NSAID isn't necessary.

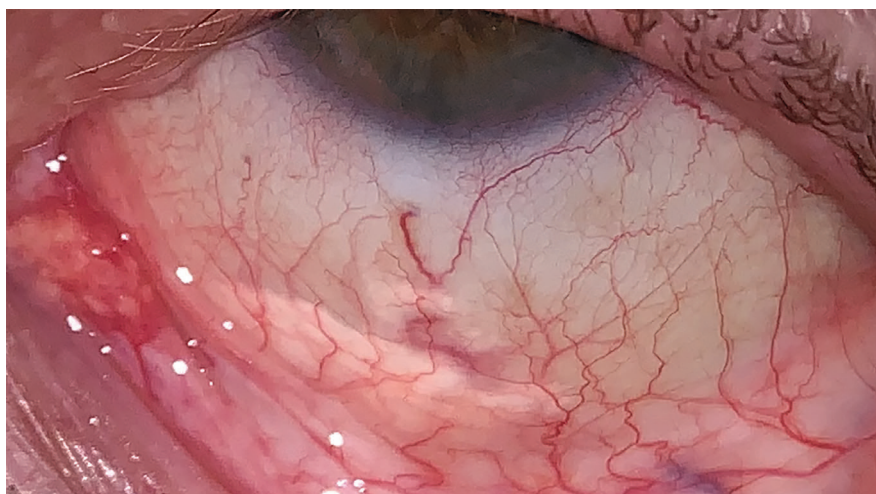"For patients who have advanced glaucoma and are at risk for a corticosteroid IOP response, the downside is that you're placing a long-acting depot of a corticosteroid under the conjunctiva, which could increase the risk of a postop IOP spike," Dr. Shorstein says. "In the entire study, there was actually less risk of an IOP response with the triamcinolone injection using the dose and concentration that I just mentioned than with topical prednisolone and NSAID. With that said, there was

increased risk of a glaucoma-related event for patients with glaucoma and ocular hypertension so one should be careful in these patients and in those who have a history of high myopia and are relatively young."

Another technique in the droplless category is an intravitreal injection of triamcinolone and moxifloxacin. "My worry with this technique is injecting into a compartment, namely the vitreous, that we generally try to avoid during cataract surgery. Additionally, few studies have clearly shown what the pharmacokinetics are of an antibiotic and a corticosteroid injection in the vitreous cavity for routine cataract surgery. In contrast, there have been at least 10 peer-reviewed studies that have looked at the subconjunctival location of injection of triamcinolone following cataract surgery going back to 1966. That's how we got started on this technique," Dr. Shorstein adds.

He reports that patients are extremely happy about not having to instill drops. "Many of our elderly, cataract population are fearful about the postop care, primarily of putting drops in. When they find out that they're using a drop-free technique, they're extremely happy, and they feel reassured that they're getting the medicine in. It's injected by the surgeon, and it's not reliant on the patient at all. They're very happy about that," Dr. Shorstein says.

John Hovanesian, MD, who is in practice in Laguna Hills, California, also prefers droplless cataract surgery. His regimen consists of Dextenza (dexamethasone ophthalmic insert 0.4 mg, Ocular Therapeutix) and intracameral moxifloxacin at the end of the surgery, which is combined by a compounding pharmacy. "We also have the patient take topical bromfenac once a day for about a month after surgery. That's our postop regimen for routine cataract surgery. For patients who are diabetic, have epiretinal membranes, or are otherwise at higher risk for postoperative macular edema, we'll sometimes give bromfenac for up to eight weeks. We sometimes will also



Neal Shorstein, MD

Drug depot one week after injection of 4 mg triamcinolone acetonide (Kenalog) 10 mg/mL, 6 to 8 mm inferior to the limbus.

Post-Op

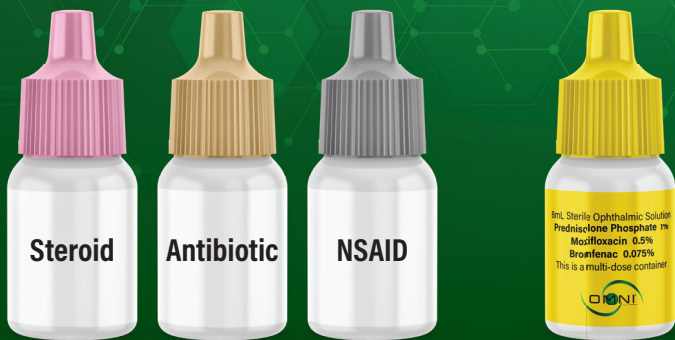
Compounded Ophthalmic Medications



Made Easy

“OSRX is as easy as it gets for the patient and the practice. It’s quality, reliable and simple. A win for everyone.”

— Robert Weinstock, MD
The Eye Institute of West Florida



3 Medications> 1 bottle

Are You Ready to
Simplify?

- ✓ Simplified Dosing
- ✓ Affordable Pricing
- ✓ Unrivaled Customer Care
- ✓ Shipping to Practice or Patient Homes Included

Get Started at
bit.ly/osrxstart



Post-op medications carry serious risks, including burning and stinging upon instillation, allergic conjunctivitis and bitter taste in mouth. View potential adverse events and contraindications at: www.osrxpharmaceuticals.com/osrx-api-aecontraindication *For professional use only. OSRX specializes in customizing compounded medications to meet unique patient and practitioner needs. Compounded drugs are not FDA-approved, which means they have not undergone FDA premarket review for safety, effectiveness, and quality. Professional Disclosure: Dr. Weinstock is on the Medical Advisory Board for Ocular Science® (an affiliate of OSRX) and has a financial interest in the company.

give triamcinolone injections subconjunctivally for higher risk diabetics,” he says.

Dr. Hovanesian recently conducted a study to evaluate the clinical efficacy and patient preference for a dropless treatment regimen compared to conventional topical therapy in cataract patients.³

In this prospective, contralateral eye study, patients with bilateral cataract were randomized to receive either intracanalicular dexamethasone insert, intracameral phenylephrine 1%/ketorolac 0.3%, and intracameral moxifloxacin (50 µg) (study group) or topical moxifloxacin 0.5%, ketorolac 0.5%, and prednisolone acetate 1.0% four times daily (control group). The second eye underwent cataract surgery two weeks later and received the opposite treatment. All patients were evaluated at days one, seven, 14, 28, and three months.

The proportion of patients with no pain was similar in both groups at all postoperative visits. No statistically significant difference in summed ocular inflammation score was observed between the two groups at any visit. The vast majority of patients (94.7 percent) preferred the study eye’s dropless regimen over the control eye’s conventional topical regimen.

The researchers concluded that a dropless treatment regimen is as effective as topical administration. A higher proportion of patients who underwent bilateral cataract surgery preferred the dropless treatment regimen over the patient-administered drop regimen.

According to Dr. Hovanesian, another advantage is cost. “The cost for patients taking a three-drop cocktail was \$100 more than the eye that received the single medication, bromfenac. We didn’t measure compliance, but it’s likely that compliance was also superior in the group taking just one drop.”

Dextenza is covered by Medicare, so it’s free to the patient and the surgeon, he says.

However, there are a few downsides. “With glaucoma patients, you must

be careful because you’re putting the steroid in at the time of surgery. You must be confident that that patient isn’t likely to have a pressure spike. Fortunately, that’s a rare event, and it’s not difficult to remove Dextenza from the lacrimal canaliculus in the event of a steroid response,” Dr. Hovanesian explains.

He adds that it is a very patient-friendly way to approach surgery. “And, perhaps more importantly, the surgeon is taking control,” he says. “When we give drops, we have no control over whether patients actually pick them up at the pharmacy, and a lot of patients don’t if they’re expensive. And will they take them? Here, you’re giving the medication, and so there’s very little you’re relying on the patient for. Additionally, drugs like Dextenza and Omidria (phenylephrine and ketorolac intraocular solution) end up saving the ocular surface from the burden of topical preservatives, because these medications contain none.”

Less-Drops

Lance Ferguson, MD, in practice in Lexington, Kentucky, prefers less-drops surgery over dropless surgery. “I’m reluctant to use intracameral medicines in cataract surgery,” he explains. “Once they’re on board, there is no way to stop the medicine, as one could with standard drops. If the patient is an unknown steroid responder, then the surgeon must aggressively prescribe ocular hypotensives, be they systemic meds (acetazolamide) or glaucoma drops, as we can’t predict who will respond a priori. Indeed, those with active chronic open-angle glaucoma should probably avoid the dropless approach altogether, especially if they are already on maximal tolerated ocular hypotensive medicines.”

He adds that some patients will require additional anti-inflammatories, and the patient may be disappointed if he or she was expecting a dropless experience. “In this case, the patient won’t be a happy camper. The general approach in patient care is to underpromise and overdeliver, whereas the

dropless approach has the distinct possibility of overpromising and underdelivering—with an unexpected hit to the wallet,” he adds.

Dr. Ferguson uses a compounding pharmacy for his less-drops approach. “Compounding allows for simplicity in the postoperative medical regimen, and simplicity equals better compliance,” he says. “Additionally, compounding markedly reduces the costs of postoperative drops, especially if one is insistent upon a name brand. Even if generics are prescribed, the savings still amount to several hundred dollars. We use a de minimis mark-up of the cost of our compounded drops to cover labor costs for ordering, stocking and dispensing of these compounded medicines.”

In the rare event that the compounded drops alone are inadequate for suppressing inflammation, he instructs the patient to increase the daily administration of the medicines. “This would indeed require giving additional antibiotic, but the risk of doing so is almost nil,” he says. “If still unsuccessful, then we would, as a second step, prescribe a separate medicine. In this scenario, we explain why we need to supplement the compounded drops. Because the patient is already on drops, it isn’t a big change in the plan and is far less disappointing than for those who expect to take no drops at all.”

He recommends carefully researching the compounding pharmacy that you use. “There are horror stories in which a less-than-competent supplier has supplied a concoction resulting in permanent patient injury,” he adds. ◀

1. An JA, Kasner O, Samek DA, Levesque V. Evaluation of eyedrop administration by inexperienced patients after cataract surgery. *J Cataract Refract Surg* 2014;40:11:1857-1861.

2. Shorstein NH, McCabe SE, Alavi M, et al. Triamcinolone acetate subconjunctival injection as stand-alone inflammation prophylaxis after phacoemulsification cataract surgery. *Ophthalmology* 2024. [pub ahead of print]

3. Donnenfeld ED, Hovanesian JA, Malik AG, Wong A. A randomized, prospective, observer-masked study comparing dropless treatment regimen using intracanalicular dexamethasone insert, intracameral ketorolac, and intracameral moxifloxacin versus conventional topical therapy to control postoperative pain and inflammation in cataract surgery. *Clin Ophthalmol* 2023;17:2349-2356.



EDITED BY KULDEV SINGH, MD, MPH,
AND PETER A. NETLAND, MD, PHD

GLAUCOMA MANAGEMENT

Exploring Anesthesia Options

The safest approaches for tubes, trabs and MIGS, and how verbal anesthesia can help.

REZA RAZEGHINEJAD, MD
PHILADELPHIA

Glaucoma surgery requires careful consideration of anesthesia options to ensure patient comfort and safety. Over the last decade, our approach to anesthesia has changed in terms of the agents and approaches used. Previously, most cases were performed under general anesthesia, but today it's far more common for patients to undergo surgery with a combination of topical and injected anesthesia. In this article, I'll discuss the anesthesia techniques for trabeculectomy, tube shunts and minimally invasive glaucoma surgeries, and how verbal anesthesia can increase patient cooperation and comfort.

Options

The most common techniques we use these days are topical, sub-Tenon peribulbar and subconjunctival injections. These anterior approaches provide adequate analgesia with reduced risk of sight-threatening complications. Surgeons must carefully evaluate patient tolerance, surgical requirements and the need for additional sedation with these approaches.

Retrolbulbar anesthesia isn't as commonly used as it once was, but we prefer to avoid the use of retrolbulbar injection. While this posterior approach provides

excellent akinesia and anesthesia, it carries a higher risk of sight-threatening complications, including globe perforation, especially in myopic patients who have larger eyes; optic nerve injury; brainstem anesthesia; and retrolbulbar hemorrhage. The chance of retrolbulbar hemorrhage seems to be higher in patients on any blood thinners, even a prophylactic dose of aspirin.

Anesthetic Agents

Anesthetic agents play a crucial role in patient comfort during surgery. Local anesthetics such as lidocaine, carbocaine, bupivacaine and ropivacaine are commonly used to achieve effective anesthesia. These may be administered alone, combined with each other, or with other agents such as epinephrine to increase duration of action and improve anesthesia.

Trabs and Tubes

Subconjunctival and sub-Tenon

injections are both suitable options for trabeculectomies and tube shunts. In trabeculectomy, it's common to combine lidocaine with mitomycin and inject into the superior subconjunctival space. This provides enough anesthesia to complete the trabeculectomy.

All patients undergoing cataract or glaucoma surgery today also receive topical anesthetic agents, such as proparacaine or tetracaine and lidocaine gel. The gel provides anesthesia to the conjunctiva and the eyelid and helps during the initiation of surgery.

For the Xen procedure, we also use a combination of lidocaine and mitomycin. Some physicians consider using lidocaine plus epinephrine, which causes vasoconstriction, to decrease the chance for any subconjunctival hemorrhage during Xen implantation. This anesthetic agent combination is also used during trabeculectomy or tube revision to decrease the chance of bleeding.

Sub-Tenon injections are widely used during tube shunt surgery. After making a small peritomy, a combination of lidocaine 2% plus bupivacaine 0.75% is instilled under Tenon's. Many surgeons will add additional anesthetic after dissecting Tenon's posteriorly, using a large blunt cannula to administer anesthesia in the retrolbulbar and intraconal space before placing the shunt.

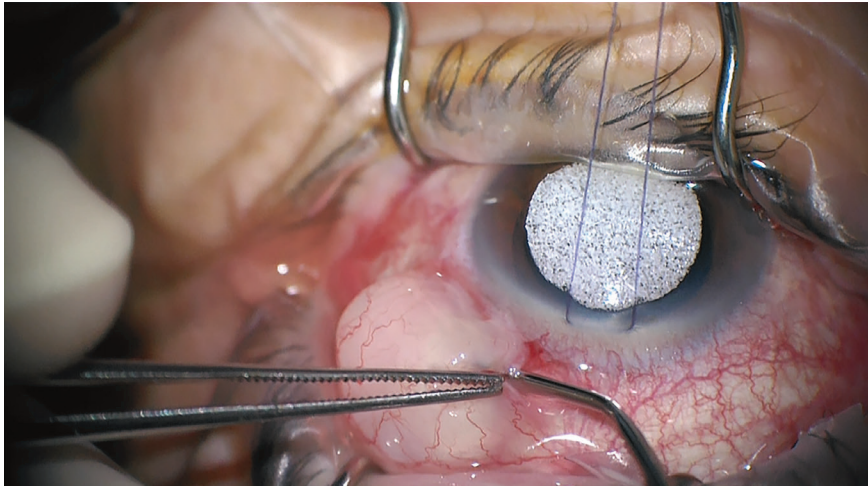
For any sub-Tenon injection, it's safer to use a cannula rather than a

TABLE 1. THE ONSET AND DURATION OF EFFECTS OF THE ANESTHETIC AGENTS

Medication	Onset (mins)	Duration (hrs)
Lidocaine (Xylocaine)	1	1-1.5
Lidocaine + epinephrine	1	2-3
Mepivacaine (Carbocaine)	3-5	1-2
Bupivacaine (Marcaine)	5	2-4
Bupivacaine (Marcaine) + epinephrine	5	3-6.5

This article has no commercial sponsorship.

Dr. Singh is a professor of ophthalmology and chief of the Glaucoma Division at Stanford University School of Medicine. He is a consultant to Alcon, Allergan, Santen, Sight Sciences, Glaukos and Ivantis. Dr. Netland is Vernah Scott Moyston Professor and Chair at the University of Virginia in Charlottesville.



The injection of anesthetic agent is performed using a cannula after making a small opening on the conjunctiva at the limbus.

needle after making a small peritomy. This decreases the chance for potential complications such as perforating vessels causing subconjunctival hemorrhage or globe penetration. The peritomy could be at the site of the tube implantation or inferonasally 4 to 5 mm posterior to the limbus.

MIGS

MIGS procedures, due to their less invasive nature, often lend themselves to topical or intracameral anesthesia, though certain cases may warrant sub-Tenon injections or other approaches, depending on patient and surgical factors.

During the MIGS procedure we need patient cooperation to look away from the surgeon to get a good view to the angle, therefore no akinesia anesthesia is the preferred method. In MIGS patients, we generally use a topical agent, such as proparacaine, tetracaine or lidocaine gel, and inject preservative-free lidocaine 1% in the anterior chamber.

Any intracameral anesthetic agents must be preservative-free to avoid complications such as toxic anterior segment syndrome or corneal endothelial toxicity.

Assessing Risks and Benefits

When selecting anesthesia techniques for glaucoma surgery, surgeons must carefully evaluate the potential risks associated with each option. A tailored approach may be needed in patients with significant comorbidities or anxiety, or in the event of complications.

During a phaco-MIGS procedure, for example, if the posterior capsule opens and the surgery requires more time to finish, sub-Tenon anesthesia may be needed to provide more comfort for the patient.

For patients undergoing cyclophotocoagulation, which is often painful even after the surgery, injecting subconjunctival bupivacaine is helpful. This gives the patient at least several hours of comfort after the procedure. Similarly, for tube shunts, because we perform

more dissection and do device implantation, I also use bupivacaine combined with lidocaine or carbocaine to provide more patient comfort for a few hours postoperatively.

Verbal Anesthesia

In addition to pharmacological anesthesia techniques, verbal anesthesia plays a key role in enhancing patient comfort and reducing anxiety during surgery. Effective communication with the patient and surgical team in the operating room can help clarify expectations and build trust.

Talking with patients before surgery in the preoperative area to give them an idea of what’s going to happen in the operating room will prepare them for the surgery and decreases their anxiety. During the procedure, offer encouragement. Telling patients things like “You’re moving” or “You’re not looking straight,” may elicit a negative response from the patient and induce more anxiety and stress, leading to a vicious cycle. Even in patients who aren’t cooperating, I find that encouragement helps them do better during the surgery. I usually tell patients, “You’re doing great. Everything looks good. We just need you to look at this light” or “You’re amazing. You’re one of my best patients.” Encouraging phrases like these help patients cooperate and feel less stress.

In summary, anesthesia management in glaucoma surgery requires weighing the advantages and disadvantages of certain techniques against patient-specific factors and surgical considerations. Understanding the nuances of each anesthesia option and using encouragement in the operating room can optimize outcomes and enhance the overall experience for patients undergoing glaucoma procedures. ◀

TABLE 2. THE SELECTION OF ANESTHESIA BASED ON THE TYPE OF GLAUCOMA SURGERY

	Topical	Intracameral	Subconjunctival	Sub-Tenon	Retrolubar
MIGS	+	+			
Xen	+		+		
Trabeculectomy	+		+		
Tube	+		+	+	
CPC	+		+	+/-	{+/-}

ABOUT THE AUTHOR



Dr. Razeghinejad is a glaucoma specialist and director of the Glaucoma Fellowship Program at Wills Eye Hospital in Philadelphia. His institution has received research grants from Olleyes and Equinox.

(Continued from pg. 52)

or whether they're rare items that don't get used very often that get opened and thrown away," mentions Dr. Hovanesian. "Another example is the size of the surgical drape. There are facilities and there are centers where it's just a matter of their practice to fully drape the patient from head-to-toe for surgery. That's not necessary for cataract surgery. It's been shown in many cases that you can use a very small, short drape that adequately covers the area needed for sterility without compromising anything further. And you're throwing a lot less material out when you do that.

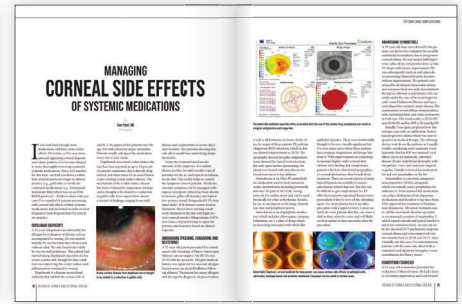

"Another step is to evaluate reusable instruments as opposed to disposable instruments," continues Dr. Hovanesian. "There are elements of our surgical pack that sometimes can be reused, like diamond blades instead of metal blades that are disposable with every case. Diamatrix makes reusable blades that are metal that can be used for a number of cases. Every time we reuse and sterilize, we reduce our [environmental] impact."

Patients may want to put in their own effort towards sustainable eye care. Physicians can encourage their patients to recycle products, especially through the TerraCycle program, and assist them on reducing waste. For instance, patients can purchase a NanoDropper to reduce wasting eye drop solution.

"The NanoDropper is an adapter that goes on top of the patient's eye drop bottle," explains Dr. Schehlein. "What it does is it reduces the eye-drop volume dispensed each time by about 62 percent.⁵ So, this will allow the bottle life to be increased by almost three times. The company hopes that this will help to reduce the carbon footprint associated with prescription medications. But also, when you look at the material that the NanoDropper adapter is made with, it's made with #2 HDPE plastics, which can be recycled normally with other clean plastics."

While the NanoDropper and TerraCycle program are ways in which patients can get involved with eye-care sustainability, they should try to focus their attention on their ocular disease and treatment regimen. "We as physicians have the responsibility to care for the whole patient," says Dr. Schehlein. "They should focus on getting better. Individual sustainability and waste reduction is important for sure, but I think that physicians and medicine as a whole have more of an impact on climate change. It's our responsibility to care for the patient in this space versus them contributing." ◀

1. How the U.S. health care system contributes to climate change. The Commonwealth Fund. <https://www.commonwealthfund.org/publications/explainer/2022/apr/how-us-health-care-system-contributes-climate-change>. Accessed June 11, 2024.
 2. Taboun OS, Orr S, Pereira A, et al. Factors contributing to the carbon footprint of cataract surgery. *JCRS* 2023;49:7:759-763.
 3. Kwakye G, Brat GA, Makary MA. Green surgical practices for health care. *Archives of Surgery* 2011;146:2:131-136.
 4. Schehlein EM, Hovanesian J, Shukla AG, et al. Reducing ophthalmic surgical waste through electronic instructions for use: A multisociety position paper. *JCRS* 2024;50:3:197-200.
 5. St. Peter DM, Steger JS, Patnaik JL, et al. Reduction of eyedrop volume for topical ophthalmic medications with the NanoDropper bottle adaptor. *Med Devices (Aukl)* 2023;16:71-79.



3rd ANNUAL REVIEW[®] of CORNEA & EXTERNAL DISEASE

TOPICS:

- WHEN AND HOW TO PURSUE DEEP ANTERIOR LAMELLAR KERATOPLASTY (DALK)
- DRY EYE/OCULAR SURFACE AND REFRACTIVE SURGERY: A PRIMER ON CORNEAL SURFACE ABLATION
- CUTTING-EDGE APPROACHES FOR MANAGING CORNEAL KERATOPATHY
- WHAT'S NEW IN ARTIFICIAL CORNEAS



**POLYBAGGED
WITH ISSUE**



**21,252*
CIRCULATION**



**WEBSITE
ARCHIVE**

*Source: BPA circ. statements for the 6-month period ending January 2024

For advertising opportunities,
contact your *Review* representative today



EDITED BY CARL REGILLO, MD,
AND YOSHIHIRO YONEKAWA, MD

RETINAL INSIDER

Best Practices for Treating CSCCR

Tips for diagnosing and managing this common, yet challenging, condition.

**YU JEAT CHONG, MD, NOA GILEAD, MD, AND
GEMMY CHEUNG, MD**
SINGAPORE

Though central serous chorioretinopathy is common, it can still be challenging to diagnose and treat, since it can present with a wide range of symptoms, such as blurred vision, a central scotoma and metamorphopsia (visual distortion); as well as with symptoms that are similar to other conditions, such as age-related macular degeneration and diabetic retinopathy. However, it's crucial that we catch and treat CSCCR, since it often strikes patients in the prime of their lives.

Here, we'll share the diagnostic cues to watch out for and the treatment approaches that often yield the best outcomes.

Classification of CSCCR

Central serous chorioretinopathy is characterized by detachment of the neurosensory retina, secondary to the presence of serous subretinal fluid (SRF).¹ Other features of this disease include pigment epithelial detachments (PED) and retinal pigment epithelial changes. It affects men up to five times more than women and is widely regarded as the fourth most common retinal disease after age-related macular degeneration, diabetic

maculopathy and vein occlusion.^{2,3} Patients suffering from CSCCR experience distortion of central vision, scotomas, micropsia and metamorphopsia.¹ While "central" refers to visual symptoms due to serous detachments in the macula, CSCCR can also present with extra-macular involvements that might be asymptomatic.⁴ It can have a significant impact on quality of life, as it typically affects patients of working age, between 30 and 50 years.³

Despite advancements in medical science, our understanding of CSCCR remains incomplete. Its underlying mechanisms involve venous overload and permeability, scleral rigidity and RPE health.^{3,5} Additionally, both glucocorticoids and mineralocorticoids have been implicated in its pathogenesis. Increasing evidence also suggests CSCCR is part of the broader pachychoroid disease spectrum (PDS), further highlighting the condition's complexity.⁶

While there's a lack of standardization among retina specialists over the classification of CSCCR, the CSCCR International Group proposed to classify CSCCR into simple, complex and atypical forms based on multimodal imaging findings.⁷ The group established a threshold based on a 2-disc area of RPE atrophy to distinguish between simple and complex CSCCR: <2 DA is simple; > 2 DA is complex.

Each group was then further categorized into: primary (representing the initial episode of SRF); recurrent (indicating the presence of SRF with history or signs of previous episodes); and resolved. SRF persisting for more than six months was classified as persistent. Both groups could be complicated by the presence of choroidal neovascularisation. Additionally, the atypical category encompasses variants such as bullous CSCCR, RPE tears or CSCCR occurring in conjunction with other retinal diseases.

Although this is a consensus-based classification, it still needs further refinement from the global ophthalmology community, given that the inter-rater agreement still ranges between fair and moderate.⁸

Other Classifications

Clinicians might be more familiar with the common classification of acute or chronic CSCCR, based on the duration of the subretinal detachments: Eyes with duration of less than three to six months are classified as acute, while eyes with duration of more than three to six months are classified as chronic.^{3,7} In clinical practice, variations in the presentation and progression of disease often result in poor agreement among retina specialists.⁷ There might also be recall bias or unreliability in the reporting of symptoms by patients. For the purpose of this article, we will use the term acute and chronic as a signifier of duration, but not for the purpose of classification.

Diagnosis of CSCCR

A detailed medical history is important for determining the nature of symptoms, timeline of disease, and identification of risk factors such as

This article has no commercial sponsorship.

Dr. Regillo is the director of the Retina Service of Wills Eye Hospital, a professor of ophthalmology at Thomas Jefferson University School of Medicine and the principle investigator for numerous major international clinical trials.

Dr. Yonekawa is an assistant professor of ophthalmology at Sidney Kimmel Medical College at Thomas Jefferson University. He serves on the Education Committee of the American Society of Retina Specialists and on the Executive Committee for the Vit Buckle Society, where he is also the vice president for academic programming.

steroid use and other comorbidities like Cushing's disease. Questions should include whether this is a first known episode or a recurrent one, as well as the duration of each episode.

A thorough and structured slit-lamp examination would help with the differential diagnosis of other diseases that may also present with similar symptoms and subretinal fluid, such as neovascular diseases, inflammatory diseases like Vogt-Koyanagi Harada syndrome (VKH), optic disc pits and retinal detachments.⁹ Typical funduscopy findings in CSCR include serous neurosensory

detachment (generally round or oval), with yellow subretinal deposits within the vicinity of the detachment. Additional indicators are RPE pigmentary changes and atrophy.

Following this, the use of multimodal imaging such as optical coherence tomography, fluorescein angiography, indocyanine green angiography and fundus autofluorescence will play a further role in specifying the classification into simple, complex or atypical CSCR.

OCT Findings

OCT is recommended as the primary imaging tool for diagnosing CSCR. It's useful at detecting various pathologies, including SRF, subretinal fibrin and abnormalities of the RPE such as irregularity, atrophy and detachments.^{3,10} Furthermore, it's invaluable for assessing the extent and location of SRF, facilitating comparisons over time. Enhanced-depth OCT can demonstrate choroidal features indicative of pachychoroid such as enlarged vessels in the Haller's layer, along with thinned choriocapillaris and Sattler's layer.¹¹

In acute CSCR, serous retinal detachments are typically confined to the macula and exhibit fewer RPE

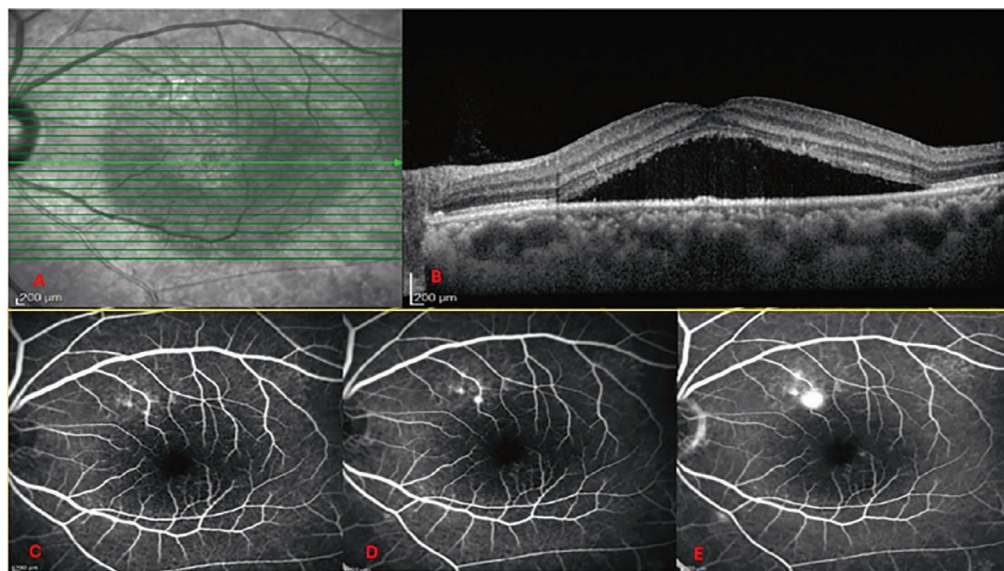


Figure 1. (A) En face infrared image on OCT scan. (B) Simple CSCR with subretinal fluid and minimal RPE changes. (C, D, E) Early, mid, and late phase of FA, demonstrating an ink blot type lesion which is the source of leakage through the RPE into the subretinal space.

abnormalities. In contrast, chronicity of CSCR can lead to various findings, including elongated photoreceptor outer segments (POS), subretinal fibrin, intraretinal lipid deposits, subretinal yellowish dots, thinning of the outer nuclear layer and widespread RPE changes.^{3,11-14} Intraretinal fluid can also develop when defects in the external limiting membrane allow fluid to enter the retina.^{15,16}

Chronic neurosensory retinal detachments are generally shallow and broad, with attenuation of the outer retinal layers. Notably, the presence of a morphological feature known as the “Fuji Sign,” characterized by a more peaked appearance of SRF, has been shown to predict a higher likelihood of spontaneous SRF resolution.¹⁷

When evaluating OCT images, examining the status of the photoreceptors is crucial for prognostication.¹³ Disruption of the external limiting membrane (ELM) and/or the ellipsoid zone (EZ) band have been associated with poor central vision, even after the resolution of SRF. Elongation of the POS at baseline is also associated with poorer long term visual acuity outcomes.¹⁸

The presence of a PED warrants careful observations of RPE defect

within the PED, which can correspond precisely to leakage points on FA.¹⁹ RPE changes, such as an RPE bulge have also been noted to occur within areas of choroidal hypermeability.²⁰

Fluorescein Findings

On FA, the classic presentation is between one to three focal leakage points, corresponding to areas of RPE defects. It can present with the characteristic “inkblot” leakage: A focal leak appears during dye transit and becomes more indistinct as the dye leaks more slowly into the subretinal space through the RPE defects (*Figure 1*).¹¹ Another classic pattern on FA is the “smokestack” leakage: a focal hyperfluorescent pinpoint with a spreading area of hyperfluorescence over time.^{4,21} Fluorescein subsequently pools in the area of neurosensory detachment, resulting in an area of diffuse circular hyperfluorescence.⁴

In chronic CSCR, gravitational tracts can be present: areas of hyperfluorescent RPE window defects which correspond to RPE atrophy (*Figure 2*).¹⁰ These window defects can make it difficult to identify the focal leakage points as both are hyperfluorescent.

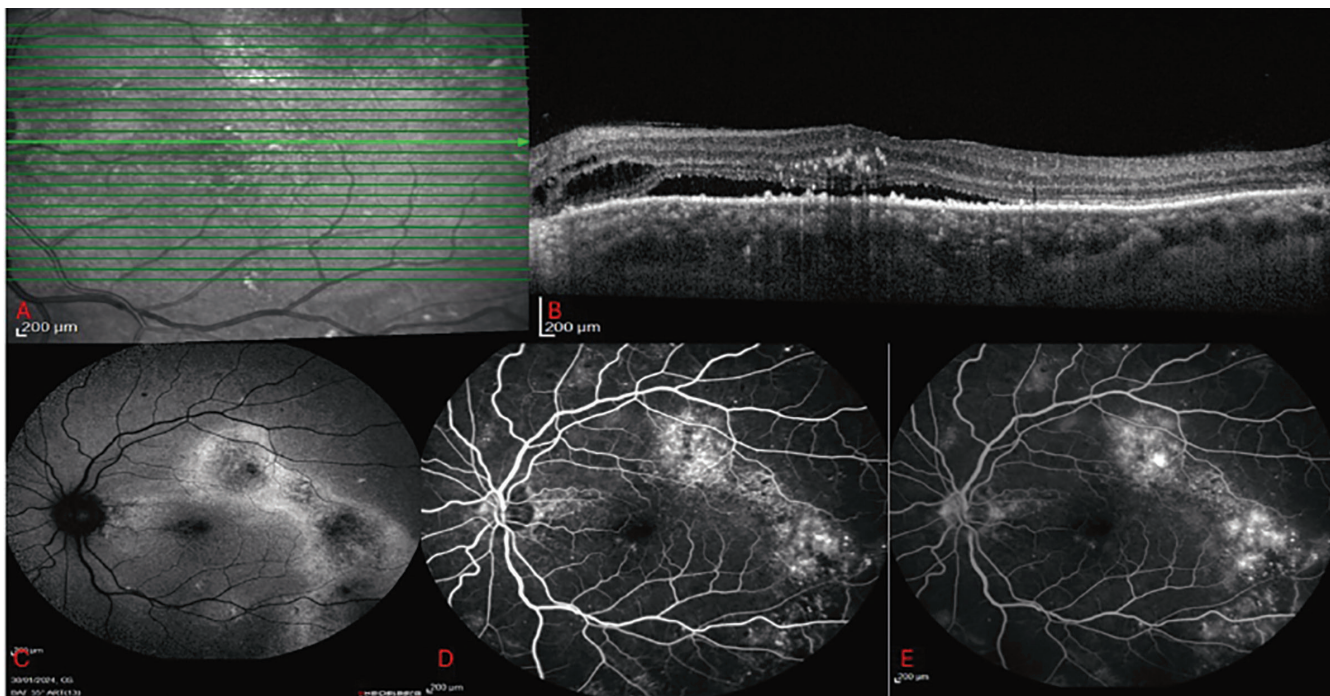


Figure 2. (A) En-face infrared image on OCT scan. (B) Complex CSCR with subretinal fluid, intraretinal lipid, intraretinal fluid and extensive RPE changes. (C) FAF with heterogeneous pattern of hyperautofluorescence and gravitational track changes. (D) Early phase FA with window defect obscuring areas of leakage. (E) Late phase FA demonstrating areas of increased hyperfluorescence corresponding to areas of leakage.

ICGA Findings

On ICGA, signs in the early phase (one to three minutes) include localized delay and uneven filling of the arteries and choriocapillaris.^{22,23} In the mid-phase (three to 15 minutes), there can be areas of indistinct hyperfluorescence which are a sign of choroidal hyperpermeability.²¹ These areas correspond to findings of focal leakage on FA. Areas of hyperfluorescence on ICGA are generally more widespread compared to FA.

FAF Findings

In the stage of disease without significant RPE damage, areas of SRF can initially present with hyperautofluorescence.²⁴ Subsequently, when RPE becomes atrophic, this appears as areas of hypoautofluorescence; initially, the patterns appear granular, before progressing and becoming confluent.^{25,26} However, accumulation of debris from photoreceptor outer segments which persist in the subretinal space can manifest as hyperautofluorescence, which highlights the

contextual importance of multi-modal imaging.²⁰

One of the main advantages of FAF is that it's a convenient and non-invasive imaging tool to visualize RPE and outer retinal changes. In general, eyes with acute CSCR tend to present with homogenous hyperautofluorescence with minimal changes around the area of neurosensory detachment. In contrast, patients with a more chronic presentation can have a more heterogeneous pattern of hyperautofluorescence, with more extensive areas of RPE abnormalities (*Figure 2*).²⁵ This visualization is important for classifying patients into either simple or complex CSCR based on the extent of RPE changes, as well as for the detection of previous areas of extramacular involvement which might have been asymptomatic.

Treatment of CSCR

In the management of CSCR, the primary goal is to achieve the resolution of SRF while maintaining the integrity of the neurosensory retina.

The initial approach involves conducting a thorough patient history and identifying and adjusting modifiable risk factors. This includes advising on the cessation or reduction of corticosteroid use, in consultation with other health-care providers, to determine the viable dosage. It's noted that a considerable proportion of acute CSCR cases can resolve on their own, and even up to 30 percent of chronic CSCR may improve without any intervention. If interventions are required, treatment options include photodynamic therapy, subthreshold laser, anti-VEGF and other potential oral therapies.

Modifiable Risk Factors

One of the most well-known risk factors is corticosteroids; both naturally occurring and medically prescribed corticosteroids, including those administered locally or systemically, have been linked to an increased risk of CSCR.¹⁰ Systemic corticosteroids in particular are recognized as an independent risk factor, and are as-

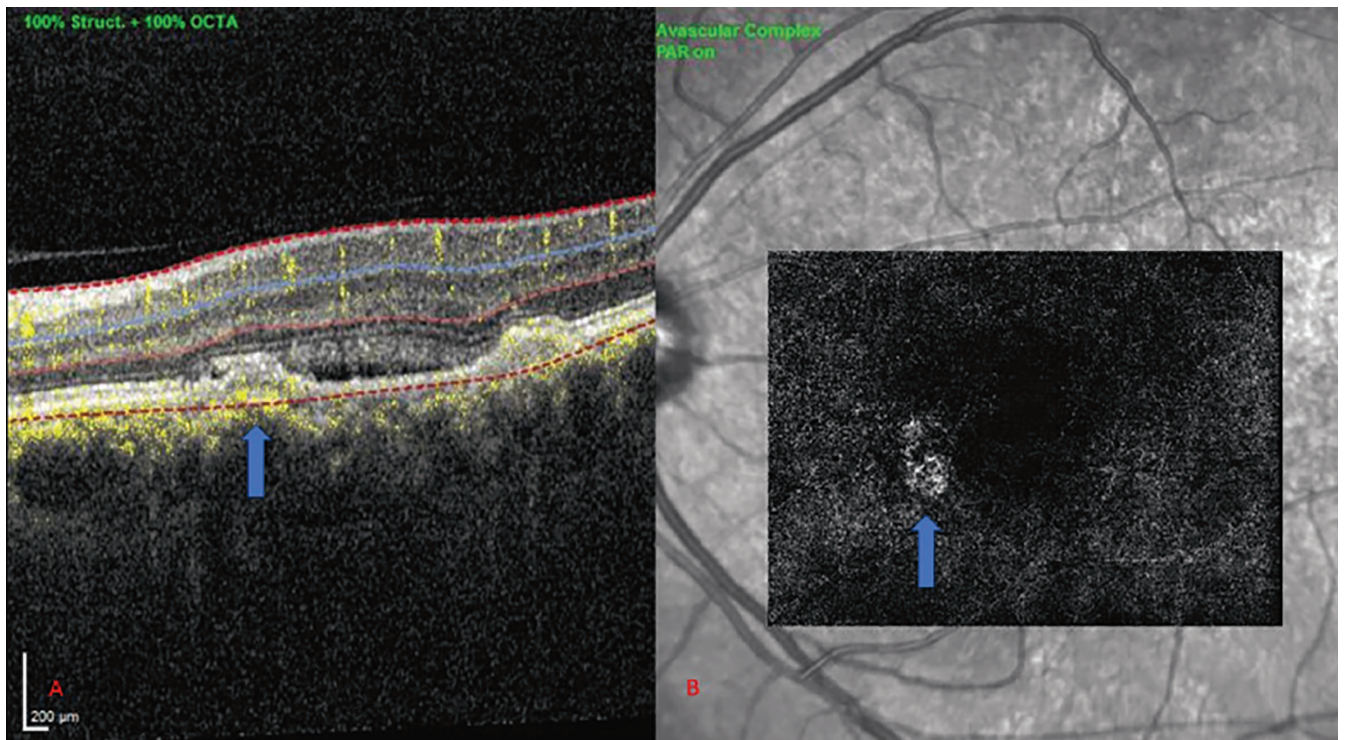


Figure 3. (A) OCT showing irregular PED in CSCR. (B) CNV corresponding to area of irregular PED (solid blue arrows).

sociated with not just onset but also with the prolongation and recurrence of CSCR. Despite the broad use of corticosteroids in medical practice, CSCR remains relatively rare, which suggests that the increased risk may not be strictly dose dependent, but rather influenced by increased vulnerability in certain individuals.

Cushing's syndrome, characterized by excessive cortisol production, is linked to an increased risk of CSCR. CSCR can sometimes be the presenting feature of patients with Cushing's syndrome. In one study, up to 7.7 percent of patients with Cushing's syndrome also had CSCR.²⁸ Furthermore, a case-series report found that SRF can dissipate in CSCR patients following surgical treatment of Cushing's syndrome.²⁹

Stress-inducing life situations such as shift work, inadequate sleep, circadian rhythm disruption, as well as type A behavioral traits are all also linked to increased risk of CSCR.³⁰⁻³³ Lastly, CSCR has also been reported to be at an increased risk during pregnancy due to changes in the choroidal circulation, specifically more so in the

third trimester.^{34,35}

Non-modifiable Risk Factors

Several risk factors have been identified for central serous chorioretinopathy, this includes male sex, which significantly increases the risk compared to females, as well as age, particularly in the 35- to 44-year-old range.¹⁰ Short axial length is another positive association.³⁶

Photodynamic Therapy

PDT involves intravenous administration of the photosensitizing agent verteporfin, followed by targeted application of laser to the area of interest, to produce free radicals which primarily affect the choriocapillaris. This leads to restructuring of vessels within the capillary bed in the vascular endothelium.³ Standard PDT treatment is a dose of 6 mg/m² body surface area of verteporfin. PDT can also be given at half that dosage.

Similarly, full-fluence PDT is when a light at 689 nm is applied to a designated area with a fluence of 50 J/cm² for 83 seconds, while half-fluence PDT is 25 J/cm² with

the same duration. Different combinations of PDT dose and fluence are used in different clinical practice, such as full-dose, half-fluence; or half-dose, full-fluence.³ Many groups have reported a high rate of resolution of SRF in CSCR following PDT. In addition, the choroidal thickness and hyperpermeability were also found to be alleviated following PDT.

The area targeted by PDT is guided by FA and ICG. On FA, the target area is the spots of leakage; on ICG, the target area is often set so that the diameter covers the localized hyperfluorescent area during the mid-phase.³

More recent prospective, randomized, controlled studies supporting its use came from the SPECTRA and PLACE trials.^{37,38} The SPECTRA trial showed that at three months follow-up, 78 percent of patients in the half-dose PDT arm had complete resolution of SRF compared to 17 percent in the eplerenone group.

In the PLACE trial, half-dose photodynamic therapy was compared to high density subthreshold micropulse laser (HSML): treatment with

half-dose photodynamic therapy was shown to be superior to HSML in both the focal leakage group and diffuse leakage group in terms of subretinal fluid resolution, at both three months (48 percent vs 16 percent) and 12 months follow-up (67 percent vs 21 percent).

Focal Laser

Focal laser is an inexpensive treatment modality that may be able to address extrafoveal leakage points in CSCR. Focal application of thermal laser was one of the earlier investigated treatment modalities, which is thought to address leakage by inducing scarring of abnormal RPE cells. While previous studies have shown that laser photocoagulation may reduce the duration of CSC, there have been limited trials as focal laser is rarely performed on leakage within 500 μ m of the fovea due to scarring and possible lesion expansion.³⁹ Focal laser can be a potential option especially for extramacular lesions.

Subthreshold Laser

Subthreshold/micropulse laser involves applying short, subthreshold micropulses of energy to the retina, promoting tissue repair without corresponding retinal damage. Due to its minimal thermal damage, it can be used close to the fovea.³ Various studies have suggested a broad range of micropulse laser techniques and laser types, complicating the comparison across different research findings. Nonetheless, the PACORES trial, although limited by its retrospective study design, compared micropulse laser with half-dose PDT. Although comparisons between the two cohorts weren't possible due to the study design, both groups demonstrated reduction in central macular thickness at 12 months follow-up.⁴⁰ In the PLACE trial, the high-density subthreshold micropulse laser (HSML) group achieved resolution of SRF in 28.8 percent of patients.³⁸

Due to its favorable safety profile, the Subthreshold Laser Ophthalmic

Society recommend the use of subthreshold laser in one month even for acute CSCR, instead of the convention of observing for a period of three to four months.⁴¹ The recommended settings are 5-percent duty cycle, 200 ms pulse duration, 100 to 200 μ m spot size, with no spacing between the spots. Some clinicians have argued that the lack of standardization has hindered the more widespread adoption of subthreshold laser.⁴²

Mineralocorticoid Antagonists

Mineralocorticoid dysfunction has been implicated in the pathogenesis of CSCR.⁴³ There have been animal models showing that overexpression of human mineralocorticoid can exhibit characteristics of pachychoroid phenotypes.⁴⁴ The mineralocorticoid receptor antagonist eplerenone has been long used as a treatment for CSCR. However, the VICI trial didn't find any significant difference between either 25 mg/day oral eplerenone, increasing up to 50 mg/day versus placebo. Nevertheless, one of the arguments against the findings is that eplerenone should be continued even where there is resolution of SRF, as stopping treatment can result in reoccurrence.⁴⁵

While multiple other oral medication treatment has been described, supportive evidence has been limited to mostly uncontrolled case series.

Anti-VEGF

Some case series have reported resolution of SRF in CSCR following treatment with anti-VEGF. However, the role of VEGF in the pathogenesis of CSCR is unclear. More recently, the incorporation of OCTA in the work-up of CSCR has helped to identify that secondary CNV may complicate CSCR in 24 to 39 percent of patients.^{46,47} Type 1 neovascularization occurs sub-RPE and can present with a shallow irregular PED or flat irregular PED (FIPED) (Figure 3).^{48,49} It's now believed that this group of eyes are likely to respond to intravitreal anti-VEGF therapy.³⁷ A case series of 88 patients with chronic CSCR iden-

tified neovascularization in one-third of eyes with shallow irregular PEDs on OCTA.⁵⁰ Therefore, eyes with these features should be evaluated in further detail with OCTA.

For eyes with CSCR without CNV, there's no substantial evidence indicating benefits in terms of anatomical or visual acuity results.

It's also important to consider type 1 neovascularization as part of pachychoroid neovascularopathy. Clues that point to PNV are Type 1 neovascularization lesion with pachychoroid features, thickened choroid, absent soft drusen and RPE changes overlying pachyvessels. PNV can be difficult to distinguish from CSCR on FA, as both can have quite similar angiographic signs. However, CSCR eyes are more likely to have the characteristic changes on FAF, such as descending tracts.

The Pachychoroid Disease Spectrum

The clinical relevance of pachychoroid in the context of CSCR lies in its inclusion within the pachychoroid disease spectrum (PDS), which encompasses a number of clinical conditions that share similar abnormalities in the choroid.¹¹ PDS conditions can evolve from one to another. Pachychoroid pigment epitheliopathy is considered a forme fruste of CSCR, but SRF may develop in these eyes during longitudinal follow-up. Choroidal congestion in PDS may aggravate or perpetuate choriocapillaris impairment. The resulting ischemic environment has been proposed to promote neovascularization in the form of pachychoroid neovascularopathy or polypoidal choroidal vasculopathy. Hence eyes with CSCR may develop secondary CNV within this context. Additionally, variations in the CFH gene have been linked to differences in choroidal thickness among specific Asian populations.⁵¹

In conclusion, our current understanding of CSCR has led to a new

(Continued on p. 68)



EDITED BY ERIK MASSENZIO, MD

WILLS EYE RESIDENT CASE REPORT

An 81-year-old female is referred to Wills Eye Hospital for photophobia and decreasing vision.

SUNIDHI RAMESH, MD, AND JAMES P. DUNN, MD
PHILADELPHIA

Presentation

An 81-year-old female with decreasing vision and photophobia referred by her outside glaucoma specialist to Wills Eye Hospital for evaluation of bilateral anterior uveitis.

History

Past ocular history was notable for herpetic keratitis of the right eye and pseudoexfoliation glaucoma of both eyes (with placement of Xen gel stent OD with mitomycin-C in 2021). She also had a remote history of central retinal vein occlusion in the left eye. Past medical history included hypertension and diabetes; other past surgical history was non-contributory. Medications included dorzolamide-timolol three times daily in the right eye (and two times daily in the left), brimonidine twice daily in the right eye, latanoprost at bedtime in the right eye and prednisolone acetate once daily in the right eye. She also took a daily multivitamin. Family history was non-contributory. She was a non-smoker with occasional alcohol use. Allergies include cephalixin (blisters) and levofloxacin (skin rash); sensitivities included gluten and lactose. Of note, she shared a history of an unknown reaction to oral moxifloxacin in 2010 that required chronic steroid therapy. Review of systems was negative for scalp tenderness, jaw claudication, fever and loss of appetite; other systemic review of systems was also negative.

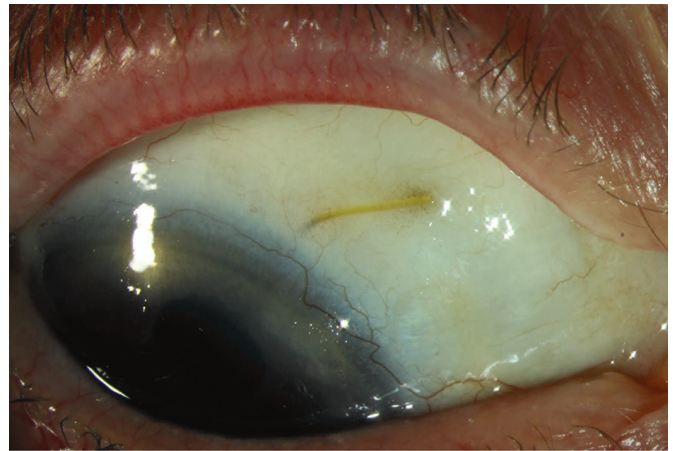


Figure 1. External photograph, right eye.

Examination

At presentation, visual acuity was 20/60 in the right eye and 20/40 in the left. IOP was 21 and 16 mmHg in the right and left eyes, respectively. External examination was unremarkable. Pupils were equal, round and reactive without afferent pupillary defect. Motility and confrontation visual fields were normal bilaterally. Ocular adnexae of both eyes were normal.

In the right eye, there was mild blepharitis and white conjunctiva without scleritis or ciliary flush. A Xen gel stent was well-covered superonasally with both vascularization and a flat bleb (*Figure 1*). There were no keratic precipitates, edema or infiltrates, although limbal stem-cell deficiency was present superiorly (*Figure 2*). The anterior chamber was deep with 1+ flare but no cells. The iris had scattered patchy mid-peripheral transillumination defects without nodules or neovascularization (*Figure 3*). A centered PC IOL was present. Posterior exam revealed advanced cupping with cup-to-disc ratio of greater than 0.9 with trace vitreous cell and posterior vitreous detachment.

The left eye also had mild blepharitis and white conjunctiva without scleritis or ciliary flush. The cornea was without keratic precipitates, edema or infiltrates; the anterior chamber was deep and quiet. The iris had patchy mid-peripheral transillumination defects 360 degrees without nodules or neovascularization (*Figure 4*). A centered PC IOL was present. Posterior exam revealed a cup-to-disc ratio of 0.3 with trace vitreous cell and posterior vitreous detachment.

What's your diagnosis? What management would you pursue? The case continues on the next page.

Work-up, Diagnosis and Treatment

Automated visual field testing, optical coherence tomography and fluorescein angiography were performed. Visual fields revealed dense, glaucomatous defects of the right eye. OCT of the retinal nerve fiber layer was consistent with glaucomatous damage since the macular OCT didn't reveal explanatory retinal pathology. Fluorescein angiography showed normal arteriovenous transit time without macular or vascular leakage.

Given the clinical history and examination, the patient was diagnosed with sequelae of bilateral acute iris transillumination (BAIT) secondary to oral moxifloxacin use in 2010. It was presumed that BAIT, rather than pseudoexfoliation, was the etiology of her pigmentary glaucoma. She was counseled to avoid oral fluoroquinolones at all costs. There was no bleb over the Xen gel stent in her right eye; IOP was also above target of 10 to 12 mmHg. She was offered gonioscopy-assisted transluminal trabeculotomy, Omni or a tube shunt in the right eye to better control her IOP, and she planned to discuss these options with her outside glaucoma specialist. She was told to continue the prednisolone acetate 1% once daily in the right eye as she self-reported severe pain on prior attempts of stopping the drop.

Ten months later, the patient returned for a follow-up visit at Wills Eye Hospital. In the interim, she had undergone GATT in the right eye, unfortunately complicated by visually significant vitreous hemorrhage. She was taken off the latanoprost OD. Best-corrected visual acuity was 20/80 in the right and 20/70 in the left. IOP was 13 mmHg in both eyes. Exam was otherwise unchanged. The BAIT was deemed to be stable, and she was told to follow up with the Uveitis clinic in six months.

Discussion

Bilateral acute depigmentation of the iris (BADI) was first described in a 2004 case series in five patients who presented with sudden-onset ocular discomfort and were all found to have varying degrees of iris depigmentation; none of the eyes had "iris transillumination defects, inflammatory keratic precipitates or inflammatory cells in the anterior chamber."¹ In the years since, BAIT has joined BADI to form a spectrum of diseases with varying amounts of depigmentation and transillumination defects.² Both conditions involve iris pigmentary release (from the epithelium in BAIT and the stroma in BADI) leading to the potential for trabecular meshwork occlusion and resultant pigmentary glaucoma.³

BADI and BAIT are rare, with fewer than 100 published cases (primarily in Europe and the Middle East) in the literature to date.⁴ The vast majority of patients present with acute ocular pain and photophobia, presumed to be related to the defects in the iris. In a 2019 literature review,⁴ 60 of the 93 reported patients were women, with a mean age of 46

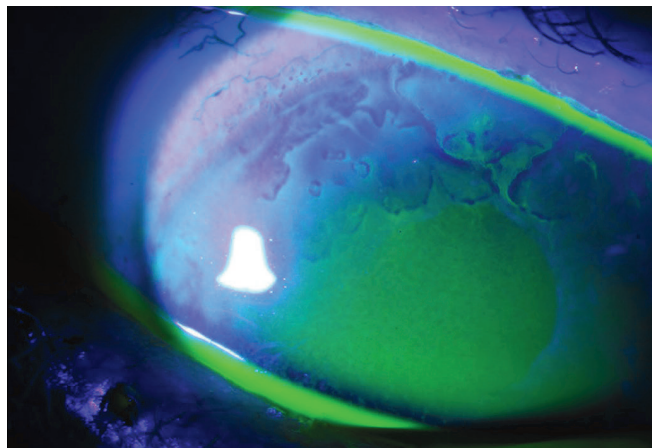


Figure 2. Fluorescein stain, right eye.

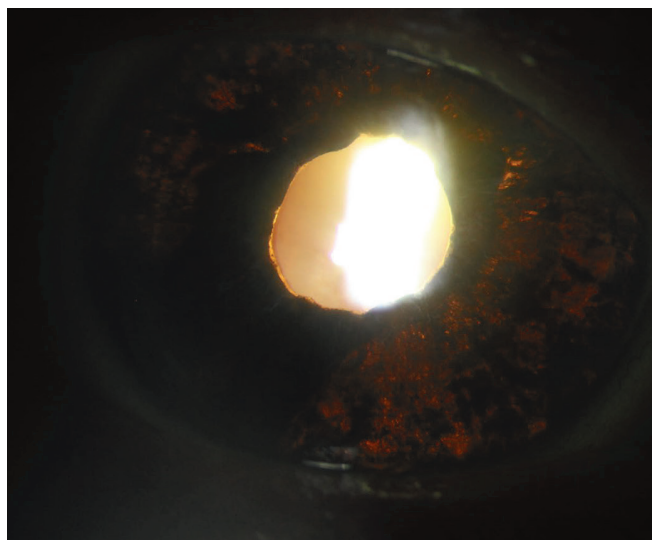


Figure 3. Iris transillumination, right eye.

±9 years. Notably, 69 percent of patients in this study had an upper respiratory tract infection in the days or weeks preceding the onset of their ocular symptoms; 81 percent of these patients had been treated with oral or intravenous antibiotic therapy, often with moxifloxacin.⁴ Other studies have also identified prior fluoroquinolone therapy as a potential trigger for BADI and BAIT.⁵⁻⁷ HLA-B51 and HLA-B27 have been implicated in 20 to 40 percent of patients, implying underlying autoimmune and genetic etiologies may sensitize certain patients to fluoroquinolone treatment.^{5,8} One report demonstrating simultaneous onset of BADI in two siblings highlights this possibility.⁹ Interestingly, COVID-19 has also been shown to be associated with development of BADI.¹⁰

Of note, only systemic (rather than topical) fluoroquinolones have been implicated in BADI and BAIT; in a 2013 case report, glaucoma specialist Robert Knape postulated that this may be in part to pharmacokinetic variations between the two forms of administration.¹¹ Topical moxi-

floxacin results in over tenfold higher concentrations in the aqueous humor than in the vitreous compared to oral administration, which yields comparable levels in both compartments.^{12,13} In addition, systemic moxifloxacin likely maintains high steady-state concentrations in the ocular tissues “at risk” compared to the intermittent levels allowed by topical therapy. As the exact pathogenesis of BADI and BAIT is poorly understood,¹⁴ the mechanism behind moxifloxacin-induced BADI/BAIT in particular (as compared to other fluoroquinolones) is largely unknown.⁵

Both syndromes exhibit increased intraocular pressure, but BAIT tends to have a higher and more frequent occurrence compared to BADI; this may be in part to the permanence of transillumination over simple depigmentation. In BAIT, high IOP occurs earlier and often leads to post-BAIT pigmentary glaucoma.² Many patients require ongoing topical treatment and filtering surgeries to control IOP.^{15,16} Overall, BADI appears to be more reversible and has a better prognosis.

Treatment of both BAIT and BADI involves mitigation of risk factors, management of symptoms and control of complications. Fluoroquinolones, if relevant to the patient’s history, must be discontinued. Topical corticosteroids have been used in larger case series¹⁷ but with equivocal response; attempts to taper topical corticosteroids, however, have been shown to trigger a recurrence in presenting symptoms.⁹ Cases with elevated IOP seem to be particularly refractive to topical therapies; in one study, anti-hypertensive medications demonstrated sufficient IOP control in only 53 percent of eyes.³ Laser iridoplasty, filtration surgeries with mitomycin C and trabeculotomy ab interno are procedures that have been pursued in eyes requiring better IOP control.^{16,18,19} Given the low global prevalence of BAIT and BADI, the true disease course of both syndromes is difficult to characterize. Some cases appear to resolve completely within 14 months¹⁸ with BADI irises showing potential for full re-pigmentation;¹⁷ other patients with BAIT endure persistent symptoms and complications from iris transillumination and glaucomatous damage.

Ultimately, BADI and BAIT are rare disease entities presenting with photophobia and decreased vision, often instigated by oral or intravenous fluoroquinolone therapy following an upper respiratory infection. Both syndromes (BAIT in particular) can lead to elevated IOP that may masquerade as simple pigmentary glaucoma; in these patients, IOP control is difficult and may require repeated surgical treatment. In our case, this 81-year-old female was diagnosed with BAIT over 10 years after fluoroquinolone exposure with severe vision loss in one eye from BAIT-induced glaucoma. ◀

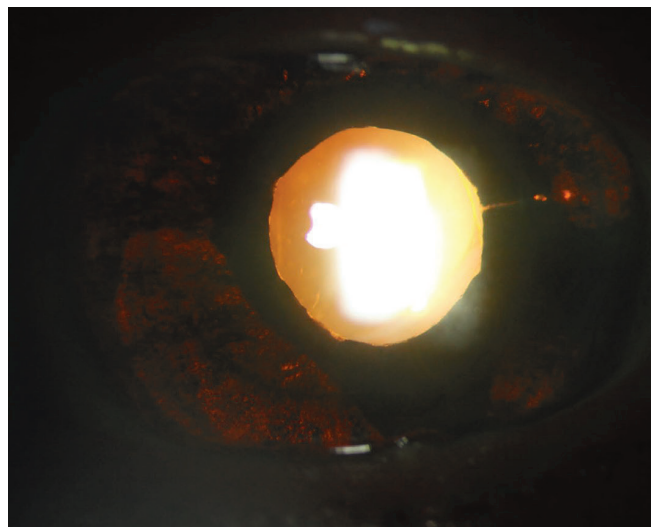


Figure 4. Iris transillumination, left eye.

1. Tugal-Tutkun I, Urgancioglu M. Bilateral acute depigmentation of the iris. *Graefes Arch Clin Exp Ophthalmol* 2006;244:6:742-6.

2. Tugal-Tutkun I, Onal S, Garip A, et al. Bilateral acute iris transillumination. *Arch Ophthalmol* 2011;129:10:1312-9.

3. Tranos P, Lokovitis E, Masselos S, Kozeis N, Triantafylla M, Markomichelakis N. Bilateral acute iris transillumination following systemic administration of antibiotics. *Eye (Lond)* 2018;32:7:1190-1196.

4. Perone JM, Chaussard D, Hayek G. Bilateral acute iris transillumination (BAIT) syndrome: Literature review. *Clin Ophthalmol* 2019;13:935-943.

5. Hinkle DM, Dacey MS, Mandelcorn E, et al. Bilateral acute uveitis associated with fluoroquinolone therapy. *Cutan Ocul Toxicol* 2012;31:2:111-6.

6. Kreps EO, Hondeghem K, Augustinus A, et al. Is oral moxifloxacin associated with bilateral acute iris transillumination? *Acta Ophthalmol* 2018;96:4:e547-e548.

7. Morshedi RG, Bettis DI, Moshirfar M, Vitale AT. Bilateral acute iris transillumination following systemic moxifloxacin for respiratory illness: Report of two cases and review of the literature. *Ocul Immunol Inflamm* 2012;20:4:266-72.

8. Wefers Bettink-Remeijer M, Brouwers K, van Langenhove L, et al. Uveitis-like syndrome and iris transillumination after the use of oral moxifloxacin. *Eye (Lond)* 2009;23:12:2260-2.

9. Amin R, Nabih A, Khater N. Bilateral acute depigmentation of the iris in two siblings simultaneously. *Am J Ophthalmol Case Rep* 2018;10:257-260.

10. Soydan A, Kaymaz A. Bilateral acute depigmentation of the iris determined in two cases after COVID-19 infection. *Indian J Ophthalmol* 2023;71:3:1030-1032.

11. Knappe RM, Sayyad FE, Davis JL. Moxifloxacin and bilateral acute iris transillumination. *J Ophthalmic Inflamm Infect* 2013;3:1:10.

12. Hariprasad SM, Blinder KJ, Shah GK, et al. Penetration pharmacokinetics of topically administered 0.5% moxifloxacin ophthalmic solution in human aqueous and vitreous. *Arch Ophthalmol* 2005;123:1:39-44.

13. Hariprasad SM, Shah GK, Mieler WF, et al. Vitreous and aqueous penetration of orally administered moxifloxacin in humans. *Arch Ophthalmol* 2006;124:2:178-82.

14. Tugal-Tutkun I, Altan C. Bilateral Acute Depigmentation of Iris (BADI) and Bilateral Acute Iris Transillumination (BAIT)-An update. *Turk J Ophthalmol* 2022;52:5:342-347.

15. Hernandez Pardines F, Serra Verdu MC, Font Julia E, Molina Martin JC. Aqueous humor misdirection syndrome after glaucoma filtering surgery in patient with bilateral acute iris transillumination (BAIT) syndrome. *Arch Soc Esp Ophthalmol (Engl Ed)* 2018;93:9:444-446.

16. Den Beste KA, Okeke C. Trabeculotomy ab interno with Trabectome as surgical management for systemic fluoroquinolone-induced pigmentary glaucoma: A case report. *Medicine (Baltimore)* 2017;96:43:e7936.

17. Tugal-Tutkun I, Araz B, Taskapili M, et al. Bilateral acute depigmentation of the iris: Report of 26 new cases and four-year follow-up of two patients. *Ophthalmology* 2009;116:8:1552-7, 1557 e1.

18. Willermain F, Deflorenne C, Bouffieux C, Janssens X, Koch P, Caspers L. Uveitis-like syndrome and iris transillumination after the use of oral moxifloxacin. *Eye (Lond)* 2010;24:8:1419; author reply 1419-20.

19. Gonul S, Bozkurt B. Bilateral acute iris transillumination (BAIT) initially misdiagnosed as acute iridocyclitis. *Arq Bras Ophthalmol* 2015;78:2:115-7.

(Continued from p. 64)

classification consensus. The adoption of multimodal imaging allows for more precise evaluation of the extent of RPE involvement, as well as identifying the areas of leakage. Current best clinical practice involves careful patient assessment, modification of risk factors and judicious use of different treatment options based on availability and clinical presentation. ◀

1. Daruich A, Matet A, Behar-Cohen F. Central serous chorioretinopathy. *Macular Edema* 2017;58:27–38.
2. Kitzmann AS, Pulido JS, Diehl NN, Hodge DO, Burke JP. The incidence of central serous chorioretinopathy in Olmsted County, Minnesota, 1980-2002. *Ophthalmology* 2008 Jan;115:1:169–73.
3. Feenstra HMA, van Dijk EHC, Cheung CMG, Ohno-Matsui K, Lai TYY, Koizumi H, et al. Central serous chorioretinopathy: An evidence-based treatment guideline. *Prog Retin Eye Res* 2024 Jan 31 [online ahead of print];101236.
4. Daruich A, Matet A, Dirani A, Bousquet E, Zhao M, Farman N, et al. Central serous chorioretinopathy: Recent findings and new pathophysiology hypothesis. *Prog Retin Eye Res* 2015;48:82–118.
5. Spaide RF, Gemmy Cheung CM, Matsumoto H, Kishi S, Boon CJF, van Dijk EHC, et al. Venous overload choroidopathy: A hypothetical framework for central serous chorioretinopathy and allied disorders. *Prog Retin Eye Res*. 2022 Jan;86:100973.
6. Brown R, Mohan S, Chhablani J. Pachychoroid spectrum disorders: An updated review. *J Ophthalmic Vis Res* 2023;18:2:212–29.
7. Chhablani J, Cohen FB, Aymard P, Beydoun T, Bousquet E, Cohen FB, et al. Multimodal imaging-based central serous chorioretinopathy classification. *Ophthalmol Retina* 2020 Nov 1;4:11:1043–6.
8. Chhablani J, Behar-Cohen F, Central Serous Chorioretinopathy International Group. Validation of central serous chorioretinopathy multimodal imaging-based classification system. *Graefes Arch Clin Exp Ophthalmol* 2022;260:4:1161–9.
9. van Dijk EHC, Boon CJF. Serous business: Delineating the broad spectrum of diseases with subretinal fluid in the macula. *Prog Retin Eye Res* 2021 Sep;84:100955.
10. Kaye R, Chandra S, Sheth J, Boon CJF, Sivaprasad S, Lotery A. Central serous chorioretinopathy: An update on risk factors, pathophysiology and imaging modalities. *Prog Retin Eye Res* 2020 Nov;79:100865.
11. Cheung CMG, Lee WK, Koizumi H, Dansingani K, Lai TYY, Freund KB. Pachychoroid disease. *Eye Lond Engl* 2019;33:1:14–33.
12. Spaide RF, Klancnik JM. Fundus autofluorescence and central serous chorioretinopathy. *Ophthalmology* 2005;112:5:825–33.
13. Matsumoto H, Kishi S, Otani T, Sato T. Elongation of photoreceptor outer segment in central serous chorioretinopathy. *Am J Ophthalmol* 2008;145:1:162–8.
14. Matsumoto H, Sato T, Kishi S. Outer nuclear layer thickness at the fovea determines visual outcomes in resolved central serous chorioretinopathy. *Am J Ophthalmol* 2009;148:1:105–110.e1.
15. Iida T, Yannuzzi LA, Spaide RF, Borodoker N, Carvalho CA, Negrao S. Cystoid macular degeneration in chronic central serous chorioretinopathy. *Retina Phila Pa* 2003;23:1:1–7;quiz 137–8.
16. Cardillo Piccolino F, Eandi CM, Ventre L, Rigault de la Longrais RC, Grignolo FM. Photodynamic therapy for chronic central serous chorioretinopathy. *Retina Phila Pa* 2003;23:6:752–63.

17. Feenstra HMA, Hensman J, Gkika T, Lipkova V, Hoyng CB, Diederer RMH, et al. Spontaneous resolution of chronic central serous chorioretinopathy: 'Fuji Sign'. *Ophthalmol Retina* 2022;6:9:861–3.
18. Asano KS, Asaoka R, Asano S, Azuma K, Inoue T, Obata R. Elongated photoreceptor outer segment length and prognosis of chronic central serous chorioretinopathy. *Retina Phila Pa* 2020;40:4:750–7.
19. Fujimoto H, Gomi F, Wakabayashi T, Sawa M, Tsujikawa M, Tano Y. Morphologic changes in acute central serous chorioretinopathy evaluated by fourier-domain optical coherence tomography. *Ophthalmology* 2008;115:9:1494–500, 1500.e1-2.
20. Hirami Y, Tsujikawa A, Sasahara M, Gotoh N, Tamura H, Otani A, et al. Alterations of retinal pigment epithelium in central serous chorioretinopathy. *Clin Experiment Ophthalmol* 2007;35:3:225–30.
21. Wang M, Munch IC, Hasler PW, Prunte C, Larsen M. Central serous chorioretinopathy. *Acta Ophthalmol (Copenh)* 2008;86:2:126–45.
22. Prunte C, Flammer J. Choroidal capillary and venous congestion in central serous chorioretinopathy. *Am J Ophthalmol* 1996 Jan;121:1:26–34.
23. Pang CE, Shah VP, Sarraf D, Freund KB. Ultra-widefield imaging with autofluorescence and indocyanine green angiography in central serous chorioretinopathy. *Am J Ophthalmol* 2014;158:2:362-371.e2.
24. Gemenetzi M, De Salvo G, Lotery AJ. Central serous chorioretinopathy: An update on pathogenesis and treatment. *Eye* 2010;24:12:1743–56.
25. Lee WJ, Lee JH, Lee BR. Fundus autofluorescence imaging patterns in central serous chorioretinopathy according to chronicity. *Eye Lond Engl* 2016;30:10:1336–42.
26. Zola M, Chatziralli I, Menon D, Schwartz R, Hykin P, Sivaprasad S. Evolution of fundus autofluorescence patterns over time in patients with chronic central serous chorioretinopathy. *Acta Ophthalmol (Copenh)* 2018;96:7:e835–9.
27. Spaide R. Autofluorescence from the outer retina and subretinal space: Hypothesis and review. *Retina Phila Pa* 2008;28:1:5–35.
28. Holtz JK, Larsson JME, Hansen MS, van Dijk EHC, Subhy Y. Pachychoroid spectrum diseases in patients with Cushing's syndrome: A systematic review with meta-analyses. *J Clin Med* 2022;29;11:15:4437.
29. van Dijk EHC, Dijkman G, Biermasz NR, van Haalen FM, Pereira AM, Boon CJF. Chronic central serous chorioretinopathy as a presenting symptom of Cushing syndrome. *Eur J Ophthalmol* 2016;26:5:442–8.
30. Yannuzzi LA. Type A behavior and central serous chorioretinopathy. *Retina Phila Pa* 2012;32 Suppl 1:709.
31. Ji Y, Li M, Zhang X, Peng Y, Wen F. Poor sleep quality is the risk factor for central serous chorioretinopathy. *J Ophthalmol* 2018;2018:9450297.
32. Setrouk E, Hubault B, Vankemmel F, Zambrowski O, Nazeyrollas P, Delemer B, et al. Circadian disturbance and idiopathic central serous chorioretinopathy. *Graefes Arch Clin Exp Ophthalmol* 2016;254:11:2175–81.
33. Bousquet E, Dhundass M, Lehmann M, Rothschild PR, Bayon V, Leger D, et al. Shift work: A risk factor for central serous chorioretinopathy. *Am J Ophthalmol* 2016;165:23–8.
34. Sunness JS. The pregnant woman's eye. *Surv Ophthalmol* 1988;32:4:219–38.
35. Yu J, Li L, Jiang C, Chang Q, Xu G. Clinical characteristics of pregnancy-associated central serous chorioretinopathy in the Chinese Population. *J Ophthalmol*. 2021 Dec 16;2021:e5580075.
36. Terao N, Koizumi H, Kojima K, Kusada N, Nagata K, Yamagishi T, et al. Short axial length and hyperopic refractive error are risk factors of central serous chorioretinopathy. *Br J Ophthalmol* 2020;104:9:1260–5.
37. van Rijssen TJ, van Dijk EHC, Tsonaka R, Feenstra HMA, Dijkman G, Peters PJH, et al. Half-dose photodynamic therapy versus eplerenone in chronic central serous chorioretinopathy (SPECTRA): A randomized controlled trial. *Am J Ophthalmol* 2022;233:101–10.

38. van Dijk EHC, Fauser S, Breukink MB, Blanco-Garavito R, Groenewoud JMM, Keunen JEE, et al. Half-dose photodynamic therapy versus high-density subthreshold micropulse laser treatment in patients with chronic central serous chorioretinopathy: The PLACE Trial. *Ophthalmology* 2018;125:10:1547–55.
39. Leaver P, Williams C. Argon laser photocoagulation in the treatment of central serous retinopathy. *Br J Ophthalmol* 1979;63:10:674–7.
40. Roca JA, Wu L, Fromow-Guerra J, Rodríguez FJ, Berrocal MH, Rojas S, et al. Yellow (577 nm) micropulse laser versus half-dose verteporfin photodynamic therapy in eyes with chronic central serous chorioretinopathy: Results of the Pan-American Collaborative Retina Study (PACORES) Group. *Br J Ophthalmol* 2018;102:12:1696–700.
41. Chhablani J. Subthreshold laser therapy guidelines for retinal diseases. *Eye* 2022;36:12:2234–5.
42. Keunen JEE, Battaglia-Parodi M, Vujosevic S, Luttrull JK. International Retinal Laser Society guidelines for subthreshold laser treatment. *Transl Vis Sci Technol* 2020;9:9:15.
43. Bousquet E, Zhao M, Daruich A, Behar-Cohen F. Mineralocorticoid antagonists in the treatment of central serous chorioretinopathy: Review of the pre-clinical and clinical evidence. *Exp Eye Res* 2019;187:107754.
44. Canonica J, Zhao M, Favez T, Gelizé E, Jonet L, Kowalczyk L, et al. Pathogenic effects of mineralocorticoid pathway activation in retinal pigment epithelium. *Int J Mol Sci* 2021;22:17:9618.
45. Stanescu-Segall D, Touhami S, Bodaghi B, LeHoang P. Eplerenone for chronic central serous chorioretinopathy. *The Lancet* 2020;396:10262:1556–7.
46. Mrejen S, Balaratnasingam C, Kaden TR, Bottini A, Dansingani K, Bhavsar KV, et al. Long-term visual outcomes and causes of vision loss in chronic central serous chorioretinopathy. *Ophthalmology* 2019;126:4:576–88.
47. Savastano MC, Rispoli M, Lumbroso B. The incidence of neovascularization in central serous chorioretinopathy by optical coherence tomography angiography. *Retina Phila Pa* 2021;41:2:302–8.
48. Bonini Filho MA, de Carlo TE, Ferrara D, Adhi M, Bauml CR, Witkin AJ, et al. Association of choroidal neovascularization and central serous chorioretinopathy with optical coherence tomography angiography. *JAMA Ophthalmol* 2015;133:8:899–906.
49. Liu T, Lin W, Zhou S, Meng X. Optical coherence tomography angiography of flat irregular pigment epithelial detachments in central serous chorioretinopathy. *Br J Ophthalmol* [online ahead of print]. 2020 Apr 7 [Accessed Mar 14, 2024]. Available from: <https://bjo.bmj.com/content/early/2020/05/05/bjophthalmol-2019-315318>
50. Bousquet E, Bonnin S, Mrejen S, Krivosic V, Tadayoni R, Gaudric A. Optical coherence tomography angiography of flat irregular pigment epithelium detachment in chronic central serous chorioretinopathy. *Retina Phila Pa* 2018;38:3:629–38.
51. Fenner BJ, Li H, Gan ATL, Song YS, Tham YC, Jonas JB, et al. Genetic variability of complement factor H has ethnicity-specific associations with choroidal thickness. *Invest Ophthalmol Vis Sci* 2023;64:2:10.

ABOUT THE AUTHORS



Dr. Chong and Dr. Gilead are both senior clinical research fellows at the Singapore Eye Research Institute.



Dr. Chong is currently a professor at Duke-NUS Medical School, National University of Singapore (NUS). She is the head and senior consultant of the Medical Retina Department at SNEC, and head of the Retina Research Group at the Singapore Eye Research Institute.



SYFOVRE® (pegcetacoplan injection), for intravitreal use
BRIEF SUMMARY OF PRESCRIBING INFORMATION
Please see SYFOVRE full Prescribing Information for details.

INDICATIONS AND USAGE

SYFOVRE is indicated for the treatment of geographic atrophy (GA) secondary to age-related macular degeneration (AMD).

CONTRAINDICATIONS

Ocular or Periocular Infections

SYFOVRE is contraindicated in patients with ocular or periocular infections.

Active Intraocular Inflammation

SYFOVRE is contraindicated in patients with active intraocular inflammation.

WARNINGS AND PRECAUTIONS

Endophthalmitis and Retinal Detachments

Intravitreal injections, including those with SYFOVRE, may be associated with endophthalmitis and retinal detachments. Proper aseptic injection technique must always be used when administering SYFOVRE in order to minimize the risk of endophthalmitis. Patients should be instructed to report any symptoms suggestive of endophthalmitis or retinal detachment without delay and should be managed appropriately.

Retinal Vasculitis and/or Retinal Vascular Occlusion

Retinal vasculitis and/or retinal vascular occlusion, typically in the presence of intraocular inflammation, have been reported with the use of SYFOVRE. Cases may occur with the first dose of SYFOVRE and may result in severe vision loss. Discontinue treatment with SYFOVRE in patients who develop these events. Patients should be instructed to report any change in vision without delay.

Neovascular AMD

In clinical trials, use of SYFOVRE was associated with increased rates of neovascular (wet) AMD or choroidal neovascularization (12% when administered monthly, 7% when administered every other month and 3% in the control group) by Month 24. Patients receiving SYFOVRE should be monitored for signs of neovascular AMD. In case anti-Vascular Endothelial Growth Factor (anti-VEGF) is required, it should be given separately from SYFOVRE administration.

Intraocular Inflammation

In clinical trials, use of SYFOVRE was associated with episodes of intraocular inflammation including: vitritis, vitreal cells, iridocyclitis, uveitis, anterior chamber cells, iritis, and anterior chamber flare. After inflammation resolves patients may resume treatment with SYFOVRE.

Increased Intraocular Pressure

Acute increase in IOP may occur within minutes of any intravitreal injection, including with SYFOVRE. Perfusion of the optic nerve head should be monitored following the injection and managed as needed.

ADVERSE REACTIONS

Clinical Trials Experience

Because clinical trials are conducted under widely varying conditions, adverse reaction rates observed in the clinical trials of a drug cannot be directly compared to rates in the clinical trials of another drug and may not reflect the rates observed in practice.

A total of 839 patients with GA in two Phase 3 studies (OAKS and DERBY) were treated with intravitreal SYFOVRE, 15 mg (0.1 mL of 150 mg/mL solution). Four hundred nineteen (419) of these patients were treated in the affected eye monthly and 420 were treated in the affected eye every other month. Four hundred seventeen (417) patients were assigned to sham. The most common adverse reactions ($\geq 5\%$) reported in patients receiving SYFOVRE were ocular discomfort, neovascular age-related macular degeneration, vitreous floaters, and conjunctival hemorrhage.

The most common adverse reactions ($\geq 5\%$) reported in patients receiving SYFOVRE were ocular discomfort, neovascular age-related macular degeneration, vitreous floaters, and conjunctival hemorrhage.

Table 1: Adverse Reactions in Study Eye Reported in $\geq 2\%$ of Patients Treated with SYFOVRE Through Month 24 in Studies OAKS and DERBY

Adverse Reactions	PM (N = 419) %	PEOM (N = 420) %	Sham Pooled (N = 417) %
Ocular discomfort*	13	10	11
Neovascular age-related macular degeneration*	12	7	3
Vitreous floaters	10	7	1
Conjunctival hemorrhage	8	8	4
Vitreous detachment	4	6	3
Retinal hemorrhage	4	5	3
Punctate keratitis*	5	3	<1
Posterior capsule opacification	4	4	3
Intraocular inflammation*	4	2	<1
Intraocular pressure increased	2	3	<1

PM: SYFOVRE monthly; PEOM: SYFOVRE every other month

*The following reported terms were combined:

Ocular discomfort included: eye pain, eye irritation, foreign body sensation in eyes, ocular discomfort, abnormal sensation in eye

Neovascular age-related macular degeneration included: exudative age-related macular degeneration, choroidal neovascularization

Punctate keratitis included: punctate keratitis, keratitis

Intraocular inflammation included: vitritis, vitreal cells, iridocyclitis, uveitis, anterior chamber cells, iritis, anterior chamber flare

Endophthalmitis, retinal detachment, hyphema and retinal tears were reported in less than 1% of patients. Optic ischemic neuropathy was reported in 1.7% of patients treated monthly, 0.2% of patients treated every other month and 0.0% of patients assigned to sham. Deaths were reported in 6.7% of patients treated monthly, 3.6% of patients treated every other month and 3.8% of patients assigned to sham. The rates and causes of death were consistent with the elderly study population.

Postmarketing Experience

The following adverse reactions have been identified during postapproval use of SYFOVRE. Because these reactions are reported voluntarily from a population of uncertain size, it is not always possible to reliably estimate their frequency or establish a causal relationship to drug exposure. Eye disorders: retinal vasculitis with or without retinal vascular occlusion.

USE IN SPECIFIC POPULATIONS

Pregnancy

Risk Summary

There are no adequate and well-controlled studies of SYFOVRE administration in pregnant women to inform a drug-associated risk. The use of SYFOVRE may be considered following an assessment of the risks and benefits.

Systemic exposure of SYFOVRE following ocular administration is low. Subcutaneous administration of pegcetacoplan to pregnant monkeys from the mid gestation period through birth resulted in increased incidences of abortions and stillbirths at systemic exposures 1040-fold higher than that observed in humans at the maximum recommended human ophthalmic dose (MRHOD) of SYFOVRE (based on the area under the curve (AUC) systemically measured levels). No adverse maternal or fetal effects were observed in monkeys at systemic exposures approximately 470-fold higher than that observed in humans at the MRHOD.

In the U.S. general population, the estimated background risk of major birth defects and miscarriage in clinically recognized pregnancies is 2-4% and 15-20%, respectively.

Lactation

Risk Summary

It is not known whether intravitreal administered pegcetacoplan is secreted in human milk or whether there is potential for absorption and harm to the infant. Animal data suggest that the risk of clinically relevant exposure to the infant following maternal intravitreal treatment is minimal. Because many drugs are excreted in human milk, and because the potential for absorption and harm to infant growth and development exists, caution should be exercised when SYFOVRE is administered to a nursing woman.

Females and Males of Reproductive Potential

Contraception

Females: It is recommended that women of childbearing potential use effective contraception methods to prevent pregnancy during treatment with intravitreal pegcetacoplan. Advise female patients of reproductive potential to use effective contraception during treatment with SYFOVRE and for 40 days after the last dose. For women planning to become pregnant, the use of SYFOVRE may be considered following an assessment of the risks and benefits.

Pediatric Use

The safety and effectiveness of SYFOVRE in pediatric patients have not been established.

Geriatric Use

In clinical studies, approximately 97% (813/839) of patients randomized to treatment with SYFOVRE were ≥ 65 years of age and approximately 72% (607/839) were ≥ 75 years of age. No significant differences in efficacy or safety were seen with increasing age in these studies. No dosage regimen adjustment is recommended based on age.

PATIENT COUNSELING INFORMATION

Advise patients that following SYFOVRE administration, patients are at risk of developing endophthalmitis, retinal detachments, retinal vasculitis with or without retinal vascular occlusion and neovascular AMD. If the eye becomes red, sensitive to light, painful, or if a patient develops any change in vision such as flashing lights, blurred vision or metamorphopsia, instruct the patient to seek immediate care from an ophthalmologist. Patients may experience temporary visual disturbances associated either with the intravitreal injection with SYFOVRE or the eye examination. Advise patients not to drive or use machinery until visual function has recovered sufficiently.

Manufactured for:
Apellis Pharmaceuticals, Inc.
100 Fifth Avenue
Waltham, MA 02451

SYF-PI-30NOV2023-2.0

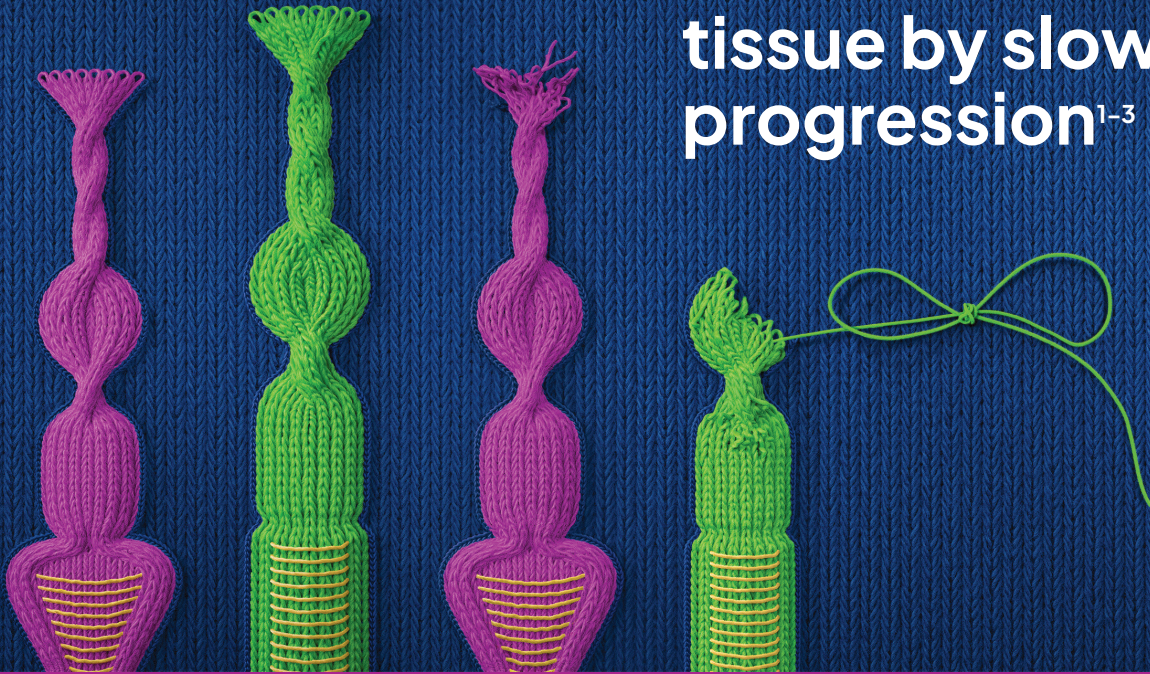APELLIS®, SYFOVRE® and their respective logos are registered trademarks of Apellis Pharmaceuticals, Inc.
©2023 Apellis Pharmaceuticals, Inc.

12/23 US-PEGGA-2200163 v4.0

SYFOVRE[®]
(pegcetacoplan injection)
15 mg / 0.1 mL

GA unravels so much

**Save retinal
tissue by slowing
progression**¹⁻³



INDICATION

SYFOVRE[®] (pegcetacoplan injection) is indicated for the treatment of geographic atrophy (GA) secondary to age-related macular degeneration (AMD).

IMPORTANT SAFETY INFORMATION

CONTRAINDICATIONS

- SYFOVRE is contraindicated in patients with ocular or periocular infections, and in patients with active intraocular inflammation

WARNINGS AND PRECAUTIONS

● Endophthalmitis and Retinal Detachments

- Intravitreal injections, including those with SYFOVRE, may be associated with endophthalmitis and retinal detachments. Proper aseptic injection technique must always be used when administering SYFOVRE to minimize the risk of endophthalmitis. Patients should be instructed to report any symptoms suggestive of endophthalmitis or retinal detachment without delay and should be managed appropriately.

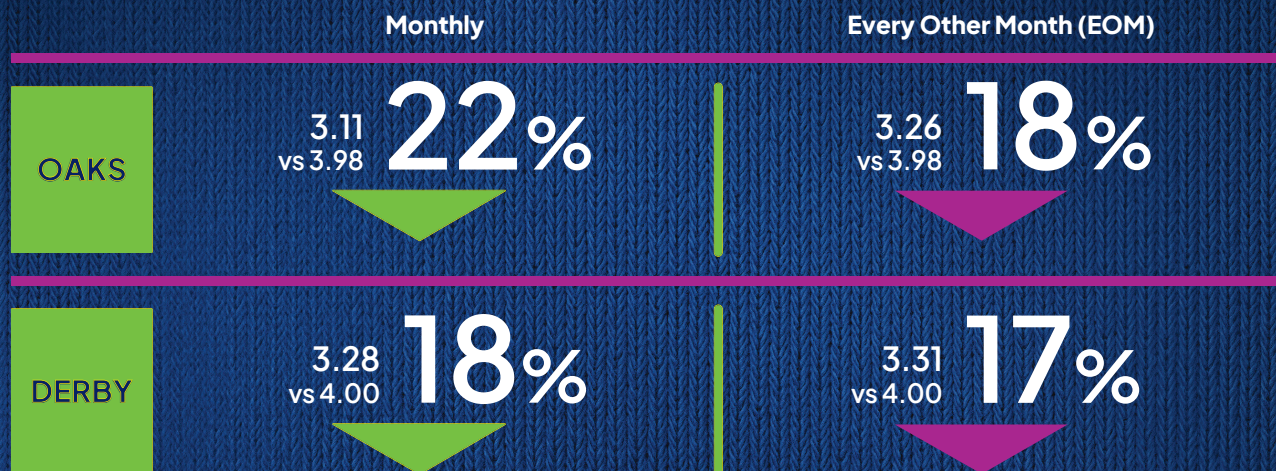
● Retinal Vasculitis and/or Retinal Vascular Occlusion

- Retinal vasculitis and/or retinal vascular occlusion, typically in the presence of intraocular inflammation, have been reported with the use of SYFOVRE. Cases may occur with the first dose of SYFOVRE and may result in severe vision loss. Discontinue treatment with SYFOVRE in patients who develop these events. Patients should be instructed to report any change in vision without delay.

● Neovascular AMD

- In clinical trials, use of SYFOVRE was associated with increased rates of neovascular (wet) AMD or choroidal neovascularization (12% when administered monthly, 7% when administered every other month and 3% in the control group) by Month 24. Patients receiving SYFOVRE should be monitored for signs of neovascular AMD. In case anti-Vascular Endothelial Growth Factor (anti-VEGF) is required, it should be given separately from SYFOVRE administration.

SYFOVRE achieved continuous reductions in mean lesion growth rate* (mm²) vs sham pooled from baseline to Month 24¹



SE in trials (monthly, EOM, sham pooled): OAKS: 0.15, 0.13, 0.14; DERBY: 0.13, 0.13, 0.17.

*Slope for baseline to Month 24 is an average of slope of baseline to Month 6, Month 6 to Month 12, Month 12 to Month 18, and Month 18 to Month 24.¹

Based on a mixed effects model for repeated measures assuming a piecewise linear trend in time with knots at Month 6, Month 12, and Month 18.¹

GA=geographic atrophy; SE=standard error.



Explore the long-term data

IMPORTANT SAFETY INFORMATION (CONT'D)

WARNINGS AND PRECAUTIONS (CONT'D)

- Intraocular Inflammation**

- In clinical trials, use of SYFOVRE was associated with episodes of intraocular inflammation including: vitritis, vitreal cells, iridocyclitis, uveitis, anterior chamber cells, iritis, and anterior chamber flare. After inflammation resolves, patients may resume treatment with SYFOVRE.

- Increased Intraocular Pressure**

- Acute increase in IOP may occur within minutes of any intravitreal injection, including with SYFOVRE. Perfusion of the optic nerve head should be monitored following the injection and managed as needed.

ADVERSE REACTIONS

- Most common adverse reactions (incidence $\geq 5\%$) are ocular discomfort, neovascular age-related macular degeneration, vitreous floaters, conjunctival hemorrhage.

Trial Design: SYFOVRE safety and efficacy were assessed in OAKS (N=637) and DERBY (N=621), multi-center, 24-month, Phase 3, randomized, double-masked trials. Patients with GA (atrophic nonexudative age-related macular degeneration), with or without subfoveal involvement, secondary to AMD were randomly assigned (2:2:1:1) to receive 15 mg/0.1 mL intravitreal SYFOVRE monthly, SYFOVRE EOM, sham monthly, or sham EOM for 24 months. Change from baseline in the total area of GA lesions in the study eye (mm²) was measured by fundus autofluorescence (FAF).^{1,4}

References: 1. SYFOVRE (pegcetacoplan injection) [package insert]. Waltham, MA: Apellis Pharmaceuticals, Inc.; 2023. 2. Pfau M, von der Emde L, de Sisternes L, et al. Progression of photoreceptor degeneration in geographic atrophy secondary to age-related macular degeneration. *JAMA Ophthalmol.* 2020;138(10):1026–1034. 3. Bird AC, Phillips RL, Hageman GS. Geographic atrophy: a histopathological assessment. *JAMA Ophthalmol.* 2014;132(3):338–345. 4. Data on file. Apellis Pharmaceuticals, Inc.

Please see Brief Summary of Prescribing Information for SYFOVRE on the adjacent page.

Apellis

APELLIS®, SYFOVRE® and their respective logos are registered trademarks of Apellis Pharmaceuticals, Inc.
©2024 Apellis Pharmaceuticals, Inc. 1/24 US-PEGGA-2200051 v3.0


INTERVENTIONAL GLAUCOMA SHATTERING THE STATUS QUO

Introducing

iDose[®] TR 
(travoprost intracameral
implant) 75 mcg

The catalyst to advance the interventional glaucoma revolution, helping you and your patients take back control of their treatment journey.

iDose TR is a long duration intracameral procedural pharmaceutical that delivers prostaglandin analog therapy for the reduction of intraocular pressure in patients with open-angle glaucoma or ocular hypertension.¹

 **Actual size**
1.8mm x 0.5mm

1. iDose TR (travoprost intracameral implant) 75 mcg Prescribing Information. Glaukos Corporation. 2023.

INDICATIONS AND USAGE

iDose TR (travoprost intracameral implant) is indicated for the reduction of intraocular pressure (IOP) in patients with open angle glaucoma (OAG) or ocular hypertension (OHT).

IMPORTANT SAFETY INFORMATION

DOSAGE AND ADMINISTRATION

For ophthalmic intracameral administration. The intracameral administration should be carried out under standard aseptic conditions.

CONTRAINDICATIONS

iDose TR is contraindicated in patients with active or suspected ocular or periocular infections, patients with corneal endothelial cell dystrophy (e.g., Fuch's Dystrophy, corneal guttatae), patients with prior corneal transplantation, or endothelial cell transplants (e.g., Descemet's Stripping Automated Endothelial Keratoplasty [DSAEK]), patients with hypersensitivity to travoprost or to any other components of the product.

WARNINGS AND PRECAUTIONS

iDose TR should be used with caution in patients with narrow angles or other angle abnormalities. Monitor patients routinely to confirm the location of the iDose TR at the site of administration. Increased pigmentation of the iris can occur. Iris pigmentation is likely to be permanent.

ADVERSE REACTIONS

In controlled studies, the most common ocular adverse reactions reported in 2% to 6% of patients were increases in intraocular pressure, iritis, dry eye, visual field defects, eye pain, ocular hyperaemia, and reduced visual acuity.

Please see full [Prescribing Information](#).

You are encouraged to report all side effects to the FDA. Visit www.fda.gov/medwatch, or call 1-800-FDA-1088.

You may also call Glaukos at 1-888-404-1644.

View full
prescribing
information at
iDoseTRhcp.com



GLAUKOS
TRANSFORMING VISION