

Wills Eye Resident Series: A patient presents with a suspicious conjunctival lesion, p. 69

# REVIEW<sup>®</sup> *of* OPHTHALMOLOGY

November 2024 • reviewofophthalmology.com

Clinical advice you can trust

## REFRACTIVE/CATARACT RUNDOWN

A Review of Rare Cataracts

PAGE 18

## PEDIATRIC PATIENT

Congenital Syphilis

PAGE 23

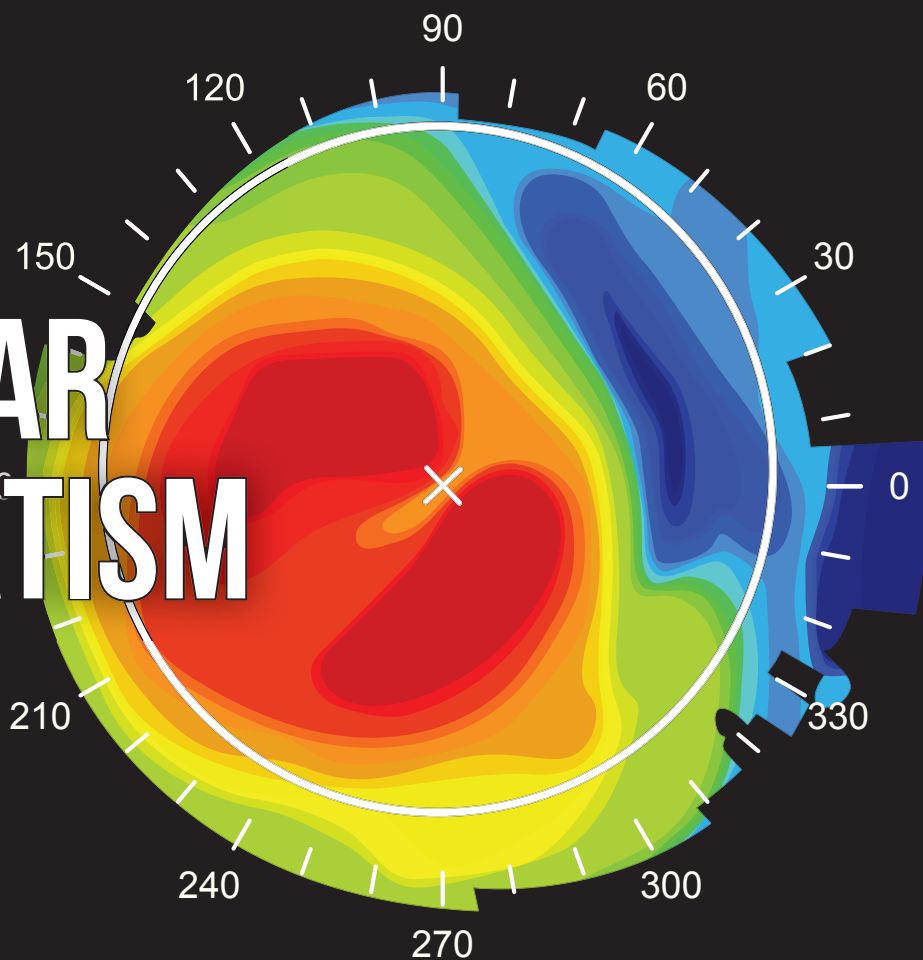
## RETINAL INSIDER

Radiation Retinopathy

PAGE 63

## HOW TO TACKLE IRREGULAR ASTIGMATISM

*What causes it and how to  
manage it. P. 34*



### Also inside

- The Endothelial Transplant Pipeline P. 31
- Plateau Iris and Angle-closure Management P. 39
- How to Manage Cross-linking Complications P. 46

# Experience the *Power of Direct* with Topcon

## BENEFITS

Consultative  
relationship  
with customized  
solutions



Responsive  
support from  
the device  
manufacturer



Factory-direct  
pricing and  
exclusive offers



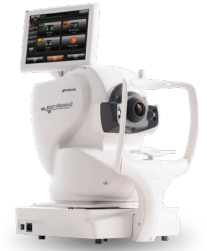**Topcon Healthcare is now  
a direct sales and service  
model in the United States.**  
Contact your local sales rep  
for more information.

## FEATURED PRODUCTS

### Maestro2 OCT

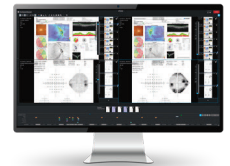#### NOW WITH OCTA!

Captures high-resolution  
macular and optic nerve  
scans in one sequence



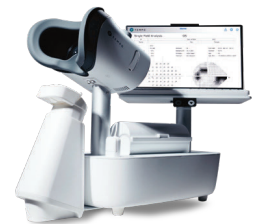### Harmony®

Organize all your  
ophthalmic clinical data  
within a single screen.



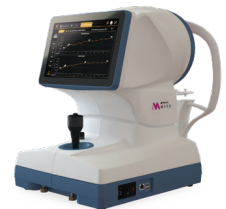### TEMPO™

The comfortable  
binocular perimeter that  
performs 39% faster than  
SAP<sup>1</sup>



### MYAH®

Build, manage, and grow  
your myopia  
management practice.



### Digital Lane

Differentiate your practice  
with digital refraction and  
a state-of-the-art  
instrument stand.



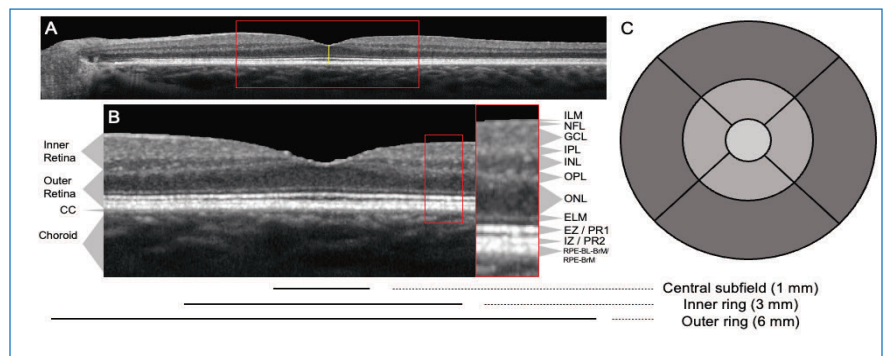
<sup>1</sup> Comparison between New Perimetry Device (IMOVifa®) and Humphrey Field Analyzer™ M Eslani, T Nishida, S Moghimi, JM Arias, C Vasile, V Mohammadzadeh, RN Weinreb; Invest. Ophthalmol. Vis. Sci. 2022;63(7):1272 – A0412.

## Thinning of Outer Retinal Layers Associated with Dementia

The incidence of Alzheimer's disease continues to grow exponentially, with some estimating it will affect more than 78 million people worldwide by 2030. However, imaging studies of brain aging have mostly been limited to neuroimaging, specifically MRI. Due to the cost associated with MRI, researchers have recognized retinal imaging to be a powerful, non-invasive and inexpensive way to study the brain via the eye. A new study in *American Journal of Ophthalmology* investigated how the outer retina in those with age-related macular degeneration would correlate with brain changes associated with Alzheimer's.<sup>1</sup> The findings, which surprised the study authors themselves, reveal that a thinner outer retina was associated with the brain regions involved in memory.

Participants with thinner outer retina had significantly smaller hippocampus ( $\beta=0.019$ ), lower occipital cortex regions of interest thickness ( $\beta=5.68$ ) and lower cortical thickness in Alzheimer's disease and related dementias ( $\beta=7.72$ ). Significantly lower occipital cortex regions of interest ( $\beta=3.19$ ) and dementia-related brain region ( $\beta=3.94$ ) thickness were associated with participants with thinner total retina.

In AMD, the outer retina is impacted significantly and early, but little is known about its association with cognition or changes in brain morphometry. The authors noted the novelty of their study as it included patients with early or intermediate AMD, as well as those



**A study in the *AJO* reports that thinner outer retinal thickness in the outer ETDRS ring is the most frequently reported variable that predicts lower brain measurements and is associated with atrophy in the of the brain regions involved in vision, memory and dementia.**

with normal retinal aging. "Limited literature exists on associations between neuroimaging and retinal imaging in older adults, particularly those with retinal diseases, such as AMD," they wrote. "As retinal diseases are highly prevalent in aging populations, studies that include people with retinal disease are critical for understanding aging eyes and brain connections. In addition, several epidemiologic studies have shown that many retinal diseases are associated with higher risks of developing ADRD."

The final cohort included 60 subjects (22 normal, 19 early AMD and 19 intermediate AMD) aged 70 to 87 (73 percent women). Seven participants were Black and the remainder were Caucasian. Linear regression was used to evaluate associations between retinal layer thickness measures (combined and averaged over central, inner, and outer ring) and dementia-related brain

regions. MRI measurements included: total brain, cortex, cerebral white matter, gray matter and hippocampus volume, as well as occipital cortex thickness and cortical thickness in ADRD-related brain regions.

In this study, thinner outer retinal thickness in the outer ETDRS ring was the most frequently reported variable that predicted lower brain measurements, and most associated with atrophy of the brain regions involved in vision, memory and dementia. Thinner outer retina was associated with thinning of occipital regions of interest, lower hippocampal volume and brain regions known to show early structural and functional changes in dementia.

The association of outer retinal thinning with brain regions vulnerable to dementia and areas primarily involved in memory "was somewhat surprising," the authors wrote in their paper. "It is

possible that this association is unique to participants with normal macular aging and early and intermediate AMD. We recently published that in this cohort, outer retinal thickness was the only retinal layer that was significantly associated with cognition in this group.”

Study co-author Cecilia Lee, MD, Klorfine Family Endowed Chair in Ophthalmology at the University of Washington, Seattle, says the study’s findings involving the outer retinal layer were surprising. “We wanted to look at what’s the earliest changes we could detect,” she says, “and we were surprised that it was the outer retina and not the retinal nerve fiber layer as we had anticipated based on the literature.”

In terms of what’s behind the association, Dr. Lee says there are a couple possibilities. “This population is very different,” she says. “A lot of previous studies have excluded patients with AMD or any retinal diseases, so this is a different pilot study in that it includes people with and without AMD. Also, it could be related to the fact that AMD is the disease of the RPE and outer retina, and the outer retina is the first layer or first retinal location implicated in the

early pathogenesis of AMD. So we’re not sure if it’s the early vascular disease that’s been picked up and there’s a thinning there. Also, we’re not really sure if it’s an AMD-related finding or if we’re following the normal aging population itself—these would be the first changes that we’d pick up in that case.

“If it’s actually the outer retinal layer, [that’s associated with brain atrophy] then that changes the focus of study,” Dr. Lee continues. “And if this is specific to the AMD population, that also changes everything because a lot of people are impacted by AMD.”

The authors point out that this pilot study, which had a small sample size, was meant to explore various relationships between retinal and brain health in people with early and intermediate AMD who are also at risk of developing age-related dementia. This “was not meant to study causal mechanisms,” they wrote. “Our study was not designed to investigate AD or any dementia specifically, and we used neuroimaging and cognitive proxy indicators of general brain health related to dementia. Thus, the generalizability of our results and hypothesized potential mechanisms

should be interpreted with caution.

“Despite these limitations, the primary aim of our study was to identify associations and to highlight the predictive value of retinal layer thickness for brain atrophy, rather than to determine the exact magnitude of the associations,” the authors continued in their *AJO* paper. “Future research with larger sample sizes and independent replication studies will be crucial to confirm these associations, in which we also suggest exploring other retinal layer thickness variables that are highly correlated with the ‘marker’ identified in this study.”

In conclusion, the study suggests that imaging, particularly of outer retinal thickness, could be a complementary tool in evaluating risks of cognitive decline in individuals with normal retina aging, as well as early and intermediate AMD, but that “further research is warranted to determine whether these findings are specific to the AMD population or could generalize to populations with retinal diseases.”

1. Jiang, Yu et al. Outer retinal thinning is associated with brain atrophy in early age-related macular degeneration. *American Journal of Ophthalmology*. Oct. 3, 2024. [Epub ahead of print.]

## Atrial Fibrillation’s Association with Visual Field Loss

Cardiac arrhythmias like atrial fibrillation (AFib) can lead to stroke, heart failure and even sudden death, but this condition can harm more than a patient’s heart. In the past, studies have found an association between atrial fibrillation and glaucoma, but these reports never examined the effects on the progression of glaucoma. Research conducted at the University of California, recently published in *Journal of Glaucoma*, elaborates on how atrial fibrillation impacts the visual field of glaucoma patients.<sup>1</sup>

Subjects had to be diagnosed with primary open-angle glaucoma but free of cardiac arrhythmia to be selected for this study. This allowed the researchers to measure a baseline visual

field. Then, patients were followed for approximately 15 years before the final results were analyzed. A total of 144 eyes from 105 patients were selected, then divided into two groups. Patients that developed AFib during the study period were categorized as cases; all others were used as controls. The cases consisted of 48 eyes and the controls consisted of 96 eyes.

All subjects had an average baseline visual field worsening of -0.20 dB/year; in cases that developed AFib, it was -0.28 dB/year after the event. Control subjects showed an insignificant difference after the follow-up period, reporting an average visual field of -0.21 dB/year.

Researchers also assessed everyone’s

scores on two common measures of stroke risk in AFib patients called CHADS<sub>2</sub> and CHA<sub>2</sub>DS<sub>2</sub>-VASc. These each assign point values based on the presence of various risk factors (e.g., congestive heart failure, hypertension, diabetes). Higher scores indicate greater risk of stroke. “In this retrospective cohort study, we found that the presence of atrial fibrillation, and both higher CHADS<sub>2</sub> and CHA<sub>2</sub>DS<sub>2</sub>-VASc score were associated with a small but significantly faster rate of visual field progression in patients with glaucoma,” stated the researchers in their study.

On average, AFib patients in the study lost -0.07 dB/year more of

(Continued on p. 12)

# TECNIS Odyssey™ IOL

Precise vision.  
Every distance.  
Any lighting.

Experience the new TECNIS™ Odyssey IOL, offering a high-quality, continuous full range of vision with an unparalleled combination of features: \*1-5

- Enhanced tolerance to refractive error†
- Optimized dysphotopsia profile†
- TECNIS™ best-in-class contrast§

LEARN MORE



\*Continuous 20/25 or better

†Compared to TECNIS Synergy™ based on bench-testing

§Compared to PanOptix® based on bench-testing

#### References:

1. Data on File. DOF2023CT4023
2. Data on File. 2024DOF4003
3. Data on File. 2024DOF4005

4. Data on File. DOF2023CT4007
5. Data on File. 2024DOF4033

#### INDICATIONS AND IMPORTANT SAFETY INFORMATION

Rx only. The TECNIS Odyssey™ IOL is indicated for primary implantation for the visual correction of aphakia in adult patients, with less than 1 diopter of pre-existing corneal astigmatism, in whom a cataractous lens has been removed. Patients should be informed of possible visual effects, which may be expected in nighttime or poor visibility conditions. Confirmation of refraction with maximum plus manifest refraction technique is strongly recommended. Patients with a predicted postoperative astigmatism greater than 1.0 D may not be suitable candidates for implantation with the TECNIS Odyssey™ IOLs and some patients may still require glasses. The lens is intended for capsular bag placement only. Please reference the Directions for Use for a complete listing of Indications and Important Safety Information.

**Johnson & Johnson**

Third party trademarks are the property of their respective owners.  
© Johnson & Johnson and its affiliates 2024 2024PP11319 v2

## CONTRIBUTORS

### CHIEF MEDICAL EDITOR

Mark H. Blecher, MD

### CONTACT LENSES

Penny Asbell, MD

### CORNEA / ANTERIOR SEGMENT

Thomas John, MD

### GLAUCOMA MANAGEMENT

Peter Netland, MD, PHD  
Kuldev Singh, MD

### MEDICARE Q & A

Mary Pat Johnson,  
COMT, CPC

### PEDIATRIC PATIENT

Janine Collinge, MD

### PLASTIC POINTERS

April Lao, MD

### REFRACTIVE SURGERY

Arturo S. Chayet, MD

### RETINAL INSIDER

Carl Regillo, MD, FACS  
Yoshihiro Yonekawa, MD

### TECHNOLOGY UPDATE

Steven T. Charles, MD  
Michael Colvard, MD

### WILLS RESIDENT CASE SERIES

Bonnie Sklar, MD

## ADVISORY BOARD

**PENNY A. ASBELL, MD**, MEMPHIS, TENN.

**BRANDON AYRES, MD**, PHILADELPHIA

**SURENDRA BASTI, MD**, CHICAGO

**WILLIAM I. BOND, MD**, PEKIN, ILL.

**ALAN N. CARLSON, MD**, DURHAM, N.C.

**Y. RALPH CHU, MD**, EDINA, MINN.

**ADAM J. COHEN, MD**, CHICAGO

**JANINE COLLINGE, MD**, FARMINGTON, CONN.

**UDAY DEVGAN, MD, FACS**, LOS ANGELES

**ERIC DONNENFELD, MD**, ROCKVILLE CENTRE, N.Y.

**DANIEL S. DURRIE, MD**, KANSAS CITY, MO.

**ROBERT EPSTEIN, MD**, MCHENRY, ILL.

**ROBERT D. FECHTNER, MD**, NEWARK, N.J.

**BRIAN FRANCIS, MD**, Los Angeles

**JAMES P. GILLS, MD**, TARPON SPRINGS, FLA.

**HARRY GRABOW, MD**, SARASOTA, FLA.

**DOUGLAS K. GRAYSON, MD**, NEW YORK CITY

**DAVID R. HARDTEN, MD**, MINNEAPOLIS

**SARA J. HAUG, MD, PHD**, DURANGO, COLO.

**KENNETH J. HOFFER, MD**, SANTA MONICA, CALIF.

**JACK T. HOLLADAY, MD, MSEE**, HOUSTON

**JOHN D. HUNKELER, MD**, KANSAS CITY, MO.

**THOMAS JOHN, MD**, TINLEY PARK, ILL.

**ROBERT M. KERSHNER, MD, MS**, PALM BEACH GARDENS, FLA.

**GUY M. KEZIRIAN, MD**, PARADISE VALLEY, ARIZ.

**SUMITRA KHANDLWAL, MD**, HOUSTON

**TERRY KIM, MD**, DURHAM, N.C.

**BRAD KLIGMAN, MD**, MANHASSET, N.Y.

**TOMMY KORN, MD**, SAN DIEGO

**APRIL LAO, MD**, MEMPHIS

**DAVID A. LEE, MD**, HOUSTON

**FRANCIS S. MAH, MD**, LA JOLLA, CALIF.

**NICK MAMALIS, MD**, SALT LAKE CITY

**EDWARD MANCHE, MD**, PALO ALTO, CALIF.

**MIKE S. MCFARLAND, MD**, PINE BLUFF, ARK.

**JEFFREY B. MORRIS, MD, MPH**, ENCINITAS, CALIF.

**KEVIN MILLER, MD**, LOS ANGELES

**MAJID MOSHIRFAR, MD**, DRAPER, UTAH

**MARLENE R. MOSTER, MD**, PHILADELPHIA

**ROBERT J. NOECKER, MD**, FAIRFIELD, CONN.

**ROBERT OSHER, MD**, CINCINNATI

**MARK PACKER, MD**, WEST PALM BEACH, FLA.

**CHRISTOPHER J. RAPUANO, MD**, PHILADELPHIA

**AUGUST READER III, MD**, SAN FRANCISCO

**TONY REALINI, MD, MPH**, MORGANTOWN, W.V.

**KENNETH J. ROSENTHAL, MD**, GREAT NECK, N.Y.

**ERIC ROTHCHILD, MD**, DELRAY BEACH, FLA.

**SHERI ROWEN, MD**, BALTIMORE

**INGRID U. SCOTT, MD, MPH**, HERSHEY, PA.

**JOEL SCHUMAN, MD**, PITTSBURGH

**GAURAV SHAH, MD**, ST. LOUIS

**DAVID R. STAGER JR., MD**, DALLAS

**KARL STONECIPHER, MD**, GREENSBORO, N.C.

**JAMES C. TSAI, MD**, NEW YORK CITY

**VANCE THOMPSON, MD**, SIOUX FALLS, S.D.

**FARRELL C. TYSON, MD**, CAPE CORAL, FLA.

**R. BRUCE WALLACE III, MD**, ALEXANDRIA, LA.



### BUSINESS OFFICES

19 CAMPUS BOULEVARD, SUITE 101  
NEWTOWN SQUARE, PA 19073  
SUBSCRIPTION INQUIRIES (877) 529-1746  
(USA ONLY); OUTSIDE USA, CALL (847) 763-9630

### BUSINESS STAFF

PUBLISHER

**MICHAEL HOSTER**

(610) 492-1028 MHOSTER@JOBSON.COM

SENIOR MANAGER, STRATEGIC ACCOUNTS

**MICHELE BARRETT**

(610) 492-1014 MBARRETT@JOBSON.COM

REGIONAL SALES MANAGER

**JONATHAN DARDINE**

(610) 492-1030 JDARDINE@JOBSON.COM

DIGITAL MARKETING MANAGER

**MATT EGGER**

(610) 492-1029 MEGGER@JOBSON.COM

CLASSIFIED ADVERTISING

(888)-498-1460

PRODUCTION MANAGER

**KAREN LALLONE**

(610) 492-1010 KLALLONE@JOBSON.COM

SUBSCRIPTIONS

\$63 A YEAR, \$99 (U.S.) IN CANADA,  
\$158 (U.S.) IN ALL OTHER COUNTRIES.

SUBSCRIPTIONS E-MAIL:

REVOPHTHALMOLOGY@CAMBEYWEST.COM

### CIRCULATION

PO BOX 71, CONGERS, NY 10920-0071

(877) 529-1746

OUTSIDE USA: (845) 267-3065

SENIOR CIRCULATION MANAGER

**HAMILTON MAHER**

(212) 219-7870 hmaher@jhihealth.com

CEO, INFORMATION GROUP SERVICES

**BILL SCOTT**

VICE PRESIDENT, CREATIVE SERVICES & PRODUCTION

**MONICA TETTAMANZI**

CREATIVE DIRECTOR

**LOUISE KOENIG**

DIRECTOR, PRODUCTION/MANUFACTURING

**REBECCA SLEBODNIK**

VICE PRESIDENT, HUMAN RESOURCES

**TAMMY GARCIA**

VICE PRESIDENT, CIRCULATION

**JARED SONNERS**

299 Market St. 2 Gateway Center - 4th Floor

Newark NJ 07102

# PAASS

## 3RD YEAR RESIDENT

# PROGRAM ON ADVANCED ANTERIOR SEGMENT SURGERY PROGRAM & WET LAB

**PROGRAM DATES**  
**JANUARY 17–18, 2025**  
(FRIDAY & SATURDAY)

### Didactic sessions

Pleasanton Marriott  
11950 Dublin Canyon Road  
Pleasanton, California 94588

### Wet Labs

Zeiss Innovation Center  
5300 Central Pkwy  
Dublin, California 94568

**Yousuf Khalifa, MD**  
**Madeline Yung, MD**

Course Co-Directors

### Program Highlights Include

- Intimate meeting (limited to the first 28 residents registered)
- Hands-on wet lab
- Refractive Surgery (LASIK, PRK (refract lenticule extraction)
- MIGs
- Yamane technique
- Capsular Tension Segments
- Complex/dense cataract mgmt

Dear Resident Program Director and Coordinator,

We are excited to announce the upcoming CME Accredited Resident Wet Lab Program on Advanced Anterior Segment Surgery (PAASS). PAASS is an intimate meeting (limited to the first 28 residents registered maximum) designed to help prepare third-year ophthalmology residents to transition successfully into a private practice setting in ophthalmology or their chosen fellowship program, or into an educational environment. The 3rd Year PAASS & Wet Lab will be approved for *AMA PRA Category 1 Credits™* and will have an emphasis on successful outcomes by concentrating on building diagnostic, medical and advanced surgical skills in the wet lab (including Yamane, Capsular Tension Segments, MIGs, etc). The course directors and the faculty create a “safe” environment, so the third-year residents feel comfortable discussing questions, new technology, and complications in an atmosphere that strongly encourages interactive participation. **We are capping the number of residents to 28 so that the residents are fully immersed in the learning environment along with a one-to-one (faculty-to-resident) ratio in the wet lab to maximize learning curve with the advanced surgical skills wet lab.**

Ophthalmology residencies in the United States strive to introduce their residents to advanced surgical techniques and technologies in an environment characterized by rapid innovation. Due to continuously evolving technological developments, best practices are constantly changing. As such, there are too few opportunities to gain hands-on training. This meeting will concentrate on advanced techniques and technologies geared towards residents approaching the end of their 3rd Year (PGY4) residency. The meeting will cover topics specifically in the areas of refractive surgery, minimally invasive glaucoma surgery, management of aphakia, new technologies for dense cataract management, intraocular lens selection technologies, heads-up displays, and progression tracking software.

This 2-day course will include one day of didactic and one day of hands-on wet lab experience. The meeting will be led by a faculty comprised of renowned key opinion leaders and specialized surgeons with a background in resident education. The wet lab will feature nationally recognized leaders with one-on-one wet lab mentorship.

We believe this program offers a unique opportunity for residents to gain hands-on experience on advanced anterior segment surgery techniques. We hope that you will select and encourage your 3rd-year residents (PGY-4) to attend this CME accredited program.

Sincerely,

Yousuf M. Khalifa, MD, and Madeline Yung, MD

**REGISTRATION IS OPEN NOW at [www.ReviewEdu.com/PAASS2025](http://www.ReviewEdu.com/PAASS2025)**



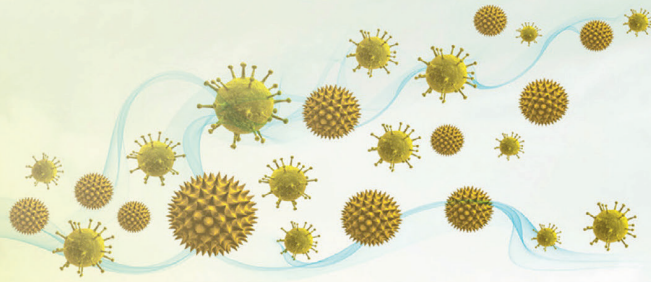

**Joint Accreditation Statement** – In support of improving patient care, this activity has been planned and implemented by Amedco LLC and Review Education Group. Amedco LLC is jointly accredited by the Accreditation Council for Continuing Medical Education (ACCME), the Accreditation Council for Pharmacy Education (ACPE), and the American Nurses Credentialing Center (ANCC), to provide continuing education for the healthcare team. Amedco Joint Accreditation #4008163.

**Physicians (ACCME) Credit Designation** – This activity has been approved for *AMA PRA Category 1 Credits™*

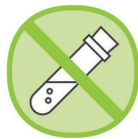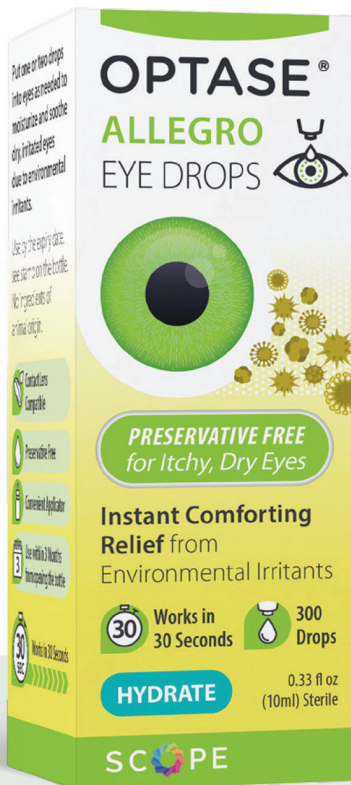For more information visit the registration site above or email Denette Holmes  
at [dholmes@postgradhealthed.com](mailto:dholmes@postgradhealthed.com) or call 866-627-0714

# OPTASE<sup>®</sup>

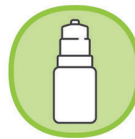## ALLEGRO EYE DROPS



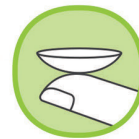A **Fast Acting,** Preservative & Drug Free Dry Eye drop that provides a **First Line of Defense** against **Environmental Irritants**



Preservative and Phosphate Free



Convenient Multi Dose Bottle



Contact Lens Compatible



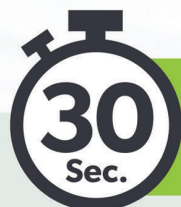Suitable for all ages



Suitable in Pregnancy



Drug Free



Reduction of Itchy dry eye symptoms in 30 seconds

For more information or samples visit [OPTASE.com](http://OPTASE.com) or email [hello@optase.com](mailto:hello@optase.com)

SCOPE



# FEATURES

Vol. XXXI, No. 11 • November 2024

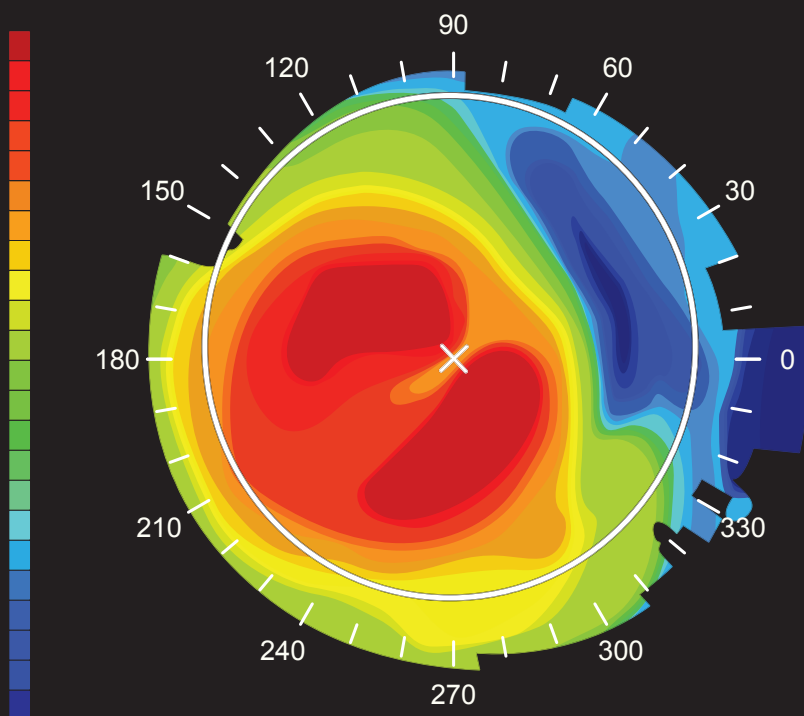
**Catch Up on the Latest News**  
Read *Review's* weekly newsletter  
online at [reviewofophthalmology.com](http://reviewofophthalmology.com).

## 34

### Managing Irregular Astigmatism

An etiology-based approach is key when addressing this complex refractive situation.

*Christine Yue Leonard, Senior Associate Editor*



## 31

### Transplant Techniques in The Pipeline

In addition to benefiting U.S. patients, these new techniques would address tissue shortages.

*Michelle Stephenson*  
*Contributing Editor*

## 39

### Plateau Iris and Angle Closure Management

Experts offer their perspectives on how to approach narrow angles and plateau iris configuration to mitigate glaucoma risk.

*Liz Hunter*  
*Senior Editor*

## 46

### Managing Complications After Cross-linking

Although rare, patients may experience issues following treatment for keratoconus and other corneal conditions.

*Andrew Beers*  
*Associate Editor*

# DEPARTMENTS

November 2024

## 3 News

## 14

EDITOR'S PAGE

### Reimbursements Are Out of Step with Reality

Walter Bethke  
Editor in Chief

## 17

THE FORUM

### All for One, and One for All

Musings on life, medicine and the practice of ophthalmology.

Mark H. Blecher, MD  
Chief Medical Editor

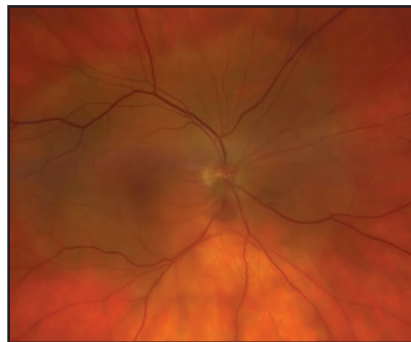## 18

REFRACTIVE/CATARACT RUNDOWN

### Rare Cataract Reminders

Tips for approaching the challenging cases that aren't seen too often.

Liz Hunter  
Senior Editor



## 23

PEDIATRIC PATIENT

### Ocular Manifestations Of Congenital Syphilis

Experts describe the increasing prevalence of this disease and dive into signs beyond Hutchinson's triad.

Linus Park, BA, Sang Nguyen, BS, and Tammy Yanovitch, MD, MHSc

## 43

AD INDEX

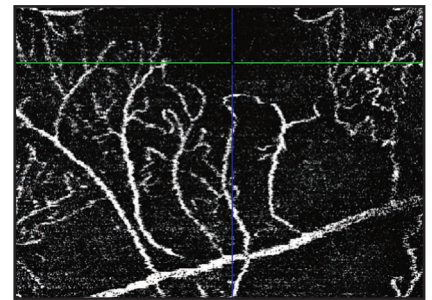
## 57

GLAUCOMA MANAGEMENT

### Intraocular Tumors And Glaucoma

Benign or malignant, a tumor in the eye can lead to rising pressures and difficult-to-treat glaucoma.

Carol L. Shields, MD



## 63

RETINAL INSIDER

### An Update on Radiation Retinopathy

An expert look at risk factors, diagnosis and which treatment methods work best in various patient presentations.

Jenna Krivit, BA, Antonio Yaghy, MD, and Lauren A. Dalvin, MD

## 69

WILLS EYE RESIDENT CASE SERIES

### A 64-year-old man was referred to Wills Eye Hospital for a suspicious conjunctival lesion in his left eye.

Thomas M. Catapano, BS, Eric B. Lee, MD, Tatyana Milman, MD, Carol L. Shields, MD



VISIT US ON SOCIAL MEDIA

Facebook

facebook.com/RevOphth

twitter/X

twitter.com/RevOphth

Instagram

@revophth



xdemvy®  
(lotilaner ophthalmic  
solution) 0.25%

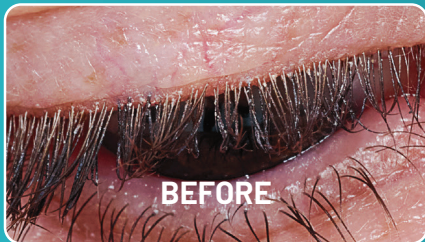This is not the actual product. It is a depiction of the product for dramatic purposes.



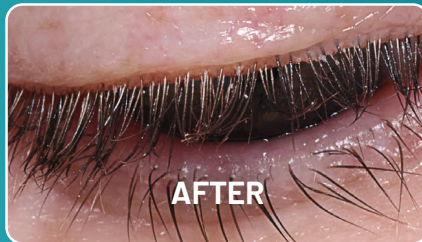# XDEMZY.

## Easy on eyelids. Tough on mites.

### Real XDEMZY results



BEFORE



AFTER

Abby, real patient with **Demodex blepharitis (DB)**. Results after 6 full weeks of treatment. Results may vary.



Learn more at  
[XDEMZYHCP.com](https://XDEMZYHCP.com)

44% and 55% of patients taking XDEMZY in SATURN-1 (N=209) and SATURN-2 (N=193), respectively, achieved a significant improvement in their eyelids (reduction of collarettes to no more than 2 collarettes per upper lid) at Day 43 vs 7% (N=204) and 12% (N=200) of patients taking vehicle (P<0.01 in each trial).\*

### INDICATIONS AND USAGE

XDEMZY (lotilaner ophthalmic solution) 0.25% is indicated for the treatment of *Demodex* blepharitis.

### IMPORTANT SAFETY INFORMATION:

#### WARNINGS AND PRECAUTIONS

**Risk of Contamination:** Do not allow the tip of the dispensing container to contact the eye, surrounding structures, fingers, or any other surface in order to minimize contamination of the solution. Serious damage to the eye and subsequent loss of vision may result from using contaminated solutions.

**Use with Contact Lenses:** XDEMZY contains potassium sorbate, which may discolor soft contact lenses. Contact lenses should be removed prior to instillation of XDEMZY and may be reinserted 15 minutes following its administration.

**ADVERSE REACTIONS:** The most common adverse reaction with XDEMZY was instillation site stinging and burning which was reported in 10% of patients. Other ocular adverse reactions reported in less than 2% of patients were chalazion/hordeolum and punctate keratitis.

Please see next page for a Brief Summary of the full Prescribing Information.

\*The safety and efficacy of XDEMZY for the treatment of DB were evaluated in a total of 833 patients (415 of whom received XDEMZY) in two 6-week, randomized, multicenter, double-masked, vehicle-controlled studies (SATURN-1 and SATURN-2). Patients were randomized to either XDEMZY or vehicle at a 1:1 ratio, dosed twice daily in each eye for 6 weeks. All patients enrolled were diagnosed with DB. The primary efficacy endpoint was defined as the proportion of patients with collarette reduction to no more than 2 collarettes per upper eyelid at Day 43.

Reference: XDEMZY [prescribing information]. Tarsus Pharmaceuticals, Inc; 2023.

© 2024 Tarsus Pharmaceuticals, Inc. All rights reserved.  
Tarsus, XDEMZY, and the associated logos are registered trademarks of Tarsus Pharmaceuticals, Inc. US--2400237 6/24



**XDEMYV® (lotilaner ophthalmic solution) 0.25%, for topical ophthalmic use**

**BRIEF SUMMARY OF PRESCRIBING INFORMATION**

Please see the XDEMYV® package insert for full Prescribing Information.

**INDICATIONS AND USAGE**

XDEMYV is indicated for the treatment of Demodex blepharitis.

**CONTRAINDICATIONS**

None.

**WARNINGS AND PRECAUTIONS**

**Risk of Contamination** Do not allow the tip of the dispensing container to contact the eye, surrounding structures, fingers, or any other surface in order to minimize contamination of the solution. Serious damage to the eye and subsequent loss of vision may result from using contaminated solutions.

**Use with Contact Lenses** Contact lenses should be removed prior to instillation of XDEMYV and may be reinserted 15 minutes following its administration.

**ADVERSE REACTIONS**

Because clinical studies are conducted under widely varying conditions, adverse reaction rates observed in the clinical trials of a drug cannot be directly compared to rates in the clinical trials of another drug and may not reflect the rates observed in practice.

XDEMYV was evaluated in 833 patients with Demodex blepharitis in two randomized, double-masked, vehicle-controlled studies (Saturn-1 and Saturn-2) with 42 days of treatment. The most common ocular adverse reaction observed in controlled clinical studies with XDEMYV was instillation site stinging and burning which was reported in 10% of patients. Other ocular adverse reactions reported in less than 2% of patients were chalazion/hordeolum and punctate keratitis.

**USE IN SPECIFIC POPULATIONS**

**Pregnancy: Risk Summary** There are no available data on XDEMYV use in pregnant women to inform any drug associated risk; however, systemic exposure to lotilaner from ocular administration is low. In animal reproduction studies, lotilaner did not produce malformations at clinically relevant doses.

**Data Animal Data** In an oral embryofetal developmental study in pregnant rats dosed during organogenesis from gestation days 6-19, increased post-implantation loss, reduced fetal pup weight, and incomplete skeletal ossification were observed at 50 mg/kg/day (approximately 1390 times the recommended human ophthalmic dose (RHOD) on a body surface area basis) in the presence of maternal toxicity (i.e., decreased body weight and food consumption). A rare malformation of situs inversus of the thoracic and abdominal viscera occurred in 1 fetus from a pregnant rat receiving 50 mg/kg/day; whether this finding was treatment-related could not be excluded. No maternal or embryofetal toxicity was observed at 18 mg/kg/day (approximately 501 times the RHOD on a body surface area basis). In an oral embryofetal development study in pregnant rabbits dosed during organogenesis from gestation days 7-19, no embryofetal toxicity or teratogenic findings were observed at 20 mg/kg/day (approximately 580-times the RHOD on an AUC basis), even in the presence of maternal toxicity (i.e., decreased food consumption and body weight).

In an oral two-generation reproductive toxicity study, F0 male and female rats were administered lotilaner at doses up to 40 mg/kg/day for 10 weeks before pairing and during the 2-week pairing period (3 weeks for males). Dosing for F0 females continued through lactation day 22. F1 male and female rats were administered lotilaner at 1 and 5 mg/kg/day post-weaning from day 23 for 10 weeks before pairing and during the 2-week pairing period (3 weeks for males). Dosing for F1 parenteral females continued through lactation day 22. There were no clear adverse effects on the F1 generation, and a slightly lower mean body weight during lactation was noted for F2 pups at 5 mg/kg/day. The observed adverse effect level (NOAEL) was determined to be 5 mg/kg/day

(approximately 139 times the RHOD on a body surface area basis).

**Lactation: Risk Summary** There are no data on the presence of XDEMYV in human milk, the effects on the breastfed infant, or the effects on milk production. However, systemic exposure to lotilaner following 6 weeks of topical ocular administration is low and is >99% plasma protein bound, thus it is not known whether measurable levels of lotilaner would be present in maternal milk following topical ocular administration. The developmental and health benefits of breastfeeding should be considered along with the mother's clinical need for XDEMYV and any potential adverse effects on the breast-fed child from XDEMYV.

**Pediatric Use:** Safety and effectiveness in pediatric patients below the age of 18 years have not been established.

**Geriatric Use:** No overall differences in safety or effectiveness have been observed between elderly and other adult patients.

**NONCLINICAL TOXICOLOGY**

**Carcinogenesis, Mutagenesis, Impairment of Fertility**

**Carcinogenesis** Long-term studies in animals have not been performed to evaluate the carcinogenic potential of lotilaner.

**Mutagenesis** Lotilaner was not genotoxic in the following assays: Ames assay for bacterial gene mutation, *in vitro* chromosomal aberration assay in cultured human peripheral blood lymphocytes, and *in vivo* rat micronucleus test.

**Impairment of fertility** In a two-generation study of reproductive performance in rats, F0 male and female rats were administered lotilaner at oral doses of 40 mg/kg/day for 80 days reduced to 20 mg/kg/day for 47-50 supplementary days. Reduced pregnancy rates and decreased implantation rates were observed in F0 females at doses 20 mg/kg/day (approximately 556 times the RHOD on a body surface area basis), which were also associated with maternal toxicity (i.e., decreased body weight and food consumption). No effects on fertility were observed in F0 females at the dose of 5 mg/kg/day (approximately 139 times the RHOD on a body surface area basis). No effects on fertility were observed in F0 males at the oral dose of 20 mg/kg/day (approximately 556 times the RHOD on a body surface area basis), and no effects on fertility were observed in F1 males and females at the oral dose of 5 mg/kg/day (approximately 139 times the RHOD on a body surface area basis).

**PATIENT COUNSELING INFORMATION**

**Handling the Container** Instruct patients to avoid allowing the tip of the dispensing container to contact the eye, surrounding structures, fingers, or any other surface in order to minimize contamination of the solution. Serious damage to the eye and subsequent loss of vision may result from using contaminated solutions.

**When to Seek Physician Advice**

Advise patients that if they develop an intercurrent ocular condition (e.g., trauma or infection), have ocular surgery, or develop any ocular reactions, particularly conjunctivitis and eyelid reactions, they should immediately seek their physician's advice concerning the continued use of XDEMYV.

**Use with Contact Lenses** Advise patients that XDEMYV contains potassium sorbate, which may discolor soft contact lenses. Contact lenses should be removed prior to instillation of XDEMYV and may be reinserted 15 minutes following its administration.

**Use with Other Ophthalmic Drugs** Advise patients that if more than one topical ophthalmic drug is being used, the drugs should be administered at least 5 minutes between applications.

**Missed Dose** Advise patients that if one dose is missed, treatment should continue with the next dose.

RX only

© 2024 Tarsus Pharmaceuticals, Inc. All rights reserved.

XDEMYV is a registered trademark of Tarsus Pharmaceuticals, Inc.

US-2300345 1/24

**REVIEW NEWS**

(Continued from p. 4)

their visual field for every unit of their CHADS<sub>2</sub> score. So, a CHADS<sub>2</sub> score of 0 would correspond with approximately -0.07 dB/year, while a score of 5 was measured at about -0.42 dB/year. This same principle was used when analyzing CHA<sub>2</sub>DS<sub>2</sub>-VASc scores, except the average visual field loss in correlation with this score was measured at -0.05 dB/year.

“Our findings may indicate that the presence of atrial fibrillation and related microvascular damage are associated with a faster visual field loss in patients with glaucoma, suggesting that impaired circulation has a role in glaucoma progression,” concluded the researchers in their paper on this study. “Our study underscores the need for comprehensive medical history assessment and the management of cardiovascular risk factors to mitigate the risk of fast disease progression.”

1. Nishida T, Moghimi S, Jin W, et al. Rates of visual field progression before and after the onset of atrial fibrillation. *J Glaucoma*. September 25, 2024. [Epub ahead of print].

## AAO Report: Intraoperative Aberrometry vs. Biometry

American Academy of Ophthalmology researchers evaluated the published literature to compare intraoperative aberrometry (IA) with preoperative biometry-based formulas with respect to intraocular lens power calculation accuracy for various clinical scenarios.

Literature searches in the PubMed database conducted in August 2022, July 2023 and February 2024 identified 157, 18 and six citations, respectively. These were reviewed in abstract form, and 61 articles were selected for full-text review. Of these, 29 met the criteria for inclusion in this assessment. The panel methodologists assigned a level of evidence rating to each of the articles; four were rated level I, 19 were rated level II and six were rated level III.

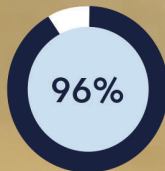Here are some of the findings:

- Intraoperative aberrometry performed better than traditional vergence formulas, including the Haigis, HofferQ, Holladay and SRK/T; it performed similarly to the Barrett Universal II and Hill-RBF with respect to minimization of spherical equivalent refractive error.
- For toric IOLs, IA outperformed formulas that only consider anterior corneal astigmatism and was similar to formulas like the Barrett Toric Calculator (BTC), which empirically account for the contribution from the posterior cornea.
- In eyes with a history of corneal refractive surgery, IA performed similarly to the Barrett True-K and slightly better than other tested methods, including the Haigis-L, Shammas and Wang-Koch-Maloney formulas.

(Continued on p. 16)

# Help your patients see the world again.

IMPROVED  
QUALITY OF LIFE



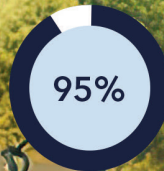
of patients reported improved quality of life with PROSE

IMPROVED  
VISION



of patients reported improved vision with PROSE

IMPROVED  
EYE HEALTH



of patients reported improved eye health with PROSE

Yet 62% of patients waited 3+ years for a PROSE referral.

## WHY WAIT?

PROSE® (prosthetic replacement of the ocular surface ecosystem) is a treatment pioneered by BostonSight. For thousands of patients suffering from the most complex ocular surface diseases, including keratoconus, dry eye disease, ocular GVHD, and corneal transplant complications, PROSE is often the ideal, and sometimes only, treatment capable of restoring visual function and reducing eye pain and light sensitivity, and all without surgery.



**PROSE**  
by BOSTONSIGHT®

[www.bostonsight.org/practitioners](http://www.bostonsight.org/practitioners)

PROSE is a registered trademark of BostonSight. Patients referred for PROSE treatment must have tried and been unsuccessful with RGP and scleral lenses before consideration for PROSE treatment. Statistics are based on percent of respondents in a survey to 2,000 PROSE patients in 2024.

©Copyright 2024 BostonSight.





## EDITORIAL STAFF

**Editor in Chief**  
**Walter Bethke**

(610) 492-1024  
wbethke@jobson.com

**Senior Editor**  
**Liz Hunter**

(610) 492-1025  
ehunter@jobson.com

**Senior Associate Editor**  
**Christine Leonard**

(610) 492-1008  
cleonard@jobson.com

**Associate Editor**  
**Leanne Spiegle**

(610) 492-1026  
lspiegle@jobson.com

**Associate Editor**  
**Andrew Beers**

(570) 856-5156  
abeers@jobson.com

**Chief Medical Editor**  
**Mark H. Blecher, MD**

**Art Director**  
**Lynne O'Connor**

(267) 566-6007  
lyoconnor@jobson.com

**Graphic Designer**  
**Jaine Kopala**

(609) 969-0694  
jkopala@jobson.com

### Business Offices

19 Campus Boulevard, Suite 101  
Newtown Square, PA 19073  
(610) 492-1000  
Fax: (610) 492-1039

### Subscription inquiries:

United States — (877) 529-1746  
Outside U.S. — (845) 267-3065  
E-mail:

revophthalmology@cambeywest.com  
Website: www.reviewofophthalmology.com



# Reimbursements Are Out Of Step with Reality

**H**istory has many instances in which an idea seemed logical and beneficial on paper but failed spectacularly when put into practice.

One famous example of this is Prohibition in the United States. On the surface, the idea of curbing the availability of “demon rum” would lead to a more stable, law-abiding society. But when Prohibition went into effect, it had almost the exact opposite effect: it led to a huge increase in organized crime as criminals profited off of the illegal production and distribution of alcohol; many citizens started drinking homemade alcohol, leading to a rise in cases of alcohol poisoning; corruption in law enforcement increased; and the alcohol industry was severely damaged, leading to mass layoffs and depriving the government of tax revenue from alcohol sales, which wound up stinging even more during the Great Depression.<sup>1</sup>

Similarly, the blind allegiance health insurers have for “step therapy” is an idea that seems useful on the surface but, as was pointed out at the 2024 American Academy of Ophthalmology meeting during a presentation on physician reimbursement, is actually counterproductive.

In the presentation, New Jersey retina specialist and chair of the American Society of Retina Specialists’ Research and Safety in Therapeutics Committee, Paul Hahn, outlined how step therapy misses the mark.

In the context of retina care, step therapy involves starting a patient with diabetic macular edema on the lower-cost Avastin first, followed by a switch to Eylea due to lack of response. The idea, of course, is to try to save money by using the cheaper option initially, and Protocol AC from the Diabetic Retinopathy Clinical Research network

seemed to bear that out.<sup>2</sup> However, as Dr. Hahn pointed out, that’s not what actually happens, since he notes that Protocol AC used treatment regimens that exceed real-world utilization.

In Dr. Hahn’s presentation, he describes a cost-effectiveness analysis he co-authored that identified “40 percent greater direct medical cost in the Protocol AC bevacizumab-first arm compared to real-world treatment over two years. Although clinical trial vision outcomes were greater, a subcohort of real-world patients whose vision outcomes were matched still demonstrated 19 percent lower cost.”<sup>3</sup> They also found that, when societal costs were analyzed, the step therapy used in Protocol AC would result in 25 percent greater costs.

At the podium, Dr. Hahn said that if these differences were applied to the 1.1 million patients with DME in the U.S., the additional societal costs associated with Protocol AC Avastin-first treatment would total \$12 billion over two-years compared to real-world regimens.

Dr. Hahn’s ultimate point is that physicians should be allowed to use whichever drug they feel is appropriate for a particular patient presentation, rather than have an insurance company dictate their choice. This not only results in better patient care, but it actually saves money too—an idea that works on paper, and also in practice.

— *Walter Bethke*  
*Editor in Chief*

1. Okrent, Daniel. Last Call: The Rise and Fall of Prohibition. Scribner, 2010.  
2. Jhaveri CD, Glassman AR, Ferris FL, et al. Aflibercept monotherapy versus bevacizumab-first for diabetic macular edema. N Engl J Med. 2022; 387(8):692-703.  
3. Grewal DS, Leung EH, Busquets M, et al. Bevacizumab-first in DRCR Protocol AC versus real-world physician treatment choice for diabetic macular edema: A two year cost analysis. J Vitreoretin Dis 2024. In press.



ASCEND™ Technology



LenSx® Laser, featuring  
ASCEND™ Technology


# Take the first step in creating reproducible surgical outcomes.

Bring **proven precision and safety** to every cataract procedure with the LenSx® Laser, featuring ASCEND™ Technology — it's **the only femtosecond platform** to be **trusted in more than 3 million procedures and counting.**<sup>1-13</sup>

Talk to your local Alcon representative about how you can take the next step forward.

Please see next page for Important Product Information and supporting references.

© 2022 Alcon Inc. US-LSX-2200005



**Alcon**  
Vision Suite

## LenSx® Laser Important Product Information for Cataract Surgery, Corneal Flap and Corneal Pockets & Tunnel Incisions

### Caution

Federal Law restricts this device to sale and use by or on the order of a physician or licensed eye care practitioner.

### INDICATIONS FOR THE LENSX® LASER:

#### Cataract Surgery Indication

In the creation of corneal cuts/incisions (single-plane, multi-plane and arcuate) anterior capsulotomy and laser phacofragmentation during cataract surgery in adult patients. Each of these procedures may be performed either individually or consecutively during the same surgery.

#### Corneal Flap Indication

For use in the creation of a corneal flap in adult patients undergoing LASIK surgery or other treatment requiring initial lamellar resection of the cornea.

#### Corneal Pockets and Tunnels

In adult patients, for the creation of corneal pockets for placement/insertion of a corneal inlay device; and for creation of corneal tunnels for the placement of corneal rings

#### Restrictions

- Patients must be able to lie flat and motionless in a supine position.
- Patient must be able to understand and give an informed consent.
- Patients must be able to tolerate local or topical anesthesia.
- Patients with elevated IOP should use topical steroids only under close medical supervision.

### CONTRAINDICATIONS

#### Cataract Surgery Contraindications

- Corneal disease that precludes appplanation of the cornea or transmission of laser light at 1030 nm wavelength
- Descemetocoele with impending corneal rupture
- Presence of blood or other material in the anterior chamber
- Poorly dilating pupil, such that the iris is not peripheral to the intended diameter for the capsulotomy
- Conditions which would cause inadequate clearance between the intended capsulotomy depth and the endothelium (applicable to capsulotomy only)
- Previous corneal incisions that might provide a potential space into which the gas produced by the procedure can escape
- Corneal thickness requirements that are beyond the range of the system
- Corneal opacity that would interfere with the laser beam
- Hypotony, glaucoma\* or the presence of a corneal implant
- Residual, recurrent, active ocular or eyelid disease, including any corneal abnormality (for example, recurrent corneal erosion, severe basement membrane disease)
- History of lens or zonular instability
- Any contraindication to cataract or keratoplasty
- This device is not intended for use in pediatric surgery.

\*Glaucoma is not a contraindication when these procedures are performed using the LenSx® Laser SoftFit® Patient Interface Accessory

### Corneal Surgery (Flaps, Pockets, Tunnels)

#### Contraindications

- Corneal lesions
- Corneal edema
- Hypotony
- Glaucoma
- Existing corneal implant
- Keratoconus
- This device is not intended for use in pediatric surgery.
- Flap creation, tunnels, pockets and cataract procedures cannot be combined into a single treatment.

#### WARNINGS

The LenSx® Laser System should only be operated by a physician trained in its use. The LenSx® Laser delivery system employs one sterile disposable Patient Interface consisting of an appplanation lens and suction ring. The Patient Interface is intended for single use only. Use of disposables other than those manufactured by Alcon may affect system performance and create potential hazards.

#### Precautions

- Do not use cell phones or pagers of any kind in the same room as the LenSx® Laser.
- Discard used Patient Interfaces as medical waste.

#### COMPLICATIONS

#### Cataract Surgery AEs/Complications

- Corneal edema
- Capsulotomy, phacofragmentation, or cut or incision decentration
- Incomplete or interrupted capsulotomy, fragmentation, or corneal incision procedure
- Capsular tear
- Corneal abrasion or defect
- Pain
- Infection
- Bleeding
- Damage to intraocular structures
- Anterior chamber fluid leakage, anterior chamber collapse
- Elevated pressure to the eye

#### Corneal Surgery (Flaps, Pockets & Tunnels) AEs/Complications

- Corneal edema
- Corneal or eye pain
- Corneal haze
- Epithelial in-growth
- Corneal abrasion or epithelial defect
- Infection/keratitis
- Corneal ectasia or endothelial perforation
- Decentered flap or pattern; uneven flap bed
- Incomplete dissection/inability to complete procedure
- Flap tearing or incomplete lift-off
- Free cap or buttonhole
- Elevated pressure to the eye

#### Attention

Refer to the LenSx® Laser Operator's Manual for a complete listing of indications, warnings and precautions.

## REVIEW NEWS

(Continued from p. 12)

Scientists concluded that intraoperative aberrometry corresponded well with modern vergence formulas, including the Barrett Universal II, Hill-RBF, BTC and Barrett True-K. It had greater accuracy than traditional vergence-based intraocular lens power calculation formulas in eyes with and without a history of corneal refractive surgery. ◀

1. Pantanelli SM, Hatch K, Lin CC, et al. Intraoperative aberrometry versus preoperative biometry for intraocular lens power calculations: A Report by the American Academy of Ophthalmology. *Ophthalmology* 2024; Oct 3. [Epub ahead of print].

## INDUSTRY NEWS

### B+L Envy IOL Approved

Bausch + Lomb announced the FDA approved the enVista Envy intraocular lens, which the company says offers a continuous range of vision with excellent dysphotopsia tolerance. A multicenter, randomized and controlled clinical trial evaluating 332 subjects demonstrated excellent long-term outcomes with the enVista Envy IOL in the United States, the company reports. The company says Envy also enables surgeons to treat a wider range of astigmatic patients with more accuracy and precision with 0.5-D steps (or less) throughout the cylinder range.

### Johnson & Johnson Expands Odyssey Introduction

Johnson & Johnson is expanding the rollout of its latest presbyopia-correcting intraocular lens, the Tecnis Odyssey, in the United States. The company says the new IOL offers patients "continuous full range of vision" so they can see clearly from far to near and in between, minimizing their need for glasses. The IOL is built on the Tecnis platform, providing increased contrast in low lighting, J&J says.

### Spectralis Flex Module Gets Approval

Heidelberg Engineering announced FDA clearance for the Spectralis Flex Module, a diagnostic imaging-only platform designed for imaging the posterior segment of pediatric and adult patients in a supine position. The Flex Module mounts the OCT device to a movable stand with an articulated adjustable arm, offering flexibility that extends imaging capabilities to various positions and acquisition environments, the company says.

### New Issue of Video Journal Released

The third issue of the *Video Journal of Cataract, Refractive, & Glaucoma Surgery*, curated by Cincinnati surgeon Robert Osher and titled "A Treasure Chest of Surgical Pearls," is available. View the Video Journal online at <https://vjcrs.com/>.

### Topcon and Microsoft Partner for AI Initiative

Topcon Healthcare announced a partnership with Microsoft to deliver AI-powered "Healthcare from the Eye" solutions to improve health care access, cost and quality. A cloud-based connected network of health-care providers using the Nuance Precision Imaging Network and the Topcon Harmony platform will enable patients and providers to participate in pre-screening for systemic and neurological disease via a robotic, rapid, and non-invasive eye scan, the company says. A key element of this effort is Harmony, a vendor-inclusive, secure, connected data management platform, according to Topcon officials.

### Keeler Launches Online Forum

Keeler launched an online educational support platform featuring videos, an image gallery, a clinical education and student blog, and access to an educational events calendar. You can view the educational platform at <https://resourcehub.keelerglobal.com/>.

**References:** 1. Alcon Data on File. 2. Alcon Data on File, 2022. 3. Kohnen T, Mathys L, Petermann K, et al. Update on the comparison of femtosecond laser-assisted lens surgery to conventional cataract surgery: a systematic review and meta-analysis. Paper presented at: ESCRS; October 7-11, 2017; Lisbon, Portugal. 4. Kranitz K, Mihaltz K, Sandor GL, Takacs A, Knorz MC, Nagy ZZ. Intraocular lens tilt and decentration measured by Scheimpflug camera following manual or femtosecond laser-created continuous circular capsulotomy. *J Refract Surg.* 2012;28(4):259-263. 5. Ali MH, et al. Comparison of characteristics of femtosecond laser-assisted anterior capsulotomy versus manual continuous curvilinear capsulorrhexis: a meta-analysis of 5-year results. *J Pak Med Assoc.* 2017;67(10):1574-1579. 6. Mastrospasqua L, Toto L, Mastrospasqua A, et al. Femtosecond laser versus manual clear corneal incision in cataract surgery. *J Refract Surg.* 2014;30(1):27-33. 7. Alcon Data on File. 8. Crozafo P, Bouchet C. Real-world comparison of FLACS vs. standard PCS: a retrospective cohort study from an outpatient clinic in France. Poster presented at: ESCRS; October 7-11, 2017; Lisbon, Portugal. 9. Al-Mohtaseb Z, et al. Comparison of corneal endothelial cell loss between two femtosecond laser platforms and standard phacoemulsification. *J Refract Surg.* 2017;33(10):708-712. 10. Bouchet, C et al. Comparing the efficacy, safety, and efficiency outcomes between LenSx femtosecond laser-assisted cataract surgery and phacoemulsification cataract surgery: a meta-analysis. *Value in Health.* 2017;20(9):A800-A801. 11. Yesilirmak N, Diakonis VF, Sise A, Waren DP, Yoo SH, Donaldson KE. Differences in energy expenditure for conventional and femtosecond-assisted cataract surgery using 2 different phacoemulsification systems. *J Cataract Refract Surg.* 2017;43:16-21. 12. Roberts TV, et al. Update and clinical utility of the LenSx femtosecond laser in cataract surgery. *Clin Ophthalmol.* 2016;10:2021-2029. 13. Roberts TV, Lawless M, Sutton G, Hodge C. Anterior capsule integrity after femtosecond laser-assisted cataract surgery. *J Cataract Refract Surg.* 2015;41(5):1109-1110.





# All for One, and One for All

*Musings on life, medicine and the practice of ophthalmology.*

**MARK H. BLECHER**  
CHIEF MEDICAL EDITOR

**F**ear and insecurity—very primal emotions which have existed from the dawn of Man. They're useful emotions and, in many circumstances, help with survival; and if not survival then comfort, growth and prosperity. Who wouldn't want that? For yourself, your family, your 'group.' It's healthy and necessary to have a degree of fear and insecurity, as you never know where a threat to your success will come from. But is it? Is it healthy and should it really be necessary?

I suppose the answer to that depends on when and where you are: a neolithic cave sheltering your family, a small medieval village subject to plundering, or a modern social group worried about its place in an ever-changing world. All of those locations are made potentially more secure by identifying and gathering like individuals. But alike how? By race, religion, an ethnic group—or a combination of all three. It's how society has survived and evolved for millennia, but it's debatable whether it's a laudable goal in the 21st century. To quote an old song lyric: "Are you better off alone?"

While homogenous societies have done very well, there's a lot to be said for pooling resources. The term "globalization" has gotten a bad rap of late. However, it's resulted in a significant improvement in world poverty levels, life spans and prosperity for the world

as a whole. And therein lies the rub: While the overall level of quality of life has increased for almost everyone, there's a tradeoff. While a rising tide lifts all boats, some boats are lifted more than others. That's when the resentment starts. In a challenging and complex world, we would all do better if we helped each other.

Pulling yourself up by your bootstraps is a great place to start, but if you find your boots stuck in the mud having someone give you a hand will get you back to productivity quicker. And the wider we view the potential pool of "others" who could lend a hand, the more stable the society. That would require that we potentially look beyond the parameters that defined our group, however, and that we view the larger world as potentially an ally and not a threat. We need to work to step away from humans' inherent xenophobia. Retreating to our cave is unlikely to benefit us in the long run. And let me be clear, I'm not advocating for naïve globalism. Just that we stop being suspicious of everyone that doesn't look or think like us.

Here in the United States, we have a long history of 'rugged individualism,' of not having to be dependent on others—which is great. That is, until you're faced with a situation that no one person or small group of people can successfully address. But many segments of our society have encouraged looking down on those who need that help, that they are "less than" and deserve derision. But there's a huge difference between not trying and not able. Everyone should try to the best of their ability. But no one should be afraid to ask for help, be denigrated for asking for help or looked upon as being different than those who haven't had to ask for help—yet.

That day will come for many of us. Where life's vicissitudes are more than one person, one family, one community or even one state can handle. And at that point you're happy that someone, a person you may have ridiculed, had thought to create a concept that was structured to pool resources to help others. This begrudging revelation likely came to many in great need after Hurricanes Helene and Milton. They were happy their community had help from the state. And happy that there was a FEMA, and federal disaster relief and the National Guard, all paid for by the rest of us as a shared resource to help each other out when in need. It's the reason it's the United States, united so that we can all have the opportunity to prosper—even when it takes more than a village. ◀



*This article has no commercial sponsorship.*

Dr. Blecher is an attending surgeon at Wills Eye Hospital.



EDITED BY ARTURO CHAYET, MD

## REFRACTIVE/CATARACT RUNDOWN

# Rare Cataract Reminders

*Tips for approaching the challenging cases that aren't seen too often.*

**LIZ HUNTER**  
SENIOR EDITOR

**O**n a typical day in the OR, cataract surgeons are most likely going to deal with traditional presentations with no hiccups. However, every so often they need to be prepared for rare cataracts and their inherent challenges, whether it's a hyper-mature Morgagnian, traumatic or even the visually striking Christmas tree cataracts.

"I perform approximately 6,000 cataract surgeries a year, so just by sheer probability it's common for me to see all of these presentations," says Douglas K. Grayson, MD, who is a cataract and glaucoma specialist at Omni Eye Services in New Jersey, as well as an attending surgeon at New York Eye and Ear Infirmary. "Even the hyper-mature cataracts—you'd be surprised that patients can walk around with good vision in one eye and not realize an issue in the second eye until something obstructs it."

Here, we offer helpful reminders and tips to successfully navigate a few of these unique cataracts.

### Morgagnian

Morgagnian cataracts are hyper-mature cataracts, where the cortex of the lens is fully liquefied, and the nucleus is essentially floating in this liquid pool of cortex. According to Amanda C. Maltry, MD, who is a general ophthalmologist and ophthalmology pathologist, as well as an associate professor at the University

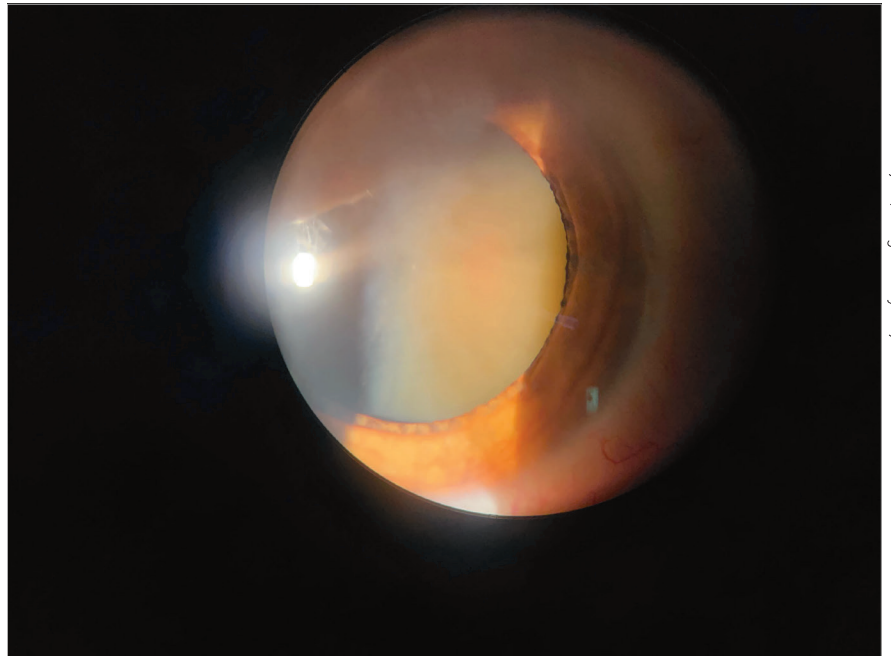
of Minnesota, Morgagnian cataracts are often called "Sunset" cataracts.

"When the patient is seated upright at the slit lamp, the nucleus sinks to the bottom, resembling the setting sun," says Dr. Maltry. "One significant concern in these cases is that the liquefied cortical proteins can leak through the lens capsule. This leakage can lead to protein accumulation in the anterior chamber, where macrophages may attempt to clear it, potentially clogging the trabecular meshwork and causing an increase in intraocular pressure, or

phacolytic glaucoma. Therefore, the main reasons for performing cataract surgery in these cases are to prevent secondary glaucoma and to clear the visual axis by removing the opacity."

Attempting the capsulorhexis is one of the most challenging surgical aspects for Morgagnian cataracts, says Dr. Maltry. "Due to the liquefied cortex, the lens capsule can be under pressure," she says. "This pressure increases the likelihood that the initial puncture during capsulorhexis will radialize or result in an Argentinian flag sign. That's probably the thing that always gets my blood pressure up a little bit at the start of these cases."

Some may opt for making an initial incision with a blade, says Dr. Grayson. "Doing a capsulotomy in a floppy anterior capsule can be



Muhammad Shahbakti, OD/Douglas Grayson, MD

**In cases of hyper-mature Morgagnian cataracts, the cortex has liquefied and the dense nucleus has sunk to the bottom of the capsular bag. This can make the capsulorhexis challenging and surgeons say the pressure inside the capsule could increase the risk of radialization, resulting in the Argentinian flag sign.**

**This article has no commercial sponsorship.**

**Dr. Chayet** is considered a pioneer in refractive and cataract surgery, and is the medical director of the Codet Vision Institute in Tijuana, Mexico. He is a clinical investigator for RxSight, LensGen and ForSight Vision6.

quite challenging,” he says. “In these cases you may need to use one of the blades, either the paracentesis blade or the keratome, to initially incise the anterior capsule for the capsulotomy.”

On the other hand, Dr. Maltry says, based on her experience, a well-filled anterior chamber is effective and negates the need to aspirate. “I ensure that the anterior chamber is fully filled with viscoelastic to flatten the anterior capsule,” she says. “You could also consider a shell technique where you start with a dispersive viscoelastic and then inject a heavier weight cohesive viscoelastic, such as Healon 5.”

Dr. Grayson prefers Viscoat. “It’s advisable to use a dispersive viscoelastic,” he says. “Sometimes, aspirating out the liquefied cortex can enhance visualization. Ultimately, success in these procedures hinges on visualization and control, which can be achieved using a combination of trypan blue, aspiration of some cortex and viscoelastic.”

Both surgeons emphasize the value of trypan blue stain. “Using trypan blue to stain the capsule is essential, as the lens is completely opaque and there will be no red reflex,” says Dr. Maltry.

Once the capsulorhexis is complete, cataract surgeons must evaluate how to proceed with removing the nucleus. “Since the cortex is now liquid, that will all aspirate out quickly, leaving the nucleus loose yet dense within the capsule,” says Dr. Maltry. “Gaining purchase on the nucleus with the phaco tip can be difficult. One strategy is to envelop the nucleus with viscoelastic by injecting it behind and in front of the lens, creating a sandwich effect to trap the nuclear fragment. This technique helps reduce the required phaco energy and protect the corneal endothelium. I find that using a phaco chop technique is effective, as grooving the lens is difficult due to its instability and density. In recent years, the MiLoop has also become a useful tool in such situations, though

I don’t use it frequently.”

Dr. Grayson says he hasn’t personally used the MiLoop, although he knows of some surgeons who’ve had success with it. “Whether it adds significant safety to the procedure depends largely on a surgeon’s comfort level with phacoemulsification,” he says. “More seasoned surgeons tend to handle hard nuclei well, having gained experience in a time when cataracts were much more mature and phaco equipment was less advanced. For younger ophthalmologists encountering hard cataracts without adequate training, using a MiLoop might simplify the process. However, I question whether it justifies the cost and effort involved.”



**Ultimately, success in these procedures hinges on visualization and control, which can be achieved using a combination of trypan blue, aspiration of some cortex and viscoelastic.**

**– Douglas K. Grayson, MD**



Morgagnians may even call for using a supracapsular tile technique, Dr. Grayson adds. “The Morgagnians tend to have a very hard center, so you’re not going to be able to do a quadratic crack or a chop, because the nucleus is floating in the free cortex. You have to be comfortable using a supracapsular tilt technique to get out those hard centers,” he says.

The integrity of the zonules further influences how the surgery continues, say surgeons.

“If the zonules are compromised, it poses significant issues during surgery,” Dr. Grayson says. “As long as the capsule remains intact with healthy zonules, you can perform the procedure effectively. For Morgagnian cataracts, the zonules can some-

times be partially dissolved, resulting in subluxation.”

If zonules are lost, support is compromised and capsular tension rings might not be feasible.

“When there’s any indication of compromised zonules, you should be comfortable using capsular support hooks—not just iris hooks, but capsular support hooks as well,” Dr. Grayson says. “It’s important to place them early to ensure good capsular stability during phacoemulsification. My threshold for using capsular hooks is whenever I notice too much wobbling or instability; I’ll insert them early, even before starting the phaco procedure, to ensure stability.”

Surgeons must then decide whether to proceed with an anterior chamber lens or a sulcus-sutured fixated lens. “I have to determine whether there’s enough stability to insert a posterior chamber lens in the bag or if you need a sutured option,” he continues. “We often discuss devices like Ahmed segments that can be sutured in the bag. While they have benefits, they’re labor-intensive and can lead to potential complications, such as suture erosion. In some instances, it may be better to leave the situation as-is and schedule a secondary lens fixation after inflammation from the initial cataract surgery has cooled down.”

## Traumatic

Traumatic cataracts present unique challenges, and can develop over time or quickly.

“Some traumatic cataracts are obvious, and when examining the patient, you can observe signs of negative dehiscence, and you may gather a history of trauma, which helps in planning the surgical approach,” Dr. Grayson says. “If you identify localized zonular absence, you should plan to place capsular support hooks in that area. For smaller dehiscences, 90 degrees or less, you might get away with simply placing the lens with a haptic in that area or using a capsular tension ring. However, for

larger areas of zonular absence, a more extensive surgical plan may be necessary, possibly involving sutured segments.”

He says to prepare for unpredictability. “The trickier traumatic cataracts are the cases where you’re uncertain about the extent of trauma until you’re in the operating room,” Dr. Grayson says. “If you know going in that this is going to be a tough case, you should block the patient. It’s unpredictable—sometimes you can do a perfect case and still have some vitreous prolapse around the missing zonular areas. You have to be prepared for the lens to totally try to go south if there’s enough trauma, so in those cases, it’s wise to support them with capsular hooks. A supracapsular technique is generally preferable to capsular cracking or chopping, as it reduces stress on the zonules and minimizes the risk of the lens migrating posteriorly. By using viscoelastic below the nucleus, you create a barrier to protect the capsule and facilitate the phacoemulsification process in the iris plane.”

Dr. Maltry says ultrasound biomicroscopy could be beneficial, and she doesn’t rule out consulting retina colleagues. “For rapidly developing traumatic cataracts, I often worry about a possible defect in the lens capsule, whether anterior or posterior,” she says. “If available, using UBM can help assess if the lens capsule is intact. If it appears that the posterior capsule is ruptured, I might consult with my retina colleagues for a potential pars plana lensectomy, as there’s a good chance the lens may fall backward anyway.”

“Assessing the anterior capsule can be trickier since quickly developing cataracts tend to become white, obscuring the reflex and making it difficult to evaluate,” she continues. “If there’s lens mate-

rial exposed to the anterior chamber, the inflammatory system will begin to react to that, which can lead to phacoantigenic inflammation and potentially glaucoma.”

Again, staining is a key step. “For rapidly developing traumatic cataracts with an anterior capsule rupture, I usually stain the capsule with trypan blue to identify the area of the rent,” recommends Dr. Maltry. “Depending on its location, I might use a cystotome or micro scissors to create the best possible capsulorhexis. Although the shape may not be perfectly round, the goal is to create enough access to remove the lens. Most of these cataracts are soft, allowing for aspiration or minimal phaco energy during removal once the capsule defects are identified.”

In the case of a white traumatic

cataract, Dr. Maltry suggests a B-scan to make sure there’s no posterior segment pathology as well.

## Christmas Trees and More

Christmas tree cataracts are particularly beautiful, resembling iridescent Easter grass, says Dr. Maltry.

“They’re classically associated with autosomal dominant myotonic dystrophy, a genetic disease affecting the muscles,” she says. Symptoms can include cataract development.

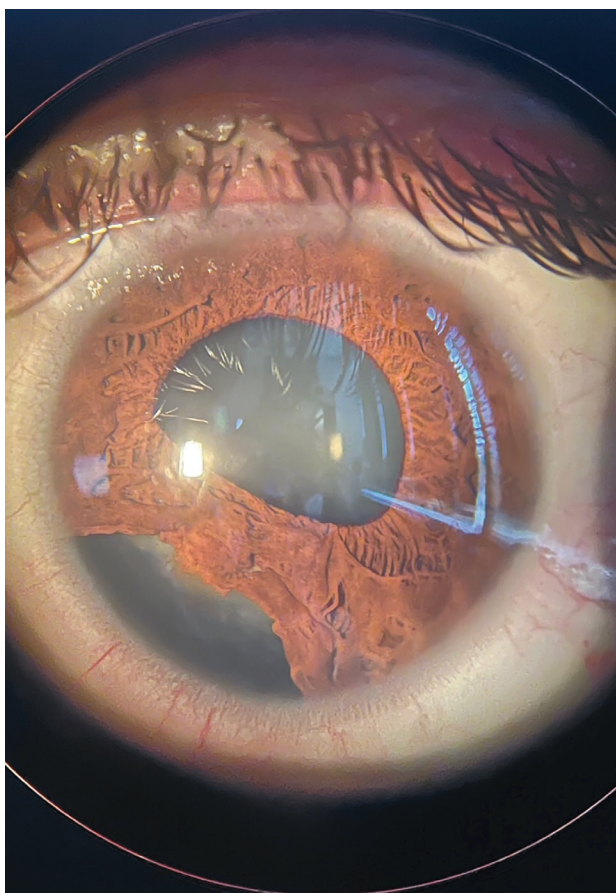
“When I encounter patients with this type of cataract, I inquire about muscle spasms, which is common in myotonic dystrophy,” continues Dr. Maltry. “However, while many patients with myotonic dystrophy may have Christmas tree cataracts, less than 20 percent of all Christmas tree cataract cases are due to this condition. Most cases are unrelated to systemic illnesses and are a fascinating example of protein crystallization in the lens.”

Patients with Christmas tree cataracts report symptoms similar to other cataract types, such as blurriness, glare and halos. “When they present, their symptoms don’t help differentiate between cataract types, but these cataracts can be visually significant,” she says. “If a patient has a Christmas tree cataract along with other types, it appears to compound the visual challenges, behaving similarly to any other cataract.”

Although their appearance makes them special, these cataracts are typically soft and manageable, so they aspirate pretty easily, says Dr. Grayson.

Other challenging cataracts Dr. Grayson offers tips on include:

- **Marfan’s syndrome.** “In patients with Marfan’s syn-



Muhammad Shahbekt, OD/Douglas Grayson, MD

**Shown here is a traumatic cataract with iridodialysis and zonular loss. Experts recommend using capsular support hooks in these situations and they may even consider involving retina colleagues to perform a pars plana lensectomy.**



## 2ND YEAR OPHTHALMOLOGY RESIDENT

**PROGRAMS AND WET LABS**

Dear Resident Program Director and Coordinator,

We would like to invite you to review the upcoming 2nd-Year Ophthalmology Resident Wet Lab Programs for the 2024–2025 Residency Year in Fort Worth. These programs offer a unique educational opportunity for second-year residents. To better familiarize beginning ophthalmologists with cataract surgery, these programs will consist of both didactic lectures and a state-of-the-art, hands-on wet lab experience. Technology and technique will be explained and demonstrated and surgeons will leave better prepared to optimize outcomes and manage complications when they arise. The programs also serve as an opportunity for your residents to network with residents from other programs.

After reviewing the material, it is our hope that you will select and encourage your 2nd Year residents to attend one of these educational activities, which are CME accredited to ensure fair balance.

Best regards,

Derek DeMonte, MD, Kourtney Houser, MD, and Jonathan Rubenstein, MD

**DECEMBER 7–8, 2024**  
FORT WORTH, TX

**Jonathan Rubenstein, MD**  
Course Director

**FEBRUARY 8–9, 2025**  
FORT WORTH, TX

**Derek DeMonte, MD**  
Course Director

**FEBRUARY 22–23, 2025**  
FORT WORTH, TX

**Kourtney Houser, MD**  
Course Director



**Registration Open: [www.ReviewEdu.com/CSE2ndYr2024-25](http://www.ReviewEdu.com/CSE2ndYr2024-25)**

For more information visit the registration site above by scanning the QR code, call Denette Holmes at 866-627-0714, or email [dholmes@postgradhealthed.com](mailto:dholmes@postgradhealthed.com).

**CME courses are restricted to 2nd-year residents enrolled in an ophthalmology residency program at the time of the course. There is no registration fee for this activity. Air, ground transportation in Fort Worth, hotel accommodations, and modest meals will be provided through an educational scholarship for qualified participants.**

**Joint Accreditation Statement**

In support of improving patient care, this activity has been planned and implemented by Amedco LLC and Review Education Group, LLC. Amedco LLC is jointly accredited by the Accreditation Council for Continuing Medical Education (ACCME), the Accreditation Council for Pharmacy Education (ACPE), and the American Nurses Credentialing Center (ANCC), to provide continuing education for the healthcare team. Amedco Joint Accreditation #4008163



JOINTLY ACCREDITED PROVIDER  
INTERPROFESSIONAL CONTINUING EDUCATION

**Physicians (ACCME) Credit Designation**

This activity has been approved for **AMA PRA Category 1 Credits™**.

Supported by an independent medical education grant from

**Alcon**

Jointly provided by

**AMEDCO**

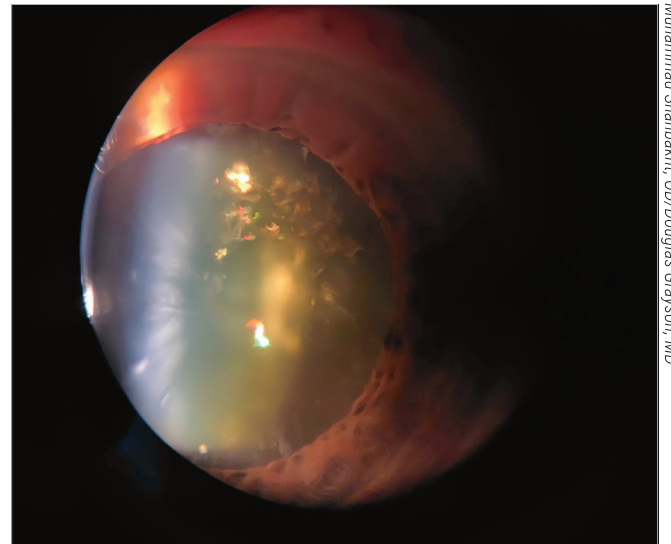
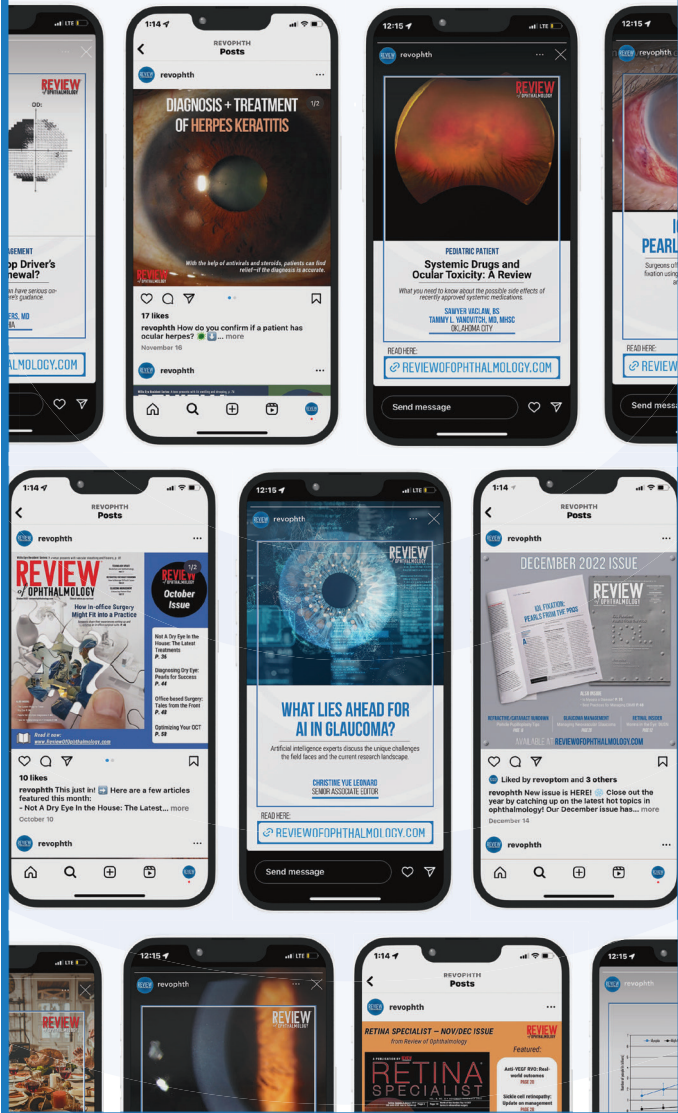
**REVIEW**  
Education GROUP

# A NEW WAY TO EXPERIENCE

## REVIEW OF OPHTHALMOLOGY

Follow us on Instagram for striking clinical images, news headlines, issue previews and great content from the magazine—all formatted for mobile.

 @REVOPHTH



Muhammad Shahbakti, OD/Douglas Grayson, MD

Patients with myotonic dystrophy may exhibit Christmas Tree cataracts, the appearance of which is due to the crystallization of proteins inside the lens. Although they look unlike other cataracts, they behave similarly and are typically soft and easy to remove.

drome, cataracts often present with subluxation,” he says. “While some surgeons opt for complex techniques involving capsular support hooks and sutured Ahmed segments to place a posterior chamber lens, I sometimes find it less traumatic to call in a retina specialist to perform a pars plana lensectomy to remove the lens entirely. The incision is small, and you can bring the patient back another day to insert an ACIOL or a sulcus-fixated lens using a Yamane technique. This decision ultimately lies with the surgeon’s discretion, but it’s vital to block these patients to manage the surgery effectively.”

• **Congenital posterior polar cataracts.** “In this scenario the biggest risk is having a posterior capsule attachment to the cataract, so that when you remove the cataract, you also remove a chunk of the posterior capsule and have a risk of vitreous loss,” he says. “So traditionally, we’ve always said to try to avoid hydrodissecting aggressively in those cataracts, because if you create a fluid wave and you hydrodissect and you blow out the posterior capsule before you’ve taken the nucleus out, you have a high chance of the nucleus dislodging posteriorly as soon as you go in because it’s almost like a trap door.”

• **Anterior cortical cataracts.** These can occur in patients with atopic disease. “The anterior capsule could be very stiff, and we use 25-gauge retinal scissors to make cuts in some fibrotic tissue that may be on the anterior capsule, with the goal being to try to come around as consistently as possible to create a continuous, curvilinear capsulorhexis,” Dr. Grayson says. ◀

### DISCLOSURES

Dr. Grayson consults for Alcon, Johnson & Johnson Vision, AbbVie, New World Medical and Glaukos. Dr. Maltry has no disclosures.



# Ocular Manifestations Of Congenital Syphilis

*Experts describe the increasing prevalence of this disease and dive into signs beyond Hutchinson’s triad.*

**LINUS PARK, BA, SANG NGUYEN, BS, AND TAMMY YANOVITCH, MD, MHSC**  
OKLAHOMA CITY

**H**ave you noticed an increase in consults for newborn eye screening exams with syphilis exposure recently? I’ve seen a significant rise in my practice over the past 12 to 24 months. Why is this happening, and how should pediatric ophthalmologists approach these patients? This article will discuss the recommended frequency and timing of eye screenings in newborns with syphilis exposure, as well as the specific systemic and ocular signs to be aware of.

## Resurgence and Rise of Congenital Syphilis Cases

Despite national efforts to raise awareness and control the spread of syphilis, the incidence of congenital cases has been on the rise, with a reported 219.3-percent increase between 2017 and 2021, in contrast to other sexually transmitted infections such as chlamydia or gonorrhea, which have been stable or declining.<sup>1</sup> These numbers are especially worrisome considering data from 2022, which shows a nearly tenfold increase from the 335 cases of babies born with syphilis in

2012.<sup>2</sup>

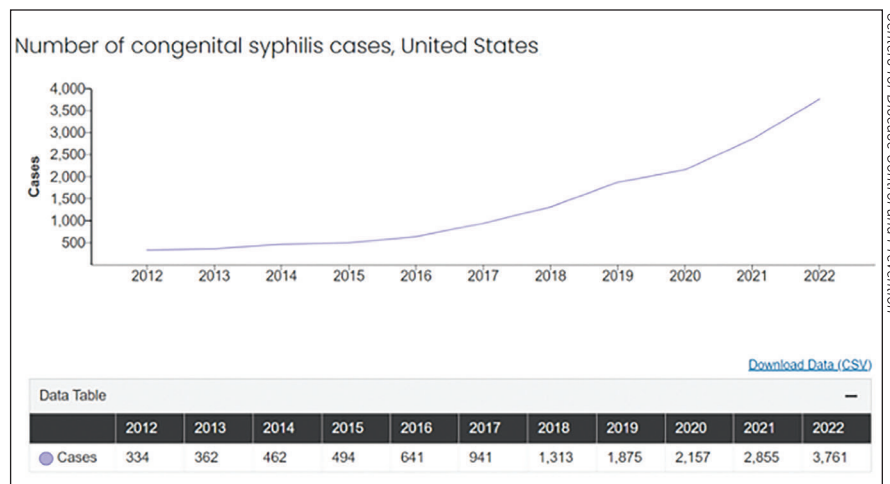
The significant rise in congenital syphilis cases deeply concerns health-care leaders. Jonathan Mermin, the director of the CDC’s National Center for HIV, Viral Hepatitis, STD and TB Prevention, stated, “The congenital syphilis epidemic is an unacceptable American crisis. All pregnant mothers—regardless of who they are or where they live—deserve access to care that protects them and their babies from preventable disease.” Between 2016 and 2023, annual reports of congenital syphilis ranged from 700,000 to 1.5 million cases world-

wide, and 2,677 cases were reported in the United States in 2021 alone (Figure 1).<sup>1,2</sup>

Despite the severe symptoms and poor outcomes in untreated infants and children, there’s hope to combat the congenital syphilis epidemic. This hope stems from findings that timely testing and treatment could prevent nine out of 10 congenital syphilis cases. More than half of the current patient population testing positive for syphilis struggles with receiving adequate care. Nearly 40 percent of those are women without prenatal care, which means that there are definitive ways to improve outcomes.<sup>2</sup>

## Understanding At-Risk Groups

Effective prenatal screening and antibiotic treatment can prevent congenital syphilis; therefore, the risk of infection is highest among groups with significant barriers to accessing health care. Women with lower socioeconomic status often experience prolonged delays in prenatal care due to lack of



**Figure 1. The number of congenital syphilis cases in the United States from 2010 to 2020.<sup>19</sup>**

Centers for Disease Control and Prevention

This article has no commercial sponsorship.

Dr. Collinge is a pediatric ophthalmologist in West Hartford, Connecticut.

transportation, difficulties navigating Medicaid, and insufficient knowledge of screening protocols.<sup>3</sup> These barriers are particularly relevant to women with histories of substance abuse and housing insecurity who may avoid care altogether due to societal stigma or potential legal consequences. Vulnerable populations also include non-English speakers and women with low levels of education, as they often lack knowledge regarding safe sex practices and how sexually transmitted infections may impact pregnancy.<sup>4,5</sup>

While all racial groups are experiencing increased rates of congenital syphilis, the burden of infection disproportionately affects racial minorities who already face inequities in health-care access. American Indian/Alaska Native populations are acutely affected by congenital syphilis—despite making up only 0.7 percent of live births, these infants account for 4.6 percent of reported congenital syphilis cases.<sup>6</sup>

While the total number of reported cases remains small (171 in 2022), rates of congenital syphilis among AI/AN births surged between 2018 and 2022, rising from 101.8 to 644.7 cases per 100,000 live births (Figure 2).<sup>7</sup> Native Hawaiian/Pacific Islander, Latino and Black communities are also experiencing high rates of congenital syphilis, with infants born to Black mothers composing the most significant total number of reported cases by race.<sup>7</sup> Despite 30 percent of all infections occurring in White-mother births, rates of reported cases for this group remain well below that of communities of color, increasing to 54.1 cases per 100,000 births in 2022.<sup>8</sup>

The geographic distribution of U.S. congenital syphilis cases is concentrated in the South and West. This trend reflects the nation’s demographic and inter-state differences in health-care infrastructure. The five states with the

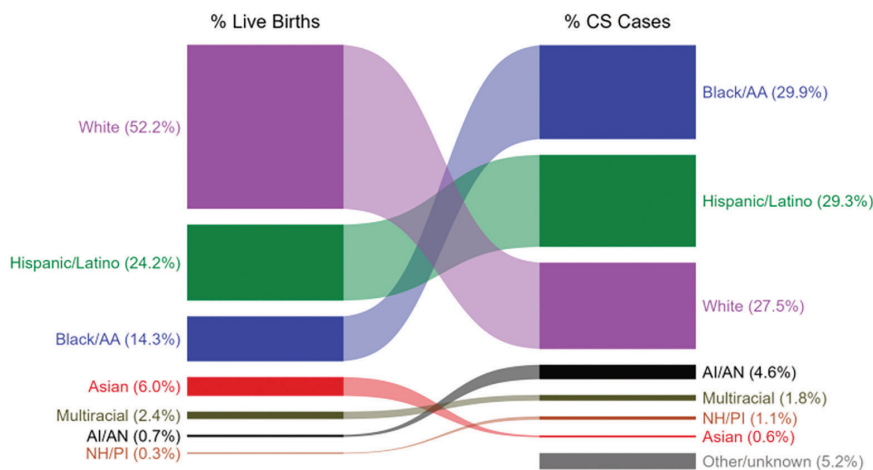
**PEDIATRIC OCULAR FINDINGS**

What ocular findings should a pediatric ophthalmologist look for when examining a neonate for eye involvement in syphilis?

1. Conjunctival injection
2. Corneal opacity
3. Anterior chamber inflammation
4. Lenticular opacity
5. Elevated intraocular pressures
6. Chorioretinal inflammation (Figure 3)
7. Optic nerve swelling or pallor (Figure 4)

highest rates of congenital syphilis (NM, SD, AZ, TX, OK) possess significant American Indian populations, with the next five states similarly being home to large populations of other at-risk racial groups.<sup>7,9</sup> Regions most affected by rising cases also lack the mater-

### Congenital Syphilis — Total Live Births and Reported Cases by Race/Hispanic Ethnicity of Mother, United States, 2022



**NOTE:** In 2022, a total of 197 congenital syphilis cases (5.2%) had missing, unknown, or other race and were not reported to be of Hispanic ethnicity. These cases are included in the “other/unknown” category.

**ACRONYMS:** AI/AN = American Indian or Alaska Native; Black/AA = Black or African American; NH/PI = Native Hawaiian or other Pacific Islander



**Figure 2. The number of total live births and reported cases of congenital syphilis in the United States by race/Hispanic ethnicity by mother in 2022.<sup>20</sup>**



# SYFOVRE<sup>®</sup>

(pegcetacoplan injection)  
15 mg/0.1 mL

## Save more retinal tissue

Through Year 2, in OAKS and DERBY, SYFOVRE slowed GA lesion growth vs sham pooled.<sup>1</sup>

SYFOVRE slowed GA lesion growth with **increasing effects over time up to 42%** in Year 3 (GALE) vs projected sham in patients without subfoveal lesions<sup>1,2</sup>

- Through Year 2 (OAKS and DERBY), SYFOVRE slowed GA lesion growth (mm<sup>2</sup>) vs sham pooled by 22% (3.11 vs 3.98) and 18% (3.28 vs 4.00) monthly, and by 18% (3.26 vs 3.98) and 17% (3.31 vs 4.00) EOM<sup>1,2</sup>
- Through Year 3 (GALE), SYFOVRE slowed GA lesion growth (mm<sup>2</sup>) vs sham pooled/projected sham by 25% (4.46 vs 5.94) monthly and 20% (4.74 vs 5.94) EOM. The greatest differences were observed in Year 3<sup>2</sup>
- Reductions in patients without subfoveal lesions at baseline through Year 3: 32% (5.10 vs 7.54 (n=95)) monthly and 26% (5.60 vs 7.54 (n=104)) EOM. In this subset of patients, there was a 42% reduction with monthly SYFOVRE in Year 3 vs projected sham

SE in trials (monthly, EOM, sham pooled/projected sham): OAKS: 0.15, 0.13, 0.14; DERBY: 0.13, 0.13, 0.17; GALE (total population): 0.16, 0.16, 0.19; GALE (without subfoveal): 0.26, 0.31, 0.41<sup>1,2</sup>

EOM=every other month; GA=geographic atrophy; SE=standard error.

Discover more at  
[SyfovreECP.com](https://www.syfovre.com)

**GALE Trial Limitations:** GALE is an ongoing open-label, multi-center extension study, subject to patient dropouts over time. The analysis for the first year of GALE utilized a projected sham and may not reflect rate of change of all patients with GA. Projected sham assumes linear growth rate from Months 24–36 (GALE Year 1) based on the average of the mean rate of change of each 6-month period of sham treatment in OAKS and DERBY and natural history studies, which have shown there is a high correlation between prior 2-year growth rates of GA lesions and subsequent 2-year growth rates. This is a prespecified analysis but there is no statistical testing hierarchy, therefore the results on the individual components need cautious interpretation. Open-label studies can allow for selection bias.<sup>2,3</sup>

### INDICATION

SYFOVRE<sup>®</sup> (pegcetacoplan injection) is indicated for the treatment of geographic atrophy (GA) secondary to age-related macular degeneration (AMD).

### IMPORTANT SAFETY INFORMATION

#### CONTRAINDICATIONS

- SYFOVRE is contraindicated in patients with ocular or periocular infections, and in patients with active intraocular inflammation

#### WARNINGS AND PRECAUTIONS

##### Endophthalmitis and Retinal Detachments

- Intravitreal injections, including those with SYFOVRE, may be associated with endophthalmitis and retinal detachments. Proper aseptic injection technique must always be used when administering SYFOVRE to minimize the risk of endophthalmitis. Patients should be instructed to report any symptoms suggestive of endophthalmitis or retinal detachment without delay and should be managed appropriately.
- **Retinal Vasculitis and/or Retinal Vascular Occlusion**
  - Retinal vasculitis and/or retinal vascular occlusion, typically in the presence of intraocular inflammation, have been reported with the use of SYFOVRE. Cases may occur with the first dose of SYFOVRE and may result in severe vision loss. Discontinue treatment with SYFOVRE in patients who develop these events. Patients should be instructed to report any change in vision without delay.
- **Neovascular AMD**
  - In clinical trials, use of SYFOVRE was associated with increased rates of neovascular (wet) AMD or choroidal neovascularization (12% when administered monthly, 7% when administered every other month and 3% in the control group) by Month 24. Patients receiving SYFOVRE should be monitored for signs of neovascular AMD. In case anti-Vascular Endothelial Growth Factor (anti-VEGF) is required, it should be given separately from SYFOVRE administration.

##### Intraocular Inflammation

- In clinical trials, use of SYFOVRE was associated with episodes of intraocular inflammation including: vitritis, vitreal cells, iridocyclitis, uveitis, anterior chamber cells, iritis, and anterior chamber flare. After inflammation resolves, patients may resume treatment with SYFOVRE.
- **Increased Intraocular Pressure**
  - Acute increase in IOP may occur within minutes of any intravitreal injection, including with SYFOVRE. Perfusion of the optic nerve head should be monitored following the injection and managed as needed.

#### ADVERSE REACTIONS

- Most common adverse reactions (incidence ≥5%) are ocular discomfort, neovascular age-related macular degeneration, vitreous floaters, conjunctival hemorrhage.

Please see Brief Summary of Prescribing Information for SYFOVRE on the adjacent page.

**OAKS and DERBY Trial Design:** SYFOVRE safety and efficacy were assessed in OAKS (N=637) and DERBY (N=621), multi-center, 2-year, Phase 3, randomized, double-masked trials. Patients with GA (atrophic nonexudative age-related macular degeneration) with or without subfoveal involvement, secondary to AMD were randomly assigned (2:2:1) to receive 15 mg/0.1 mL intravitreal SYFOVRE monthly, SYFOVRE every other month, sham monthly, or sham every other month, for 2 years. Change from baseline in the total area of GA lesions in the study eye (mm<sup>2</sup>) was measured by fundus autofluorescence (FAF).<sup>1,2</sup>

**GALE Trial Design:** GALE (N=790) is a multi-center, 3-year, Phase 3, open-label extension study to evaluate the long-term safety and efficacy of pegcetacoplan in subjects with geographic atrophy secondary to age-related macular degeneration. Patients enrolled in GALE include those who completed OAKS or DERBY after 2 years and 10 patients from Phase 1b Study 103. Patients with GA (atrophic nonexudative age related macular degeneration) with or without subfoveal involvement, secondary to AMD were assigned to receive 15 mg/0.1 mL intravitreal SYFOVRE monthly or SYFOVRE EOM for 3 years. The first visit was required to be within 60 days of the final visit in OAKS and DERBY.<sup>2</sup>

**References:** 1. SYFOVRE (pegcetacoplan injection) [package insert]. Waltham, MA: Apellis Pharmaceuticals, Inc.; 2023. 2. Data on file. Apellis Pharmaceuticals, Inc. 3. Sunness JS, Margalit E, Srikumar D, et al. The long-term natural history of geographic atrophy from age-related macular degeneration: enlargement of atrophy and implications for interventional clinical trials. *Ophthalmology*. 2007;114(2):271–277. doi:10.1016/j.ophtha.2006.09.016.

Apellis

APELLIS<sup>®</sup>, SYFOVRE<sup>®</sup> and their respective logos are registered trademarks of Apellis Pharmaceuticals, Inc. All rights reserved.  
©2024 Apellis Pharmaceuticals, Inc. 9/24 US-PEGGA-2400208 v1.0

**SYFOVRE® (pegcetacoplan injection), for intravitreal use**  
**BRIEF SUMMARY OF PRESCRIBING INFORMATION**  
Please see SYFOVRE full Prescribing Information for details.

**INDICATIONS AND USAGE**

SYFOVRE is indicated for the treatment of geographic atrophy (GA) secondary to age-related macular degeneration (AMD).

**CONTRAINDICATIONS**

**Ocular or Periocular Infections**

SYFOVRE is contraindicated in patients with ocular or periocular infections.

**Active Intraocular Inflammation**

SYFOVRE is contraindicated in patients with active intraocular inflammation.

**WARNINGS AND PRECAUTIONS**

**Endophthalmitis and Retinal Detachments**

Intravitreal injections, including those with SYFOVRE, may be associated with endophthalmitis and retinal detachments. Proper aseptic injection technique must always be used when administering SYFOVRE in order to minimize the risk of endophthalmitis. Patients should be instructed to report any symptoms suggestive of endophthalmitis or retinal detachment without delay and should be managed appropriately.

**Retinal Vasculitis and/or Retinal Vascular Occlusion**

Retinal vasculitis and/or retinal vascular occlusion, typically in the presence of intraocular inflammation, have been reported with the use of SYFOVRE. Cases may occur with the first dose of SYFOVRE and may result in severe vision loss. Discontinue treatment with SYFOVRE in patients who develop these events. Patients should be instructed to report any change in vision without delay.

**Neovascular AMD**

In clinical trials, use of SYFOVRE was associated with increased rates of neovascular (wet) AMD or choroidal neovascularization (12% when administered monthly, 7% when administered every other month and 3% in the control group) by Month 24. Patients receiving SYFOVRE should be monitored for signs of neovascular AMD. In case anti-Vascular Endothelial Growth Factor (anti-VEGF) is required, it should be given separately from SYFOVRE administration.

**Intraocular Inflammation**

In clinical trials, use of SYFOVRE was associated with episodes of intraocular inflammation including: vitritis, vitreal cells, iridocyclitis, uveitis, anterior chamber cells, iritis, and anterior chamber flare. After inflammation resolves patients may resume treatment with SYFOVRE.

**Increased Intraocular Pressure**

Acute increase in IOP may occur within minutes of any intravitreal injection, including with SYFOVRE. Perfusion of the optic nerve head should be monitored following the injection and managed as needed.

**ADVERSE REACTIONS**

**Clinical Trials Experience**

Because clinical trials are conducted under widely varying conditions, adverse reaction rates observed in the clinical trials of a drug cannot be directly compared to rates in the clinical trials of another drug and may not reflect the rates observed in practice.

A total of 839 patients with GA in two Phase 3 studies (OAKS and DERBY) were treated with intravitreal SYFOVRE, 15 mg (0.1 mL of 150 mg/mL solution). Four hundred nineteen (419) of these patients were treated in the affected eye monthly and 420 were treated in the affected eye every other month. Four hundred seventeen (417) patients were assigned to sham. The most common adverse reactions ( $\geq 5\%$ ) reported in patients receiving SYFOVRE were ocular discomfort, neovascular age-related macular degeneration, vitreous floaters, and conjunctival hemorrhage.

**Table 1: Adverse Reactions in Study Eye Reported in  $\geq 2\%$  of Patients Treated with SYFOVRE Through Month 24 in Studies OAKS and DERBY**

Adverse Reactions	PM (N = 419) %	PEOM (N = 420) %	Sham Pooled (N = 417) %
Ocular discomfort*	13	10	11
Neovascular age-related macular degeneration*	12	7	3
Vitreous floaters	10	7	1
Conjunctival hemorrhage	8	8	4
Vitreous detachment	4	6	3
Retinal hemorrhage	4	5	3
Punctate keratitis*	5	3	<1
Posterior capsule opacification	4	4	3
Intraocular inflammation*	4	2	<1
Intraocular pressure increased	2	3	<1

PM: SYFOVRE monthly; PEOM: SYFOVRE every other month

\*The following reported terms were combined:

**Ocular discomfort** included: eye pain, eye irritation, foreign body sensation in eyes, ocular discomfort, abnormal sensation in eye

**Neovascular age-related macular degeneration** included: exudative age-related macular degeneration, choroidal neovascularization

**Punctate keratitis** included: punctate keratitis, keratitis

**Intraocular inflammation** included: vitritis, vitreal cells, iridocyclitis, uveitis, anterior chamber cells, iritis, anterior chamber flare

Endophthalmitis, retinal detachment, hyphema and retinal tears were reported in less than 1% of patients. Optic ischemic neuropathy was reported in 1.7% of patients treated monthly, 0.2% of patients treated every other month and 0.0% of patients assigned to sham. Deaths were reported in 6.7% of patients treated monthly, 3.6% of patients treated every other month and 3.8% of patients assigned to sham. The rates and causes of death were consistent with the elderly study population.

**Postmarketing Experience**

The following adverse reactions have been identified during postapproval use of SYFOVRE. Because these reactions are reported voluntarily from a population of uncertain size, it is not always possible to reliably estimate their frequency or establish a causal relationship to drug exposure. Eye disorders: retinal vasculitis with or without retinal vascular occlusion.

**USE IN SPECIFIC POPULATIONS**

**Pregnancy**

**Risk Summary**

There are no adequate and well-controlled studies of SYFOVRE administration in pregnant women to inform a drug-associated risk. The use of SYFOVRE may be considered following an assessment of the risks and benefits.

Systemic exposure of SYFOVRE following ocular administration is low. Subcutaneous administration of pegcetacoplan to pregnant monkeys from the mid gestation period through birth resulted in increased incidences of abortions and stillbirths at systemic exposures 1040-fold higher than that observed in humans at the maximum recommended human ophthalmic dose (MRHOD) of SYFOVRE (based on the area under the curve (AUC) systemically measured levels). No adverse maternal or fetal effects were observed in monkeys at systemic exposures approximately 470-fold higher than that observed in humans at the MRHOD.

In the U.S. general population, the estimated background risk of major birth defects and miscarriage in clinically recognized pregnancies is 2-4% and 15-20%, respectively.

**Lactation**

**Risk Summary**

It is not known whether intravitreal administered pegcetacoplan is secreted in human milk or whether there is potential for absorption and harm to the infant. Animal data suggest that the risk of clinically relevant exposure to the infant following maternal intravitreal treatment is minimal. Because many drugs are excreted in human milk, and because the potential for absorption and harm to infant growth and development exists, caution should be exercised when SYFOVRE is administered to a nursing woman.

**Females and Males of Reproductive Potential**

**Contraception**

**Females:** It is recommended that women of childbearing potential use effective contraception methods to prevent pregnancy during treatment with intravitreal pegcetacoplan. Advise female patients of reproductive potential to use effective contraception during treatment with SYFOVRE and for 40 days after the last dose. For women planning to become pregnant, the use of SYFOVRE may be considered following an assessment of the risks and benefits.

**Pediatric Use**

The safety and effectiveness of SYFOVRE in pediatric patients have not been established.

**Geriatric Use**

In clinical studies, approximately 97% (813/839) of patients randomized to treatment with SYFOVRE were  $\geq 65$  years of age and approximately 72% (607/839) were  $\geq 75$  years of age. No significant differences in efficacy or safety were seen with increasing age in these studies. No dosage regimen adjustment is recommended based on age.

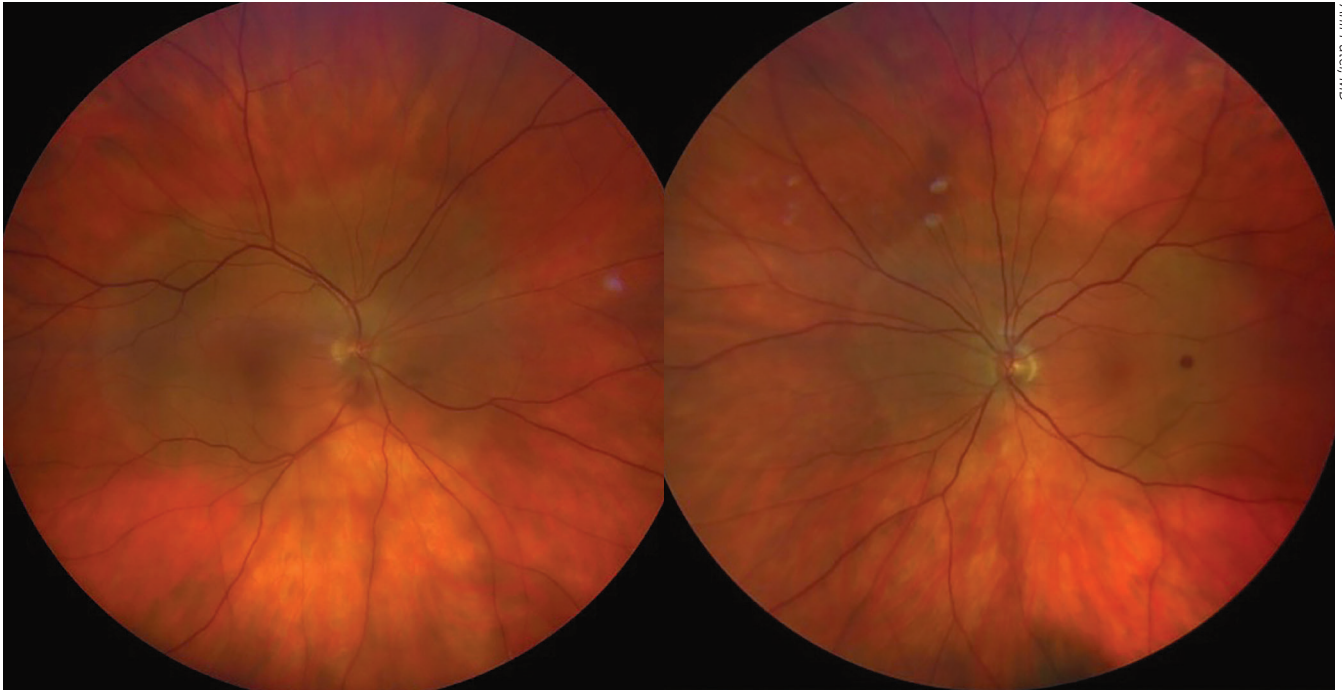
**PATIENT COUNSELING INFORMATION**

Advise patients that following SYFOVRE administration, patients are at risk of developing endophthalmitis, retinal detachments, retinal vasculitis with or without retinal vascular occlusion and neovascular AMD. If the eye becomes red, sensitive to light, painful, or if a patient develops any change in vision such as flashing lights, blurred vision or metamorphopsia, instruct the patient to seek immediate care from an ophthalmologist. Patients may experience temporary visual disturbances associated either with the intravitreal injection with SYFOVRE or the eye examination. Advise patients not to drive or use machinery until visual function has recovered sufficiently.

Manufactured for:  
Apellis Pharmaceuticals, Inc.  
100 Fifth Avenue  
Waltham, MA 02451  
SYF-PI-30NOV2023-2.0

APELLIS®, SYFOVRE® and their respective logos are registered trademarks of Apellis Pharmaceuticals, Inc.  
©2023 Apellis Pharmaceuticals, Inc.

12/23 US-PEGGA-2200163 v4.0



**Figure 3. Fundus photographs showing acute syphilitic posterior placoid chorioretinitis.**

nal health infrastructure needed for effective prevention and treatment. Many of the states ranking within the top half for congenital syphilis rates suffer from large “maternity care deserts,” areas of the state lacking a combination of obstetrics care, adequate providers, and birthing facilities.<sup>7,10</sup> Rural and low-income urban communities often fall under the definition of maternal care deserts, thereby lacking the prenatal screening services required to prevent syphilis cases.

### Screening and Diagnostic Methods

The indiscriminate nature and unpredictable timing of maternal syphilis transmissions create a vulnerability for children at any point during pregnancy and childbirth. Given the current understanding of the different risk groups involved, what modalities and signs should medical professionals incorporate into their practice to screen for congenital syphilis?

The medical checklist recommended for screening signs and symptoms associated with congenital syphilis includes:

**1. Nose.** Rhinitis with mucopurulent nasal discharge.

**2. Skin.** Jaundice, rash, and desquamation.

**3. Abdomen.** Abdominal pain or tenderness due to peritonitis or hepatosplenomegaly.

**4. Eyes.** Vision impairment or any form of ocular inflammation.



**If suspicion of congenital syphilis is high, perform ocular exams to evaluate for the following: chorioretinitis and pigmentary chorioretinopathy (“salt and pepper type”); congenital syphilitic keratouveitis; secondary glaucoma; cataracts; interstitial keratitis; and optic neuritis/atrophy.**



**5. Other.** Pseudoparalysis of an extremity due to osteochondritis. Alongside these general examina-

tions, a thorough maternal medical history and pregnancy history should be obtained, as the quality of a comprehensive medical history may isolate important risk factors and significantly determine diagnostic outcomes.

The presence of syphilis is diagnosed by the collection of maternal and neonatal blood samples to undergo laboratory testing for rapid plasma reagin (RPR), venereal disease research laboratory (VDRL) levels, blood count, and signs of thrombocytopenia in the neonate. CSF reactivity for VDRL, elevated CSF cell count, and fluorescent antibody detection for *Treponema pallidum* may be used to further diagnose syphilis. Positive tests may also be obtained from darkfield tests or PCR of the placenta, cord, any lesions, and/or body fluids from the neonate. Obtaining photographs of congenital anomalies is important for record-keeping and prognosis of long-term complications.<sup>8</sup>

Any abnormal physical findings associated with the symptoms described in the diagnostic methods or serum quantitative titer higher

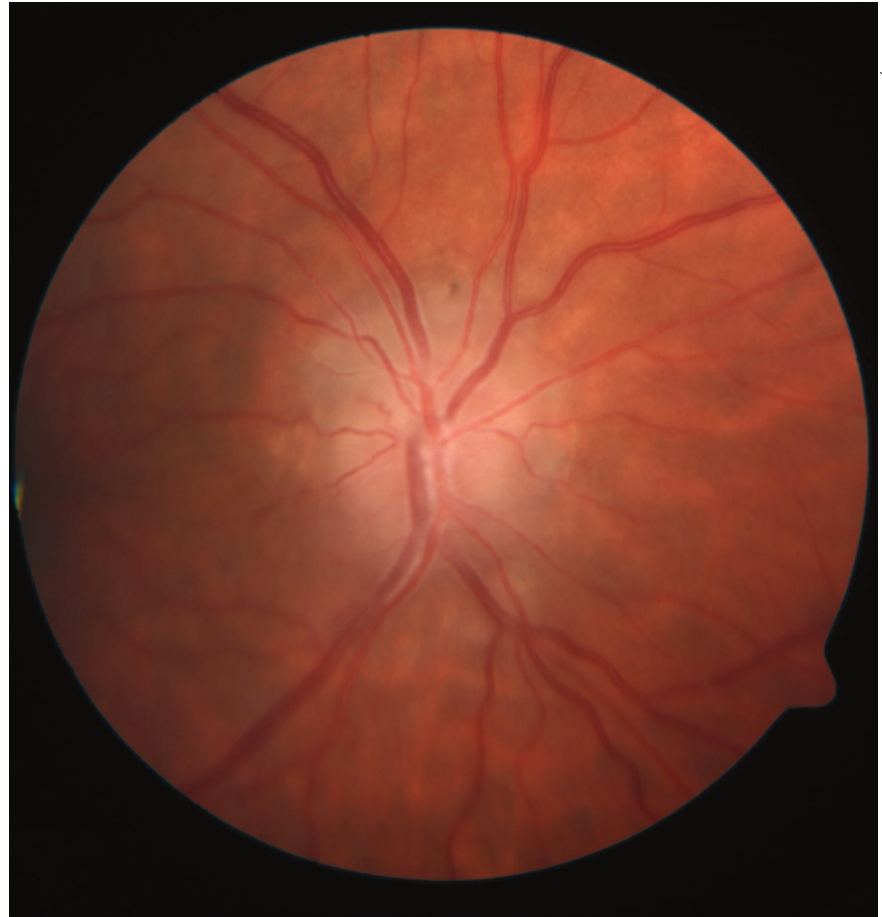than the maternal titer at delivery by fourfold values would categorize the neonate into a highly probable case of congenital syphilis. In this case, a complete CSF analysis with values on VDRL, cell count, and proteins, along with CBC, long-bone radiographs, and other relevant clinical testing—ophthalmologic examination, liver function test, and neuroimaging—is recommended.<sup>11</sup>

The same evaluation methods—complete CSF analysis, CBC, differential, platelet count, and long-bone radiograph—are recommended for neonates with normal physical examination and less than a fourfold difference in nontreponemal quantitative titer from the maternal titer, but with a mother who was inadequately treated or not treated at all.

### Systemic and Ocular Manifestations

One of the biggest challenges presented with the congenital syphilis epidemic is the difficulty in early recognition of symptoms. Laboratory values and antibody testing are reliable metrics for diagnosis. Still, there are risks of long-term complications and medical oversight for situations in which mothers test negative for syphilis during the 16-week gestational period. There’s been evidence of congenital syphilis transmission in countries with high rates of antenatal screening due to medical providers’ reliance on lab values.<sup>12</sup> There are only general indications and broad symptoms linked to congenital syphilis, but any abnormalities in physical exam findings or reasons for suspicion during medical history should prompt a heightened awareness for a differential diagnosis to improve the rate of early recognition and prevention of further complications.

Congenital syphilis arises from transplacental transmission of *Treponema pallidum* from an infected mother to a fetus. Infants



Anil Patel, MD

Figure 4. Fundus photograph showing syphilitic optic neuritis.

coming into direct contact with a syphilis sore during the postpartum period can also present with systemic clinical manifestations of jaundice, rash, hepatosplenomegaly, long-term disabilities, and central nervous infections often observed in congenital syphilis cases.<sup>1,13</sup>

Many ocular structures can be affected by syphilis infections, with findings extending from the front to the back of the eye. Anterior segment findings include keratitis, unilateral or bilateral iritis with granulomatous features, and secondary glaucoma. Patients may have chorioretinitis, vitritis, vasculitis, macular edema, and optic neuritis in the posterior segment. Inflammation can cause damage to these structures and lead to retinal and corneal scarring and optic atrophy.<sup>12,13</sup> In cases of untreated con-

genital syphilis, bilateral interstitial keratitis is one of the most recognized and diagnosed presentations, presenting as early as two-year-old patients but more commonly observed in the age range of 5 to 15 years. Hutchinson’s triad, which consists of interstitial keratitis, notched incisors, and sensorineural hearing loss, is a hallmark set of symptoms in children with congenital syphilis. These children can also manifest other features such as saddle nose deformity, ectopia lentis, conjunctivitis, and scleritis.

### Treatment

The recommended treatment regimen for systemic syphilis infection involves an administration of aqueous crystalline penicillin G (100,000-150,000 units/kg body weight/day administered as 50,000

units/kg body weight/day) by IV every 12 hours during the first seven days of life and every eight hours after that for 10 days or Procaine penicillin G 50,000 units/kg body weight/day IM once single dose for 10 days. Benzathine penicillin G 50,000 units/kg body weight/day IM once single dose for 10 days can be administered for neonates with possible or less likely congenital syphilis.<sup>14</sup> Infants who experience allergic reactions may undergo desensitization treatment before the penicillin G regimen. Due to its efficacy and widespread availability, penicillin G is administered in most congenital syphilis cases. Ceftriaxone can be considered in the event of penicillin shortage with expert consultation and serologic testing.

In addition to penicillin, the ophthalmic manifestations of congenital syphilis may require additional treatment. Topical steroids may be used for the treatment of interstitial kera-

titis; however, their use for uveitis and scleritis isn't currently recommended by the CDC, as there's no demonstrated evidence of benefit.<sup>7</sup> The role of corticosteroids and immunosuppressants is also unclear in patients with other types of severe ocular inflammation or macular edema. Surgical procedures may be necessary to manage rare cases of cataracts and secondary glaucoma due to ocular inflammation. As always, pediatric ophthalmologists should look to correct any refractive errors and treat possible amblyopia.

### Mitigating Spread and Increasing Detection

Penicillin is an effective method of treating congenital syphilis once the diagnosis has already been confirmed; however, any meaningful reduction in overall rates will require increased prevention of syphilis before it can infect the fetus. A vast majority of congenital syphilis cases

are a partial result of inadequate screening and treatment of the birth mother during pregnancy.<sup>15</sup> Test timing and regularity are crucial—a greater frequency of screenings throughout pregnancy increases the likelihood of identifying late-presenting instances of infection. Sufficient prenatal testing and treatment will significantly reduce overall congenital infection while also narrowing gaps that exist between geographic and racial groups.<sup>16,20</sup>

The absence of characteristic symptoms in latent infection further complicates the diagnosis of congenital syphilis. In the context of ocular manifestations, *T. pallidum* spirochetes may persist in the aqueous fluid and lens cortex, and while rare, the infection may remain asymptomatic until reactivated to invade surrounding structures such as the cornea, uvea and retina.<sup>17</sup> Latency may persist for decades, with some

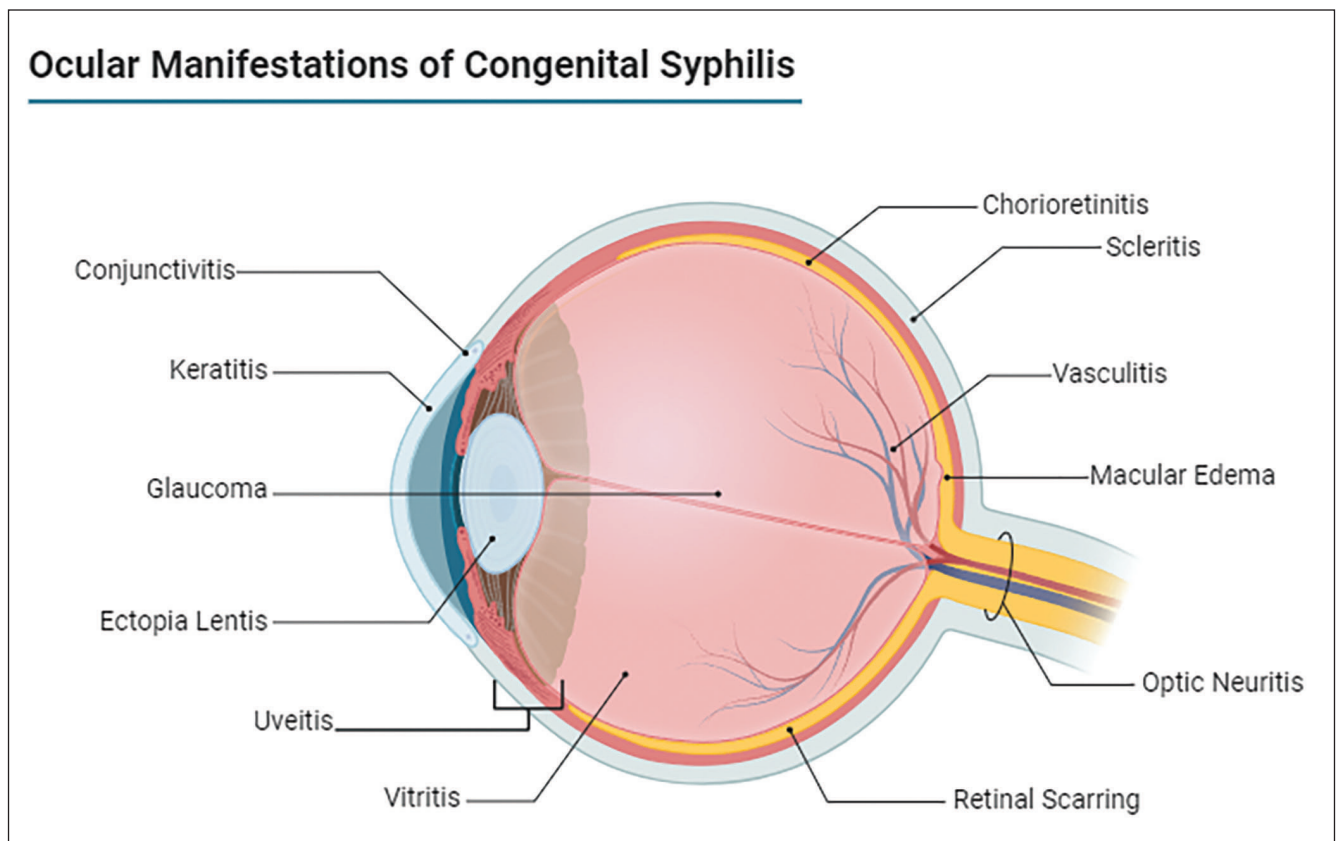


Figure 5. Ocular manifestations of congenital syphilis. Created with BioRender Software.

### HELPFUL RESOURCES FOR PRACTICING CLINICIANS

- For reporting cases of congenital syphilis to public health boards and information officers, a customizable template for congenital syphilis health alerts is available at <https://www.cdc.gov/sti/php/sti-program-resources/health-alert-template-for-congenital-syphilis.html>.
- Refer to the document found at <https://www.cdc.gov/std/treatment-guidelines/congenital-syphilis.htm> for varying course of management and in-depth treatment plans based on the degree of suspicion for congenital syphilis in mothers and neonates.
- Lastly, reporting methods for public health agencies in all 50 states and contact information and/or links to forms are available at <https://docs.google.com/spreadsheets/d/1bZHLyxLxmS3IbVTi0oGgh6xV9VafLoGthgA7fYVZdPI/edit?usp=sharing>.

patients unaware of congenital infection until cataract surgery results in postoperative inflammation of the anterior eye.<sup>16,18</sup> Therefore, ophthalmologists should always keep an eye out for various social risk factors associated with congenital syphilis, including maternal sexual history in the at-risk demographic.

Ophthalmologists can help curb the growing trends of congenital syphilis in their everyday practice by communicating findings to pediatricians, related specialists and public health agencies. Notifying the patient’s pediatrician is especially critical in the treatment process, allowing for the coordination of a multi-specialty team to address the systemic sequela of congenital syphilis infection.

### The Takeaway

Syphilis rates have rapidly risen over the last five years. Congenital syphilis rates are significantly elevated in comparison to other stable or declining sexually transmitted infections. Congenital syphilis is most prevalent in the southern and western United States, particularly among Indigenous, Latino and Black populations.

Comprehensive physical exams and a detailed history should be obtained for all infants with sus-

pected maternal history of syphilis infection, as standard antibody tests may not detect infection during the gestational period. If suspicion of congenital syphilis is high, perform ocular exams to evaluate for the following: chorioretinitis and pigmentary chorioretinopathy (“salt and pepper type”); congenital syphilitic keratouveitis; secondary glaucoma; cataracts, interstitial keratitis; and optic neuritis/atrophy.

Penicillin G (50,000 units/kg body weight/day) is the principal treatment for congenital syphilis. Dosing is determined based on the likelihood of syphilis infection; however, the most effective method of combating congenital syphilis rates remains preventative screening during pregnancy. ◀

1. Wang X, Liao L, Yang X, et al. Ocular syphilis: A comprehensive review. *Transl Vis Sci Technol* 2022;11:5:547.
2. Centers for Disease Control and Prevention. Newborn syphilis cases increase, and public health officials urge awareness. 2023.
3. Salinas J, Day J, Ochoa R, et al. The role of screening for congenital syphilis in prenatal care. *BMC Public Health* 2020;20:789.
4. Pardo M, Schmitz M, Pizones J, et al. Trends in congenital syphilis and implications for prevention. *Pediatr Res* 2022;92:3:496-502.
5. Zhang Y, Wang Q, Zhang L, et al. Syphilis epidemiology and treatment recommendations. *Pathogens* 2022;11:5:547.
6. Centers for Disease Control and Prevention. 2022 STD Surveillance Report. 2023.

7. Koundanya VV and Tripathy K. Syphilis ocular manifestations. *StatPearls*. Updated August 25, 2023.
8. Centers for Disease Control and Prevention. Quick reference handbook for congenital syphilis surveillance.
9. Administration for Children and Families. American Indians and Alaska Natives: Numbers and demographics. 2023.
10. Miller S, Dempsey A, Darrow A. The effect of National Health Service Corps on health outcomes. *Med Care* 2021;59:10:893-900.
11. Centers for Disease Control and Prevention. Treatment guidelines for congenital syphilis.
12. Taha T, Al-Mahfoudh R, Abbas A, et al. Epidemiology of syphilis and its implications for treatment. *Lancet Infect Dis* 2020;20:4:450-458.
13. Kankam H, Bafor A, Arhin S, et al. Increasing trends in congenital syphilis. *BMC Pregnancy Childbirth* 2022;22:104.
14. Centers for Disease Control and Prevention. Treatment guidelines for congenital syphilis.
15. Centers for Disease Control and Prevention. MMWR: Congenital syphilis in the United States. *MMWR Morb Mortal Wkly Rep* 2023;72:46:e1-e4.
16. Whittington J, Churilla A. Syphilis diagnosis and treatment in adults. *J Am Board Fam Med* 2008;21:3:185-192.
17. Johnson L, Mckelvey K. Epidemiology of congenital syphilis. *Pediatr Infect Dis J* 1992;11:4:343-347.
18. Paik J, Yoon S, Kim J, et al. The role of molecular methods in diagnosing congenital syphilis. *BMC Ophthalmol* 2023;23:212.
19. Centers for Disease Control and Prevention. Effects of HIV, STDs, TB, and hepatitis on pregnancy. Accessed September 19, 2024. Available from: [https://www.cdc.gov/pregnancy-hiv-std-tb-hepatitis/effects/?CDC\\_AAref\\_Val=https://www.cdc.gov/nchhstp/pregnancy/effects/syphilis.html](https://www.cdc.gov/pregnancy-hiv-std-tb-hepatitis/effects/?CDC_AAref_Val=https://www.cdc.gov/nchhstp/pregnancy/effects/syphilis.html).
20. Centers for Disease Control and Prevention. STD surveillance 2022: Figure 1. Accessed September 19, 2024. Available from: <https://www.cdc.gov/std/statistics/2022/figures/disp-1.htm>.

### ABOUT THE AUTHORS



**Mr. Park and Mr. Nguyen** are medical students at the University of Oklahoma College of Medicine.



**Dr. Yanovitch** is a clinical professor and director of medical student education at the Dean A. McGee Eye Institute in Oklahoma City. They have no related financial disclosures.



**Correspondence:**  
 Tammy Yanovitch, MD, MHS  
 608 Stanton L. Young Boulevard  
 Oklahoma City, Oklahoma  
 Phone: 405-271-1094  
 Email: [tammy-yanovitch@dmei.org](mailto:tammy-yanovitch@dmei.org)

# TRANSPLANT TECHNIQUES IN THE PIPELINE

In addition to benefiting U.S. patients, these new techniques would address the tissue shortage in other countries.

**MICHELLE STEPHENSON**  
CONTRIBUTING EDITOR

In recent years, endothelial transplant methods have replaced penetrating keratoplasty for the treatment of Fuchs' endothelial dystrophy, and several new transplant techniques are currently in the pipeline. The hope is that these new techniques will have a global impact. "In the United States, we're very fortunate. We have an excellent eye banking system; we don't have tissue shortages. The rest of the world is a different story," says Kathryn Colby, MD, PhD, the Elisabeth J. Cohen Professor and Chairman of the Department of Ophthalmology at the NYU Grossman School of Medicine.

Sioux Falls, South Dakota's John Berdahl, MD, agrees, noting that the unmet need for endothelial cell transplants across the globe is enormous. "The United States has a healthy system of eye banks. Our limiting factor is the number of cornea transplant surgeons that we have. The problem abroad is that we don't have enough tissue to cover all the needs. What's exciting about these techniques is they

don't have to be one-to-one, meaning one corneal donor to one recipient. They can be manufactured corneas, manufactured drugs, or based on cell therapy cultures where one cornea could turn into hundreds or even thousands of corneal transplants. So, it allows the therapy to be delivered at scale and to provide for the global need for endothelial cell transplantation. Additionally, the surgical technique is not as delicate and specialized, so this should open the pathway for more surgeons to be able to perform these techniques," says Dr. Berdahl.

Dr. Colby adds that these new techniques would provide more specific treatments. "Now, we do endothelial keratoplasty instead of a full-thickness penetrating keratoplasty, which is what we did for Fuchs' in the 90s. It's great if we can do a less invasive, less extensive type of surgery that is less resource intensive. You can imagine that we might be able to develop a medication that prevents the endothelial cells from degenerating and prevents the need for any kind of surgical intervention. The advantage of the cultured cells is that they can potentially be used in the developing world

where there are tissue shortages. And if you had a cell suspension, it would probably be easier to transport if you were going internationally," she adds.

The new techniques fall into three categories. "First, there are cultured endothelial cells. Several companies are working on that. There's a company looking at basically an artificial endothelial layer that just acts as a barrier, and a number of companies are looking at medications that may enhance the success of Descemet's stripping only, which is where we just remove the central endothelium and let the peripheral host endothelium repopulate the central cornea. Those are the three major buckets," Dr. Colby says.

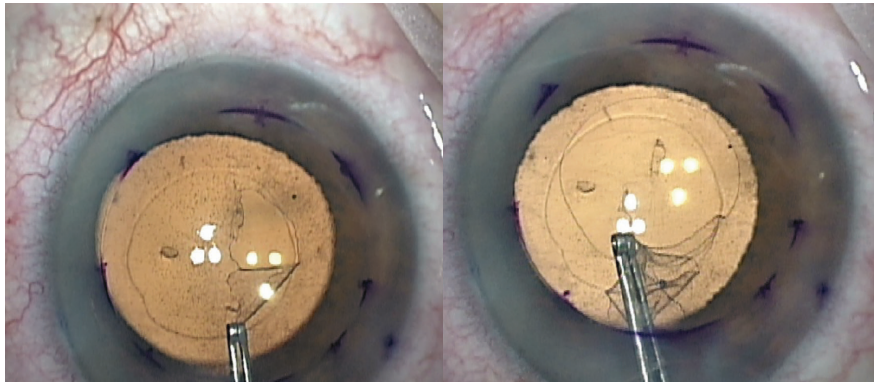
She adds that companies overseas are developing techniques. "There's a lot of interest in the disease. It's a very common condition. In fact, up to 4 percent of people in the United States have a mild form of it. Fewer need any intervention, but it tells us a lot about the biology of the cornea, which is also very interesting," she says.

## Cultured Endothelial Cells

Two new techniques being evaluated

*This article has no commercial sponsorship.*

**Dr. Berdahl** has a financial interest in Aurion, CorneaGen, Dakota Lions Sight & Health. **Dr. Colby** has no financial interests to disclose. **Dr. Mah** is a consultant to EyeYon.



Mark A. Terry, MD

**The initial part of the Descemet's Stripping Only procedure. Also seen is the pre-existing anterior capsulorhexis opening (left). The completed DSO procedure and the surgically detached disc of Descemet's membrane with compromised endothelial cells (right). The pre-existing capsulorhexis opening is also visible.**

by Aurion and Emmeccell fall into this category. According to Francis Mah, MD, who is in practice in La Jolla, California, Aurion's technology is *ex vivo* expansion of endothelial cells. "They take donor cells and expand them in culture. Then, investigators inject the donor cells into Fuchs' dystrophy patients who need a corneal transplant. Some positioning is needed. The patients need to lie face down so that the endothelial cells can attach to the posterior cornea," he says.

Dr. Mah explains that this technique started with Shigeru Kinoshita in Japan, who did groundbreaking research developing it. He performed an uncontrolled, single-group study involving 11 patients who were diagnosed with bullous keratopathy and had no detectable corneal endothelial cells.<sup>1</sup> Human corneal endothelial cells were cultured from a donor cornea. A total of 1×10<sup>6</sup> passaged cells (passaging refers to the removal of the medium and transfer of cells from a previous culture into fresh growth medium) were supplemented with a rho kinase (ROCK) inhibitor and were injected into the anterior chamber of the eye that was selected for treatment. After the procedure, patients were placed in a prone position for three hours. At 24 weeks after the cell injection, the researchers recorded a corneal endothelial cell density of more than 500 cells per mm<sup>2</sup> in all 11 treated eyes

and more than 1,000 cells per mm<sup>2</sup> in 10 of the 11 treated eyes.

"This technology was purchased by Aurion in the U.S.," Dr. Mah explains, "and they've done preclinical as well as the Phase II studies outside Japan. Now, they are doing a five-arm FDA trial. There are some specifics regarding why it needs to be a five-arm study. The technique that Kinoshita described used a ROCK inhibitor that is not currently FDA-approved in the United States. So, they're studying this technique with and without the ROCK inhibitor. It's pretty landmark stuff."

The second technique is Emmeccell, which is similar. "Emmeccell is unique in that, while it is also *ex vivo* expansion of endothelial cells, it uses nanoparticle magnets that are inserted into the cells in a proprietary fashion," says Dr. Mah. "They don't harm the cells at all. This company has also done an FDA clinical trial. As previously mentioned with the Aurion technology, the cells are injected into the anterior chamber. The patient then needs to look down at the floor, and just through gravitation, the cells are going to kind of float down and attach to the stroma. The patient needs at least two hours—maybe longer—in the face-down position. In the beginning, the Aurion technique required days face down. The endothelial cells with nano-magnets in the Emmeccell

technology tries to improve on the patient post-cell injection positioning. Patients must wear a magnetic facemask, kind of like a sleep mask with magnets. So, the positioning for the patients becomes a much easier proposition. The patients wear goggles with the magnets, and the magnets actually pull the endothelial cells to the posterior stroma to attach. It helps solve one of the potential downsides of the Aurion technology."

He notes that Emmeccell doesn't use a ROCK inhibitor, which is another potential advantage. "The Emmeccell technology with the magnets just helps attach the cells to the posterior stroma. The Kinoshita technology, Aurion's technology, is FDA-approved in Japan, so they already have a lot of regulatory data and information available for that technology. So, they're a little further along in terms of the regulatory pathway than Emmeccell. But, at least in the United States, both have completed a Phase I clinical trial," he explains.

According to Dr. Mah, one of the advantages of Aurion and Emmeccell is that they're injectable, so the procedure could potentially be performed in the office. "There is a small incision with DSEK, DMEK and DSO, but this would be even smaller, potentially, so it would be even safer. Additionally, while it may be initially cost-prohibitive, the costs will come down, and the technology will be able to be used by others where eye banking or corneal transplantation isn't readily available due to lack of tissue or surgeons. This might be a way to treat corneal blindness in areas that need corneal transplantation," he adds.

Another potential benefit is that the rates of rejection could possibly be minimal to none. "Right now, those two technologies really seem to work best in Fuchs' patients, but you might imagine where the technology grows as we learn more about those two technologies, such that we can do other patients who need corneal transplantation due to any endothelial decompensation, not just Fuchs'



patients,” Dr. Mah says.

### Artificial Endothelial Cell Layer

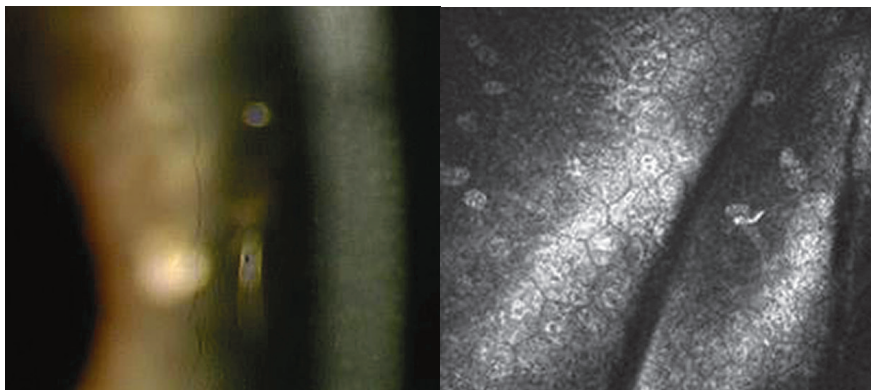
EndoArt corneal artificial endothelial layer (EyeYon Medical) is the first synthetic implant to treat corneal edema. It attaches to the back of the corneal surface, preventing the transfer of fluids into the cornea and inhibiting the build-up of fluid. The procedure is performed through small incisions.

“EyeYon is an Israeli company, and EndoArt has been used outside of the United States in well over 100 cases,” Dr. Mah explains. “Essentially, it’s like a contact lens. The surgeon makes an incision just like for DSEK or a DMEK and implants EndoArt after removal of the Descemet’s membrane. It has a certain base curve that should shape to the posterior cornea. So, there is a possibility that you could implant it upside down, but they’ve got little markings on it to prevent this complication. You place an air bubble in the eye, and you place a suture through the superior part of the cornea and implant to help with attachment. Basically, the endothelial cells pump fluid out of the stroma and the cornea. This technology prevents fluid from getting into the stroma, so it helps prevent the swelling that lack of endothelial cells produces.”

The company has had to adjust the size of the implant. “They started with a larger size in preclinical and early clinical studies and found that it actually prevented too much fluid from going into the cornea. It also prevented some of the nutrients from the aqueous from entering the cornea. So, they made the implant a little smaller so that nutrients and some amount of fluid can get into the cornea. And now they’re going through the United States’ regulatory process to see if they can get this FDA-approved here,” Dr. Mah adds.

The EyeYon technology wouldn’t require the use of long-term steroids because there’s no chance of rejection. “You would need a short course of steroids in the beginning, probably less than six months,” Dr. Mah adds.

Kathryn Colby, MD



A slit lamp photo (left) and its corresponding endothelial image from a DSO patient.

“And because there is no corneal tissue, again, this would be very easily used in countries where there’s a lack of eye banking or the infrastructure for corneal tissue is not as robust. This technology may not replace first-line DSEKs and DMEKs, especially, for example, in the United States, but it would give another option for patients who have run out of other options due to their immune system and rejection or other issues with the eye.”



**Emmecell is unique in that, while it is also *ex vivo* expansion of endothelial cells, it uses nanoparticle magnets that are inserted into the cells ...”**

—Francis Mah, MD



A recent case report found that “this new device could serve as an alternative to lamellar endothelial corneal transplantation in cases where tissue rejection has occurred and is highly likely to recur. The technique is simple, and the deswelling effect on the cornea persisted, although the visual results require further validation in patients with a higher visual potential.”<sup>2</sup>

The patient in this case study presented with pseudophakic bullous keratoplasty after a history of two

rejected PKs and one rejected Descemet’s stripping automated keratoplasty. An artificial endothelial layer was implanted and remained fully attached for a follow-up period of 12 months.

### Medications to Enhance DSO

Multiple companies are currently studying medications to facilitate DSO healing. CoA is investigating ripasudil for this purpose, and Dr. Colby is the chair of the study. “We’ve completed the Phase II study, which was positive, and now we are in Phase III trials,” she says. “One of them has virtually completed enrollment; we’re not accepting any more people for screening. And the other one is about three-quarters enrolled. So, we expect to have results within the next year or so. That’s probably the furthest along of the medical treatments. Another company, Trefoil, is looking at a bioengineered fibroblastic growth factor. Additionally, a company called Design Therapeutics is developing a small molecule to inhibit transcription of the repeat expansion that underlies most of Fuchs’ in the United States. Right now, they’re doing a natural history study to try to determine the best biomarker for when they have the product that they can use in patients with Fuchs’ endothelial dystrophy.” ◀

1. Kinoshita S, Koizumi N, Ueno M, et al. Injection of cultured cells with a ROCK inhibitor for bullous keratopathy. *N Engl J Med* 2018;378:995-1003.

2. Rens J, Krolo I, Koppen C, et al. Artificial endothelial layer implantation after multiple failed keratoplasties. *Cornea* 2024;43:6:790-794.

# MANAGING IRREGULAR ASTIGMATISM

An etiology-based approach is key when addressing this complex refractive situation.

**CHRISTINE YUE LEONARD**  
SENIOR ASSOCIATE EDITOR

One of the more frustrating refractive challenges for both surgeons and patients, corneal irregular astigmatism can arise from a variety of factors, leading to unpredictable visual outcomes. The irregular curvature of the cornea not only affects visual clarity but also increases higher-order aberrations such as coma and trefoil, resulting in discomfort from glare and halos around light sources. Treatment strategies must be tailored to address the specific underlying causes in order to achieve the best possible results.

Here, experts delve into the intricacies of corneal irregular astigmatism, exploring its causes and the management approaches that enhance patient outcomes.

## Highly Irregular

Brian M. Shafer, MD, of Shafer Vision Institute in Plymouth Meeting, Pennsylvania, explains that corneal irregular astigmatism is defined topographically when the meridians of astigmatism aren't perpendicular to each other. "This results in reduced

best corrected visual acuity that's not correctable with glasses or soft contact lenses," he says. "In regular astigmatism, the meridians are perpendicular to each other, and it's correctable with optical lenses in front of the eye."

Clinicians rely heavily on corneal topography when assessing irregular astigmatism. "Placido disc imaging is a great technique for assessing the corneal surface, in addition to elevation mapping like the Pentacam," says Jonathan Rubenstein, MD, Chairman of Ophthalmology at Rush University Medical Center in Chicago. "Treatment goals vary, depending on the degree of irregular astigmatism and the treatment endpoint. Is the surgeon looking for some degree of improvement in vision or are they looking to provide a patient with functional uncorrected visual acuity? Preoperatively, surgeons need to normalize the cornea enough to make it amenable to astigmatic treatment at the time of cataract surgery. For example, in cataract surgery, we might aim to normalize the cornea so it can be treated with a toric lens that you couldn't offer before.

"It's important to discuss treatment options with the patient and explain

how far you can go with treatment," he continues. "Significant irregular astigmatism due to severe scars from trauma or infections often can't be treated without keratoplasty. Treatment options depend on the degree of corneal pathology."

## Key Causes

A variety of conditions and situations can contribute to abnormal corneal shape and irregular astigmatism. Here are some of the causes commonly seen in clinic:

- **Corneal ectasia.** Ectatic conditions such as keratoconus (*Figure 1*), pellucid marginal degeneration and post-LASIK ectasia are among the most common etiologies for irregular astigmatism, characterized by irregular thinning, steepening and bulging of the cornea.

- **Scarring.** Scarring may result from events such as trauma or old infections such as herpes, bacterial infections or fungal infections. "If you have a scar on the cornea from a prior infection, that area becomes very flat after the infection heals and the scar sets into place," Dr. Shafer explains.

"It's important to realize that it's really not the opacity from the scar that tends

This article has no commercial sponsorship.

Dr. Rubenstein is a consultant for Alcon. Dr. Shafer is a consultant for CorneaGen, which cuts CTAK tissue, and Glaukos. Dr. Jacobs and Dr. Blitzer have no related financial disclosures.

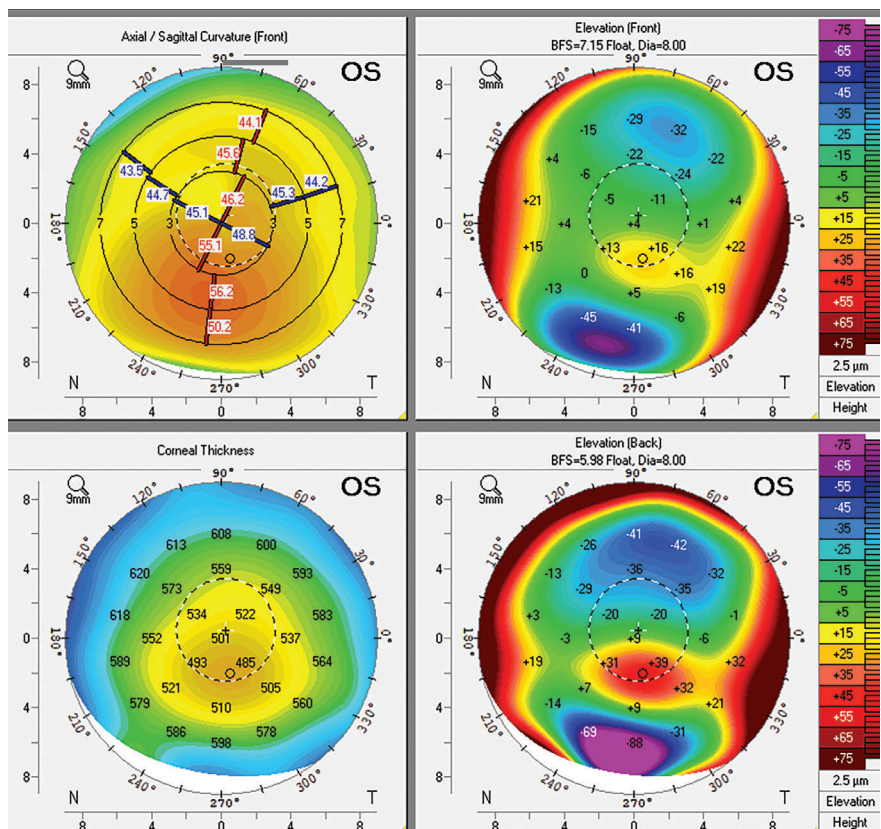
to decrease vision, but rather the shape change, or irregular astigmatism induced by the scar that causes decreased visual acuity,” Dr. Rubenstein notes.

• **Prior RK.** Radial keratotomy flattens the central cornea to improve vision by creating multiple incisions. Irregular astigmatism can result from the RK incision scars. Though it’s not performed anymore, having fallen out of favor in the wake of newer, more predictable refractive procedures like LASIK, Andrea Blitzer, MD, of NUY Langone’s Department of Ophthalmology, says that “many patients who had RK in the 80s are now experiencing hyperopia, astigmatism or scarring of the cornea, causing further astigmatism.”

• **Ocular surface disease.** “Various disease entities can damage the tear film,” Dr. Rubenstein says. “Ocular surface disease, and more specifically dry eye, is probably the most common cause of irregular astigmatism in my practice (Figure 2). An irregular surface causes degraded optics, poor visual acuity and the inability for the accurate assessment of corneal power that’s required for lens implant calculations before cataract surgery.

“With ocular surface disease, we’re looking at three components of the tear film which may be altered: the aqueous component; the oil component; and the mucus component. The aqueous component can be altered in all sorts of conditions that cause dry eye, from common causes such as aging and reduced aqueous production to decreased blink rate related to driving, or staring all day at computers, cell phones and TVs.

“Chronic meibomian gland dysfunction affects the oil component of the tear glands,” he continues. “Anything that can affect the ability to produce a normal oil layer on the outside of the tear film can result in chronic ocular surface disease from evaporative dry eye. The third component is mucin. Mucin comes from goblet cells in the conjunctiva. Scarring of the conjunctiva, for example, leads to decreased goblet cell density. This leads to decreased mucus formation, which destabilizes the tear film.”



**Figure 1. Irregular astigmatism associated with keratoconus, with inferior steepening and thinning.**

• **Epithelial abnormalities.** Conditions such as epithelial basement membrane dystrophy can lead to irregular astigmatism, though typically not to the same degree as something like ectasia or scarring. “In EBMD, there’s redundancy in the basement membrane and the epithelium is irregular, which on its own can create some irregular astigmatism,” Dr. Shafer says.

• **Salzmann’s nodules.** “These can grow anywhere on the cornea,” he says (Figure 3). “They typically start in the peripheral or mid-peripheral zones and lead to irregular astigmatism.”

• **Pterygium.** “A pterygium typically grows in from the nasal aspect of the conjunctiva and may cross into the central visual axis, creating flattening in that area and inducing irregular astigmatism,” he says (Figure 4).

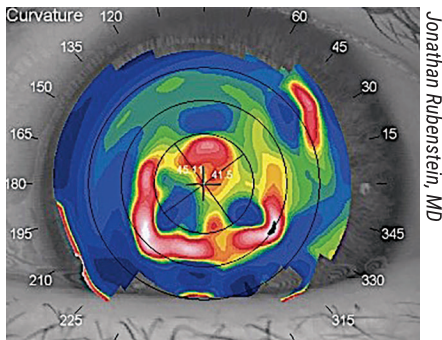
### Optical Strategies

If the patient has a low amount of irregular astigmatism, spectacles are a non-invasive treatment worth trying. However, clinicians say it’s common for

patients to remain unsatisfied with this management approach. When it comes to lens-based strategies for irregular astigmatism, hard contact lenses<sup>1</sup> and pinhole IOLs are the go-to for many doctors.

“A soft contact lens might neutralize some irregular astigmatism, if it’s a mild amount, and particularly if it’s a lens with a more rigid modulus, such as a silicone hydrogel lens. But typically, irregular astigmatism requires a rigid lens of some sort,” says Deborah S. Jacobs, MD, of Massachusetts Eye and Ear.

“I think most corneal specialists have been in a situation where they originally thought a patient had such a large degree of irregular astigmatism or corneal scarring that the only treatment was keratoplasty, but instead found that when the patient was fitted with a scleral contact lens, they achieved an excellent level of visual acuity,” Dr. Rubenstein says. “The advances that have occurred in hard contact lens design—with computer programs that design the contact lens fit to the development of



**Figure 2. Dry eye is one of the most common and fixable causes of irregular astigmatism. Treatments targeting tear production and the lids may help, depending on the type of dry eye.**

scleral lenses—have really helped to treat irregular astigmatism and have offered many potential surgical patients a non-surgical alternative treatment.”

Scleral lenses and RGP lenses work by masking the irregular surface of the cornea. “The refractive element of the cornea is really the cornea-tear film interface,” explains Dr. Shafer. “Functionally, [these lenses] create a normal surface that can bypass the irregularity and allow the patient to see more clearly when you correct their manifest refraction as well.”

Scleral lenses are useful options for rehabilitating eyes with conditions such as keratoconus, pellucid marginal degeneration and after penetrating keratoplasty. “They’re more predictable than incisional surgery to correct irregular astigmatism and may be more appropriate for some patients than PRK or LASIK,” says Dr. Jacobs.

These lenses are typically used as a treatment for bilateral problems. Dr. Jacobs says that it’s rare for patients to tolerate a rigid lens in just one eye. “If the irregular astigmatism is the after effect of trauma or surgery or an infection, and it’s affecting only one eye, then the patient is much less likely to accept or adapt to wearing one contact lens,” she says. “In these cases, surgical or laser approaches make more sense. That said, a rigid scleral lens might fare better [than a rigid corneal lens] if it’s well-fitted.”

Dr. Rubenstein adds that hard contact lenses are also an important diagnostic

modality to assess the effects of irregular astigmatism on visual acuity, since the irregularities can be masked with a hard contact lens. “You can place a hard contact lens on the patient in the office and see if that improves their acuity,” he says.

In addition to rigid lenses, surgeons now have the opportunity to manage irregular astigmatism with a small-aperture intraocular lens implant, the Aphthera lens (formerly the IC-8). “This lens works via the pinhole principle,” Dr. Shafer says. “It bypasses some of the irregularity by filtering out the scattered light and only letting through the focused light. This can help correct some of the aberrations induced from irregular astigmatism.”

### Ectasia

Before turning to optical correction for the irregular astigmatism induced by ectatic conditions such as keratoconus, pellucid marginal degeneration and post-LASIK ectasia, surgeons often perform corneal collagen cross-linking. “This procedure strengthens the cornea to prevent it from progressing and becoming more cone-shaped, but it doesn’t fix the irregular astigmatism that’s already occurred—it’s more of a way to halt further progression,” Dr. Blitzer says.

The decision to cross-link before or after a procedure “is a philosophical question that will differ from surgeon to surgeon,” Dr. Shafer says. “My personal approach at this point in time is to cross-link the patient first, wait six months, and then place ring segments, just because we know that the cornea does change a little bit after cross-linking. I like to see it stabilized before doing something like [ring segments]. However, there are surgeons who perform ring segments first and then cross-link the patient later. I think that’s totally reasonable also.”

Dr. Blitzer says she prefers to cross-link the patient as soon as indicated. “It’s really important to halt the progression, so as soon as I see a patient who’s progressing with keratoconus and they have no contraindication to getting

cross-linked, I recommend that as an early procedure.

“After cross-linking, I recommend contact lenses for many of these patients as well,” she continues. “Much of the irregular astigmatism that we see, including with keratoconus, can be improved with RGP lenses and scleral lenses. These can provide good quality vision.”

Some corneas are too cone-shaped for contact lenses or may need additional flattening before glasses or contact lenses can be used to correct the refractive error. Procedures involving implantable corneal ring segments flatten the cornea and may help stave off the need for a future transplant procedure.

Some options include artificial implants such as Intacs, corneal allogenic intrastromal ring segments and a new procedure called corneal tissue addition keratoplasty. “Artificial ring segments, which are made out of PMMA, are placed underneath the area of the ectasia to reinforce it and help correct irregular astigmatism,” Dr. Shafer says. He notes that implant extrusion is one complication to be aware of, which can occur with further stromal thinning or ring migration and leads to chronic pain and discomfort for some patients.

The corneal allogenic intrastromal ring segments procedure, developed by Soosan Jacob, MS, FRCS, DNB, employs donor corneal tissue instead of synthetic implants to flatten the cone and improve vision. Since 2018, customized CAIRS has tailored the tissue based on the patient’s unique features, including keratometry and pachymetry, allowing for improved visual outcomes.<sup>2</sup>

Corneal tissue addition keratoplasty is an emerging allogenic inlay procedure for keratoconus. “Custom femtosecond laser-cut tissue segments, created based on a patient’s Pentacam or tomography imaging, are implanted into a femtosecond laser-cut channel in the host cornea,” says Dr. Shafer. “The goal is to bolster some of the area that’s irregular so you can move it

more centrally and make the meridians more perpendicular to each other, therefore making the astigmatism more correctable with glasses or soft contact lenses.”

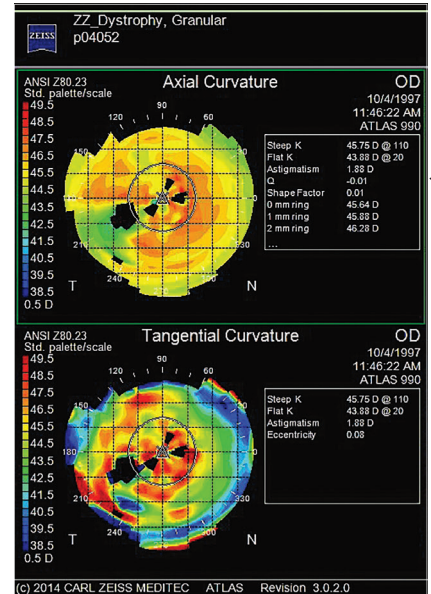
The results of a prospective CTAK clinical trial (NCT02649738)<sup>3</sup> published last year in the *Journal of Cataract and Refractive Surgery* report improved visual acuity and topography in patients with keratoconus and ectasia. The single center study involved 21 eyes of 18 patients, each of whom received a custom-cut tissue inlay of preserved corneal tissue. The study reported a significant improvement in uncorrected distance visual acuity from 1.21 ±0.25 logMAR to 0.61 ±0.25 logMAR (Snellen equivalents: 20/327 to 20/82). Corrected distance visual acuity improved significantly from 0.62 ±0.33 to 0.34 ±0.21 logMAR (Snellen equivalents: 20/82 to 20/43). Average MRSE improved significantly as well, and the researchers reported that 20 eyes gained more than two lines of UDVA, 10 eyes gained more than six

lines and no eyes grew worse. Twelve eyes gained at least two lines of CDVA and one eye worsened by more than two lines. At six months, the researchers reported an average Kmean flattening of -8.44 D ( $p=0.002$ ), Kmax flattening of -6.91 D ( $p=0.096$ ) and mean Kmaxflat of -16.03 D.

Dr. Shafer recently completed his first CTAK procedure. “Procedurally, it’s similar to doing an intracorneal ring segment implantation, but requires a bit more nuance since it’s not as rigid of a segment,” he explains. “I’m excited to be offering this to more patients.”

When a patient’s ectasia is too severe for options such as crosslinking or ring segments, a cornea transplant may be necessary. “Keratoconus does very well with deep anterior lamellar keratoplasty, because typically, unless the patient has had an episode of acute hydrops, the posterior cornea is relatively normal,” Dr. Blizter says. “A DALK is preferred, but a penetrating keratoplasty is another reasonable option.”

According to retrospective study of



Jonathan Rubenstein, MD

**Figure 3. Irregular astigmatism resulting from Salzmann's nodules.**

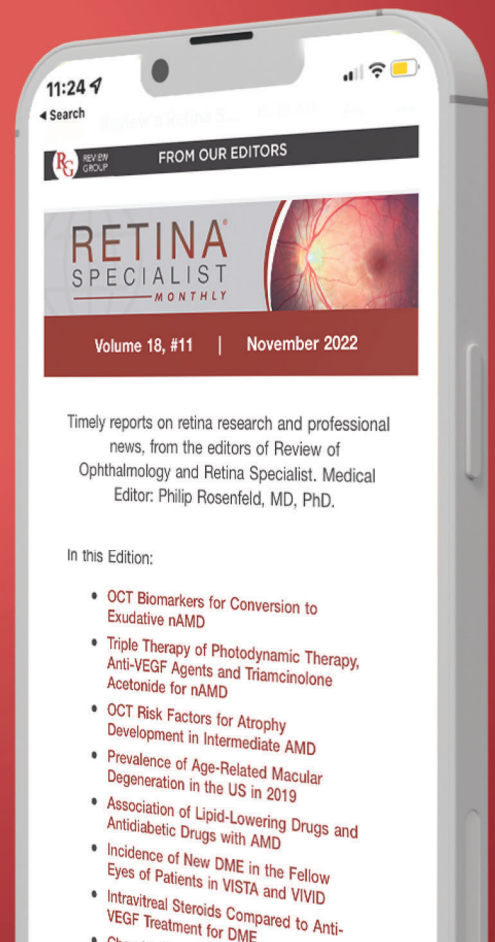
long-term keratoplasty outcomes for keratoconus, DALK resulted in higher endothelial survival and lower risk of postoperative ocular hypertension than PKP.<sup>4</sup>

*“Don’t Miss Your Monthly Dose”*

# RETINA<sup>®</sup> SPECIALIST MONTHLY

Timely reports on retina research and professional news, from the editors of *Review of Ophthalmology* and *Retina Specialist*.

Medical Editor: Philip Rosenfeld, MD, PhD.



### Corneal Scars

“If a scar is causing astigmatism, it can be treated with either a laser or surgical modality,” Dr. Rubenstein says. “If it’s a superficial scar, it can be treated with a mechanical superficial or phototherapeutic keratectomy. If it’s deeper, it might warrant an anterior lamellar keratoplasty; if it’s deeper still, a deep lamellar keratoplasty. If the entire cornea is affected, then sometimes you might have to do a penetrating keratoplasty.”

For corneal ulcers and scars from prior infections, Dr. Blitzer urges caution when performing procedures such as topography-guided LASIK or PRK. “I’d hesitate to do any ablative surgery on those eyes,” she says. “However, these patients would still be good potential candidates for contact lenses and for DALK or PKP if needed.”

### Radial Keratotomy

Today, clinicians are managing the late-stage complications of RK. “Some patients do well with contacts, but many of them are also at cataract surgery age, and if their astigmatism in the center of the cornea is relatively regular, they may do well with a toric intraocular lens,” Dr. Blitzer says. “The Aphera is another option.”

“The ideal patient [for the Aphera lens implant] has irregular corneal astigmatism, either from perhaps a previous keratoplasty or keratoconus,” Dr. Rubenstein says. “The best patients seem to be those who had previous radial keratotomy. Radial keratotomy can cause all sorts of funny aberrations, especially those who had RK years ago with more and longer incisions. I’ve found that the Aphera is a real advantage for these patients.”

### Ocular Surface Disease

Dry eye is a common culprit for irregular astigmatism, and it’s important to treat the root cause. “You have to figure out which part of the ocular surface is affected and what the cause is,” Dr. Rubenstein says. “We’re basically talking about tear film deficiency. So, you have to break it down into its components. Is it an aqueous deficiency? Is it a mucin

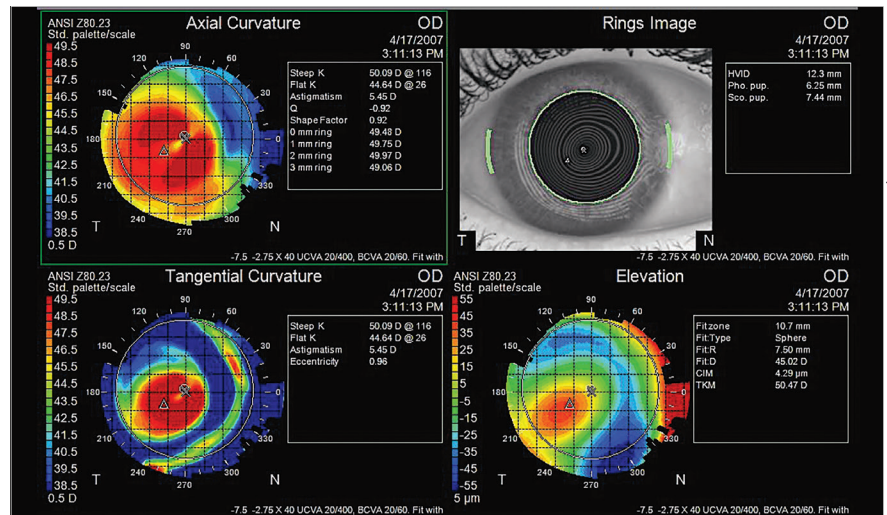


Figure 4. Pterygium in the right eye of a patient.

or mucus deficiency? An oil deficiency? How you treat it depending on the etiology.

“If it’s more aqueous-deficient, try to increase use of artificial tears or anti-inflammatory drops,” he continues. “You can stimulate tear production, perhaps with some of the newer entities like Tyrvaya, for example, or you can block tear outflow with punctal occlusion in various ways. If it’s more of an oil-related etiology, options include performing good eyelid hygiene or using different approaches to physically remove the excess eyelid oil and debris. Some treatments mechanically try to evacuate the oil glands. If it’s a mucus problem, then it’s usually due to conjunctival scarring which can be harder to treat other than with replacement of a more viscous artificial tear.”

### Other Corneal Conditions

“Other pathological entities that cause irregular astigmatism are epithelial basement membrane disorders, such as epithelial basement membrane dystrophy or epithelial basement membrane abnormalities,” says Dr. Rubenstein. “These lead to an irregular basement membrane and an overlying irregular corneal epithelium that’s thrown into slight folds, resulting in an irregular surface.” These patients are treated with debridement plus superficial keratectomy with diamond burr polishing.

“If the irregularity is related more to

corneal roughness of the surface than a specific dioptric optical feature, one option would be a phototherapeutic keratectomy, which can serve to regularize an irregular surface,” Dr. Jacobs says. “A customized excimer ablation or topography- or wavefront-guided ablation are other options.”

Like PTK, superficial keratectomy also addresses a variety of ocular surface disorders,<sup>5</sup> including EBMD.<sup>6</sup> Salzmann’s nodules are another condition benefiting from superficial keratectomy. “The epithelium is removed, and the Salzmann’s nodules are peeled away from Bowman’s layer,” Dr. Shafer says.

Dr. Shafer adds that “for a pterygium, excise the pterygium and remove it from the cornea. Use either a conjunctival autograft or an amniotic membrane graft to fill in the area over top of the sclera.”

1. Noufal KH, Babu SP. Short-term visual outcome with sclero-corneal contact lens on irregular cornea. *Saudi J Ophthalmol* 2023;37:1:43-47.
2. Jacob S, Agarwal A, Awwad ST, et al. Customized corneal allogenic intrastromal ring segments (CAIRS) for keratoconus with decentered asymmetric cone. *Indian J Ophthalmol* 2023;71:12:3723-3729.
3. Greenstein SA, Yu AS, Gelles DJ, et al. Corneal tissue addition keratoplasty: New intrastromal inlay procedure for keratoconus using femtosecond laser-shaped preserved corneal tissue. *J Cataract Refract Surg* 2023;49:7:740-746.
4. Borderie VM, Georgeon C, Sandali O and Bouharaoua N. Long-term outcomes of deep anterior lamellar versus penetrating keratoplasty for keratoconus. *Br J Ophthalmol* 2023;108:1:10-16.
5. Salari F, Beikmarzhehi A, Liu G, et al. Superficial keratectomy: A review of the literature. *Front Med (Lausanne)* 2022;9:915284.
6. He X, Huang AS, Jeng BH. Optimizing the ocular surface prior to cataract surgery. *Curr Opin Ophthalmol* 2022;33:1:9-14.

# PLATEAU IRIS AND ANGLE CLOSURE MANAGEMENT

Experts offer their perspectives on how to approach narrow angles and plateau iris configuration to mitigate glaucoma risk.

LIZ HUNTER  
SENIOR EDITOR

**E**arly identification and treatment of primary angle closure suspects are crucial steps to help lower patients' risk of developing glaucoma. The anatomical nature of their narrow angles will influence how they can be managed and how they respond, particularly if the patient has a plateau iris configuration. We spoke with several glaucoma specialists who offered advice on the clinical definitions and confirmation of narrow angles and plateau iris, treatment options and what to expect in long-term monitoring of these patients.

## Differentiating Narrow Angles And Plateau Iris

The first observation a comprehensive ophthalmologist makes is during a gonioscopy exam. They'll notice the trabecular meshwork isn't visible for at least half of the angle.

"For an angle to be classified as narrow, it must be occludable in at least two quadrants," says Lauren S. Blieden, MD, associate professor of ophthalmology at the Cullen Eye Institute,

Baylor College of Medicine and Texas Children's Hospital in Houston. "This scenario describes what we refer to as primary angle closure suspect. In the case of primary angle closure the situation is similar, but patients also exhibit elevated intraocular pressure or findings of synechial closure or peripheral anterior synechiae on gonioscopy. Symptoms may vary from subtle complaints like new headaches with vision changes, such as halos around lights, to more pronounced manifestations like pain with blurred vision or full-blown acute angle closure attacks."

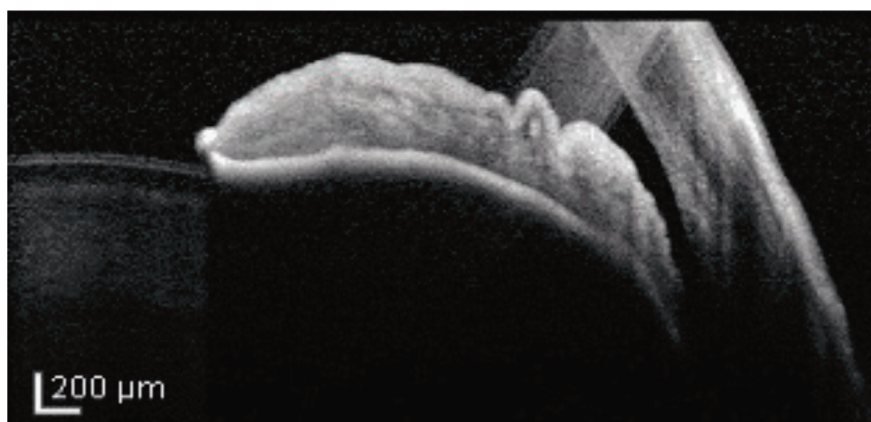
The most severe condition in this spectrum is primary angle closure glaucoma, where there's demonstrable damage to the optic nerve, anatomically or functionally characterized by visual field changes. "When distinguishing between narrow angles and plateau iris, it's important to recognize that they fall on a clinical spectrum, with overlapping characteristics," Dr. Blieden says.

Plateau iris will have a different appearance on gonioscopy. "Rather than exhibiting a typical bombe configuration—where the iris billows forward and occludes the pupil in primary

angle closure—plateau iris displays more of an anterior rotation or anterior displacement of the ciliary body and the iris root," she continues. "In this case, the iris root is pushed more peripherally into the angle because of the anatomical variations versus the iris simply bulging into the angle."

Many general ophthalmologists aren't familiar with the diagnostic features associated with plateau iris. On gonioscopy, specific findings suggestive of plateau iris include the "double-hump sign" where one can see a ripple effect of the peripheral iris.

"If the anterior chamber depth is deep centrally and narrow in the periphery, there's a good possibility that the patient may have plateau iris configuration," says James C. Tsai, MD, MBA, the president of the New York Eye & Ear Infirmary of Mount Sinai. "The classic pupillary block type of angle closure suspect is a patient with a narrow central anterior chamber depth as well as narrow periphery. Observed very commonly in young patients with narrow angles, plateau iris configuration features an abnormal anterior position of the ciliary body. The entity is characterized by appo-



Sanjay Asrani, MD

**On gonioscopy, the iris bombe is the classic presentation of primary angle closure, where the iris billows forward and occludes the pupil.**

sitional angle closure with a flat iris configuration as compared to anterior bowing of the iris in the more typical angle closure glaucoma suspect patient. When the pupils are dilated, the angle gets crowded by focal bunching together of the peripheral iris, thereby causing an increase in intraocular pressure and an angle closure attack.”

Further confirmation can be obtained by ultrasound biomicroscopy, says Dr. Blieden. “Standard AS-OCT doesn’t penetrate beyond the iris; however, UBM can reveal crucial anatomical features that distinguish plateau iris from primary angle closure,” she says. “The definitive indicator of plateau iris on UBM is the anterior rotation of the ciliary body, accompanied by a notable loss of the ciliary sulcus space.”

Understanding patient risk factors will also help guide the diagnosis. “When I examine a patient with narrow angles, I think of the four major risk factors for angle closure besides family history: hyperopia; female sex; older age; and Asian ethnicity,” says Dr. Tsai.

Typically, patients with plateau iris syndrome present as narrow angles before age 40 and tend to be female.<sup>1</sup> One way to confirm this diagnosis is following a laser iridotomy, the common first-line treatment for narrow angles. “After they undergo laser iridotomy, they may experience high intraocular pressure after dilation, despite the iridotomy,” explains Sanjay Asrani, MD, professor of ophthalmol-

ogy at Duke University. “In contrast, those with narrow angles without plateau iris generally don’t have a pressure spike after dilation. It’s important to note that while some individuals over 40 may experience a pressure spike after dilation, they’re more likely to have a phacomorphic narrow angle, which is lens-induced.”

### Treatment vs. Observation

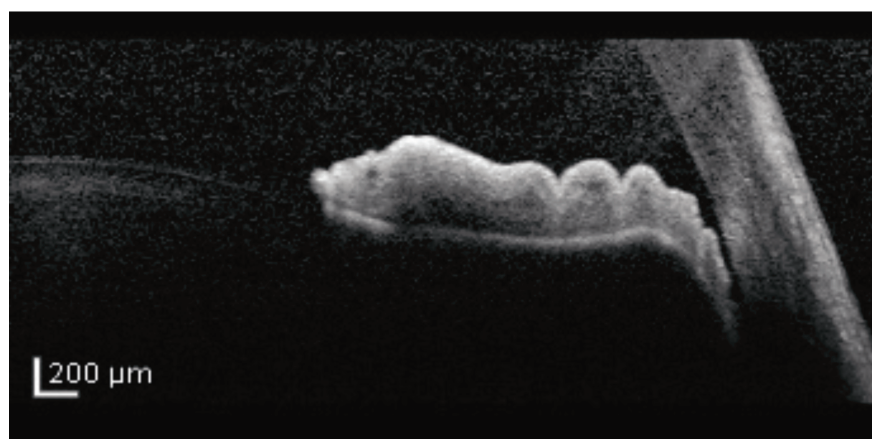
As mentioned earlier, peripheral iridotomy has been the standard therapy for narrow angles. However, there are differences of opinion on whether or not laser is always warranted.

First, Dr. Tsai says ophthalmologists must consider the true risk of the patient developing PAC or PACG. The ZAP study, a prospective, randomized clinical trial that compared LPI in one

eye vs. observation in the contralateral eye of 889 patients with PACS, showed a low risk of patients progressing to PAC or acute PACG.<sup>2</sup> Although the 14-year follow-up lost 390 LPI-treated eyes and 388 control eyes, PAC was found in two LPI-treated eyes and four control eyes.<sup>3</sup>

Using that same cohort of untreated eyes from ZAP, another study determined the baseline predictors of progression from PACS to PAC.<sup>4</sup> They cited “higher IOP, shallower central and limbal ACDs, and smaller TISA at 500 μm and light-room ARA at 750 μm may serve as baseline predictors for progression to PAC in PACS eyes.”

Dr. Tsai provided a published commentary<sup>5</sup> on this study, saying, “As a clinician evaluating a patient with bilateral, asymptomatic PACS (i.e., normal IOP, non-suspicious optic nerve examination findings [with OCT confirmation], no evidence of PAS on dynamic gonioscopy, and no history of an AAC episode), it’s comforting to know that the likelihood of that patient developing PAC or PACG is rather low based on the results of the large randomized clinical trials described here. In deciding whether to recommend prophylactic LPI or close observation in an asymptomatic patient with PACS, the ZAP trial results indicate that the clinician can make this clinical determination based on



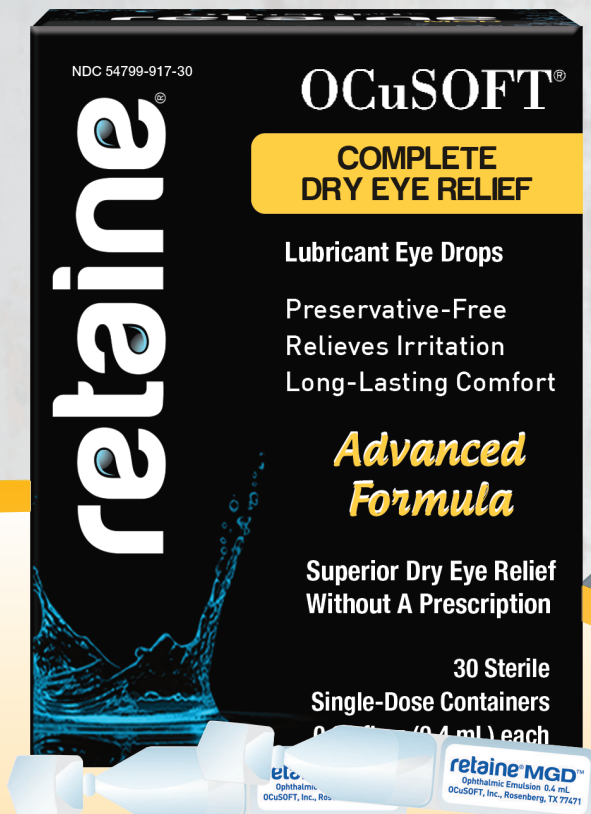Sanjay Asrani, MD

**The “double-hump sign” is suggestive of plateau iris, showing a ripple effect of the peripheral iris. Accurate identification of plateau iris configuration influences treatment planning, say glaucoma specialists.**



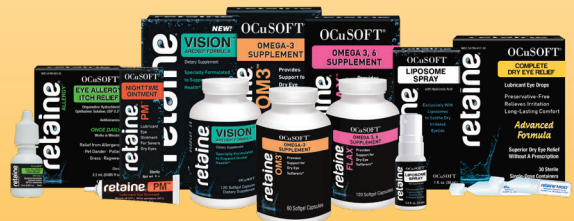# Restore Balance for MGD Patients

with Retaine® MGD® Ophthalmic Emulsion



Retaine® MGD® targets all three layers of the tear film for long-lasting comfort.

- ✓ Preservative-Free
- ✓ Developed for MGD Patients
- ✓ Lipid Active Ingredients
- ✓ Positively Charged Nano-droplets



For FREE samples or more information  
call (800) 233-5469 or visit [www.ocusoft.com](http://www.ocusoft.com)

Part of a complete line of Retaine® Brand Products

IOP, central ACD and limbal ACD without the need for more sophisticated AS-OCT measurements. In addition to the comprehensive ocular examination (including dynamic gonioscopy), patient factors such as age, sex, race, ethnicity and refractive status should be considered, since risk factors for the development of PACG include older age, Asian race, female sex, hyperopia and positive family history.”

Dr. Tsai says that if a patient has multiple risk factors but is asymptomatic, he will often consider performing the 15-minute dark room prone provocative test to obtain additional IOP information on these patients.

“In the dark room prone provocative test, the clinician records the patient’s IOP and then turns down the lights in the room,” he says. “The patient places their head down, and in the dark, their pupils should dilate. The clinician returns and measures their eye pressures after 15 minutes. This method is presumably positive (i.e., predilection for future angle closure attack) if the IOP is increased by at least 8 mmHG. If the IOP goes up by even 4 or 5 mmHg, that’s enough for me to be worried and strongly consider recommending laser iridotomy.”

Glaucoma experts say it’s important to discuss the success rates of LPI, as well as the side effects. It’s not uncommon for the patients to Google the procedure and find worst-case scenarios online, and ophthalmologists should be prepared to temper those misconceptions.

“Patients frequently express concerns about potential side effects following an iridotomy, particularly regarding dysphotopsias,” Dr. Blieden says. “While these visual disturbances can occur, they’re not as common as some might believe, and for the majority of patients, they’re not debilitating. However, significant findings from the EAGLE trial revealed instances of complications such as macular edema, persistent inflammation and uncontrolled IOP post-LPI. These complications sometimes necessitated further surgical interventions.”

If the angle remains closed post-PI, the next step has traditionally been iridoplasty. However, this approach is less frequently employed today, and clear lens extraction is becoming the preferred technique to eliminate the narrow angle issue altogether.

“If one is diagnosed with narrow angles, he/she may have plateau iris configuration, and a laser iridotomy won’t remedy and/or cure this condition,” says Dr. Tsai. “So in my opinion, you’re subjecting a person with normal vision, a normal optic nerve on OCT analysis, normal visual field, and no previous symptoms of angle-closure attack to an invasive laser procedure. What are the well-known risks of laser iridotomy? Well, these risks include bleeding, inflammation, ghost images, a keyhole effect and precipitation or worsening of a cataract.”

“The landscape of treatment has changed since EAGLE and ZAP, particularly with the realization that early cataract extraction can effectively open the angle in the majority of these patients,” Dr. Blieden says. “Thus, performing lens extraction has become a more favorable solution. In fact, it’s exceedingly rare for a plateau iris patient to not experience sufficient angle opening following cataract surgery. Some surgeons will combine lens extraction with endocyclophotocoagulation to help rotate the ciliary body down and away from the angle.

“In comparing groups from the EAGLE trial, it was evident that those undergoing laser iridotomy faced a statistically significant rate of subsequent glaucoma-related surgeries and interventions compared to the clear lens extraction group,” she continues.

### Can smartphones prevent an angle closure attack?

Since the advent of the smartphone, the field of ophthalmology has found ways to take advantage of its multifunctionality, whether it’s with telehealth, imaging or accessing EMR. One feature that James C. Tsai, MD, MBA, the president of the New York Eye & Ear Infirmary of Mount Sinai, has found useful is its bright flashlight, and the potential it has to prevent an angle closure attack.

“Years ago, if a patient noted that an angle closure attack was happening (e.g., at the movies), they had little recourse since the lights in the movie lobby (or available flashlights) wouldn’t likely be bright enough to constrict their pupil to reverse their pupillary dilation and an angle closure attack,” he says. “But smartphone flashlights are even brighter than the pen lights ophthalmologists use.”

For patients who’ve never had signs or symptoms of an angle closure attack—eye pain, headache, blurred vision, red eyes, nausea, vomiting—and their eye pressures and visual fields are normal and their optic nerve looks healthy on OCT, a laser iridotomy procedure could eliminate their risk of relative pupillary block, but comes with considerable side effects and complications.

“If they’re asymptomatic, I can offer a more conservative approach,” Dr. Tsai continues. “If they take this latter approach, patients must promise that they’ll keep their smartphones with them at all times. If they feel any symptoms of angle closure attack, they’re instructed to shine the smartphone flashlight in their eyes. Since pupillary constriction is a bilateral response, the patient doesn’t even have to identify the eye that has the potential angle closure attack. If they shine the light in one eye, both pupils automatically constrict.”

Dr. Tsai feels this is a better alternative than the previously recommended pilocarpine for those who had an increased risk of angle closure attack. “The problem with pilocarpine is the increased risk of retinal detachment as well as additional side effects such as brow ache,” he says. “Thus, the smartphone flashlight appears to be a readily available option for aborting an angle closure attack in patients with a diagnosis of primary angle closure suspect.”

However, if a patient does feel an attack coming on, which is then reversed by the flashlight, Dr. Tsai says conservative management would no longer be appropriate. “In these patients, I recommend prompt laser iridotomy.”

Not everyone agrees that a laser iridotomy should be skipped, though.

“I generally don’t recommend clear lens extraction without prior laser treatment,” says Dr. Asrani. “This approach is unusual and could pose unnecessary risks. Laser iridotomy is essential to eliminate the possibility of pupillary block, and that may be all the patient needs. The success rate is very high for a laser iridotomy for narrow angles, and I feel that one shouldn’t bypass this part of the treatment process. Furthermore, one shouldn’t perform a clear lens extraction on a patient with normal IOP and an undamaged optic nerve. If a patient shows significant glaucoma damage to the optic nerve and is on maximum tolerated medical therapy but continues to progress, clear lens extraction can be considered, preferably after laser iridotomy has been performed.”

Close observational management can be a reasonable alternative, says Dr. Tsai. “I’m not saying it should be the only option. I believe it’s a reasonable alternative if patients desire a more

conservative approach to avoid post-LPI adverse effects. However, if you as an ophthalmologist are concerned, you can always recommend the laser iridotomy procedure,” he says. “But please be on the lookout for patients with plateau iris syndrome since the laser isn’t going to solve the problem in these cases. Ophthalmologists should understand that if they perform successful laser iridotomy on a patient with plateau iris configuration, this patient will still be at risk of an angle closure attack with pupillary dilation.”

Patients who may not be candidates for conservative management could include diabetics who require an annual dilated retinal exam. “I wouldn’t recommend following this patient conservatively,” Dr. Tsai says. “I’d want to eliminate the pupillary block component of their narrow angles, and therefore I’d recommend performing LPI to minimize as much as possible the risk of angle closure attack (since the patient needs to have repeated dilated pupillary exams). In my opinion, the more times a patient with PACS

gets dilated, the more likely they are to have an angle closure attack.

“Furthermore, alerting these patients to the utility of their smartphone flashlight and providing the potential benefits of immediate and bilateral pupillary constriction in aborting a suspected acute angle closure attack appears warranted,” he continues (*see sidebar*).


Navigating conversations with patients about their treatment options really depends on the practitioner. “For patients who wear bifocals and exhibit signs of PAS or symptoms of angle closure, I recommend lens extraction,” Dr. Blieden says. “For younger patients who aren’t already reliant on bifocals, the discussion becomes more nuanced; they may be apprehensive about losing their ability to accommodate.”

For ophthalmologists who do choose to perform a clear lens extraction, Dr. Blieden says it’s essential for them to recognize that narrow angle cataracts behave somewhat differently from typical cataracts. “Be prepared for the possibility of shallow anterior

## ADVERTISER INDEX

*This index is published as a convenience and not as part of the advertising contract. Every care will be taken to index correctly. No allowance will be made for errors due to spelling, incorrect page number, or failure to insert.*

<b>Alcon</b> ..... 15, 16 ..... (800) 451-3937 ..... <a href="http://www.alcon.com">www.alcon.com</a>	<b>Epion Therapeutics</b> ..... 51 ..... <a href="https://www.epiontx.com/">https://www.epiontx.com/</a>	<b>Reichert Technologies</b> ..... 45 ..... (888) 849-8955 ..... <a href="http://www.reichert.com">www.reichert.com</a>
<b>Alcon</b> ..... 53 ..... (800) 451-3937 ..... <a href="http://www.alcon.com">www.alcon.com</a>	<b>Glaukos</b> ..... Cover 4 ..... (800) 452-8567 ..... <a href="http://www.glaukos.com">www.glaukos.com</a>	<b>Scope Health Inc.</b> ..... 8 ..... <a href="http://scopehealthservices.com">scopehealthservices.com</a> ..... <a href="mailto:hello@optase.com">hello@optase.com</a>
<b>Apellis</b> ..... 25, 26 ..... <a href="http://www.apellis.com">www.apellis.com</a>	<b>Johnson &amp; Johnson Surgical Vision, Inc.</b> ..... 5 ..... <a href="http://surgical.jnjvision.com">http://surgical.jnjvision.com</a>	<b>Tarsus</b> ..... 11, 12 ..... <a href="https://tarsusrx.com">https://tarsusrx.com</a>
<b>Bausch + Lomb</b> ..... Cover Tip ..... (800) 323-0000 ..... <a href="https://www.bausch.com/">https://www.bausch.com/</a>	<b>Nanodropper</b> ..... 59 ..... <a href="http://www.nanodropper.com/ReviewOpt">www.nanodropper.com/ReviewOpt</a>	<b>Thea Pharma</b> ..... Cover 3 ..... <a href="http://www.ivizia.com/ecp">www.ivizia.com/ecp</a>
<b>Boston Sight</b> ..... 13 ..... <a href="https://www.bostonsight.org/">https://www.bostonsight.org/</a>	<b>Ocusoft</b> ..... 41 ..... <a href="https://www.ocusoft.com/">https://www.ocusoft.com/</a>	<b>Topcon</b> ..... Cover 2 ..... <a href="http://www.topconhealthcare.com">www.topconhealthcare.com</a>
	<b>Oyster Point</b> ..... 48, 49 ..... <a href="https://oysterpointrx.com/">https://oysterpointrx.com/</a>	<b>Vital Tears</b> ..... 55 ..... <a href="https://vitaltears.org/">https://vitaltears.org/</a>



Sanjay Asrani, MD

**Plateau iris presents with an abnormal anterior position of the ciliary body with the iris root pushed more peripherally into the angle.**

chambers and understanding how the iris may respond intraoperatively, and the potential of a higher risk for aqueous misdirection during the perioperative period is crucial,” she says. “Additionally, awareness of the risk for myopic surprises due to the effective lens position of the IOL is vital during patient consultations.”

Overall, she says the findings from ZAP have helped calm her when approaching treatment for patients with narrow angles. “I no longer feel the need to panic upon identifying a narrow angle,” says Dr. Blieden. “We used to think they were a ticking time bomb for an angle closure. In reality, it just doesn’t happen that often, or that quickly. Instead, I believe in adopting a more cautious and measured approach, emphasizing patient education about their risk factors and treatment options. Keep an open dialogue and assess the patient’s anxiety level. Ultimately, it’s their decision, and it’s my job just to counsel them based on the evidence I have.”

### Long-term Management and Ongoing Research

Dr. Asrani says there’s a misconception among patients that an LPI protects them for life.

“After laser iridotomy, it’s crucial to inform patients that although their pressures are initially normal, there

remains a risk of developing chronic angle closure as they age,” he says. “The lens continues to grow and may lead to increased pressure over time. Therefore, patients should be advised to schedule annual follow-ups with their ophthalmologist or optometrist to monitor their optic nerve health and intraocular pressure. It’s important to convey that having had laser treatment doesn’t protect them from developing other forms of glaucoma, such as low-tension glaucoma.”

Dr. Blieden says she follows her clear-lens extraction patients similarly to POAG patients. “Historically, I’d schedule follow-up visits every six months; however, I’ve recently transitioned to annual visits,” she says. “I can’t completely let them go because we don’t know what those angles are going to do in 15 or 20 years. These patients are often younger—typically in their 50s—so as they age, particularly when they reach their 70s, we may not yet fully understand the long-term implications of their narrow angle diagnoses. The potential for increased risk factors over time is something we need to monitor, which is why annual check-ups seem reasonable until more data becomes available.”

Ophthalmologists should also keep tabs on their patients’ medications and which ones can cause dilated pupils.

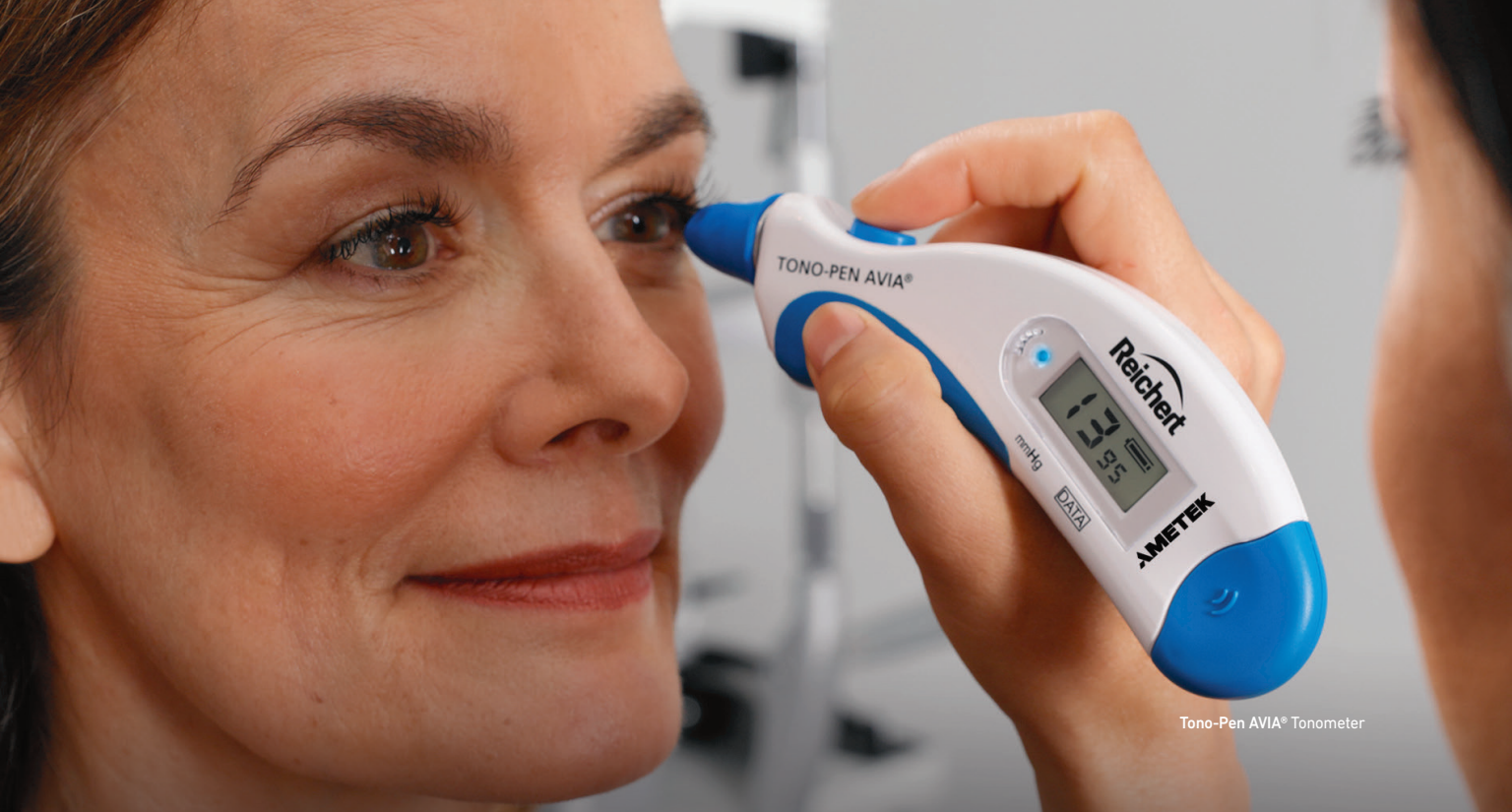“Many subspecialties of medicine, including urology, psychiatry and ENT are realizing that their commonly prescribed drugs have anticholinergic properties,” says Dr. Asrani. “Just one extra medication, such as an antidepressant or decongestant, is sometimes all a patient needs to push them into a narrow angle attack.”

Dr. Tsai adds that Botox shots (botulinum injections) and over-the-counter cold medications that contain phenylephrine can cause pupil dilation, and scopolamine patches (for motion sickness) can cause long-term pupillary dilation (three days to two weeks). “Therefore, I stress to my patients that if they want to take a conservative approach with their narrow angles, they should avoid these medications,” he says.

The glaucoma specialists we spoke with are closely monitoring the research taking place regarding diagnosis and treatment for narrow angles. Dr. Asrani says he’s particularly interested in studies on imaging techniques that will help reduce the reliance on expert interpretation of gonioscopy.

“It’s a skill that many providers aren’t well-versed in,” he says. “Literature suggests that over half of newly diagnosed glaucoma patients don’t receive a gonioscopy, which could result in undetected narrow angles. Ongoing research is focusing on anterior segment optical coherence tomography and algorithms to improve diagnostic accuracy without the need for gonioscopy.” ◀

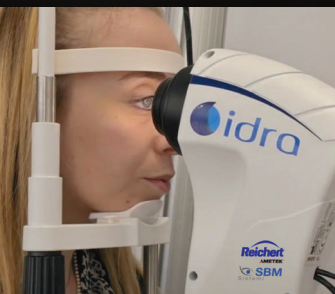1. Jain N, Zia R. The prevalence and breakdown of narrow anterior chamber angle pathology presenting to a general ophthalmology clinic. *Medicine (Baltimore)* 2021;18:100:24:e26195.
2. He M, Jiang Y, Huang S, et al. Laser peripheral iridotomy for the prevention of angle closure: A single-centre, randomized controlled trial. *Lancet* 2019;393:10181:1609-1618.
3. Yuan Y, Wang W, Xiong R, Zhang J, Li C, Yang S, Friedman DS, Foster PJ, He M. Fourteen-Year outcome of angle-closure prevention with laser iridotomy in the Zhongshan Angle-Closure Prevention Study: Extended follow-up of a randomized controlled trial. *Ophthalmology* 2023;130:8:786-794.
4. Yuan Y, Xiong R, Wang W, et al. Long-term risk and prediction of progression in primary angle closure suspect. *JAMA Ophthalmol* 2024;142:3:216-223.
5. Tsai JC. Longitudinal management of primary angle closure suspect. *JAMA Ophthalmol* 2024;142:3:224-225.



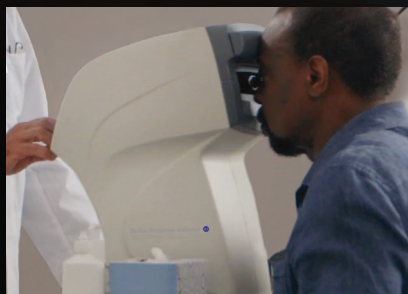Tono-Pen AVIA® Tonometer

# BETTER MEASUREMENTS ENABLE BETTER OUTCOMES

Deliver exceptional patient care with Reichert's full range of diagnostics for glaucoma, refraction, and dry eye – Including **Tono-Pen®**, Corneal Hysteresis, and the all-new **Tono-Vera®**.



Dry Eye Assessment and Therapy



Ocular Response Analyzer® G3  
with Corneal Hysteresis + IOPcc



All-New! Tono-Vera® Tonometer with  
ActiView™ Positioning System



Phoropter® – Digital or Traditional  
featuring Phoropter® VRx with ClearChart®



LEARN MORE: REICHERT.COM



*passionate about eye care*

# MANAGING CROSS-LINKING COMPLICATIONS

Although rare, patients may experience issues following treatment for keratoconus and other corneal conditions.

ANDREW BEERS  
ASSOCIATE EDITOR

Whether a patient has keratoconus, ectasia following refractive surgery, or pellucid marginal degeneration, corneal collagen cross-linking can be used to prevent progression. This treatment is a particularly safe and effective procedure, and rarely do complications arise. However, complications can occur, and some patients may experience negative effects, vision-threatening symptoms as well as continuous progression. Here, experts share their knowledge on what complications may arise following CXL and how to manage patients.

## Complications and Their Management

There are several complications that can present postoperatively. Some are far more common and don't pose as much of a threat compared to others. In most cases, these problems can easily be treated with topical drugs and contact lenses, but severe cases may need to be retreated with CXL

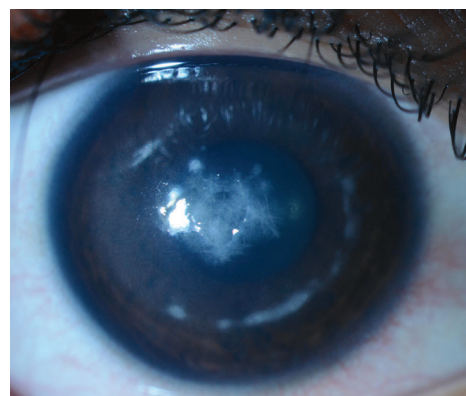
or could lead to a corneal transplant. "Most of the side effects—complications of cross-linking—are really related to epithelial removal," says Peter Hersh, MD, of Teaneck, New Jersey, and the U.S. medical monitor of the original CXL FDA trial by Avedro, which was acquired by Glaukos in 2019.

• **Ocular pain.** Common amongst invasive surgeries, patients do experience pain and discomfort following CXL due to the epithelial debridement. The epithelium-off CXL technique is the only technique approved by the United States Food and Drug Administration. Although pain isn't touted as a complication, it's best to ensure that patients are satisfied through this process and given proper care for any irritation that may arise.

"There's expected pain, which I wouldn't call a complication, and it could worsen, which I wouldn't call a complication either," suggests Brad Feldman, MD, a cornea and refractive surgeon at Philadelphia Eye Associates in Pennsylvania. "Most patients

have pretty well-tolerated pain that they're able to sleep off in the first several hours after the procedure, and by the next morning, they're no longer in pain. They just have some mild discomfort, tearing or foreign body sensation, but there are some patients who have more intense or prolonged pain, as well as folks who have no initial pain and develop it at day two or three. That's pretty uncommon, but it can happen.

"So, for people who have very sensitive eyes, it's just a matter of



Zeba Syed, MD

**An eye presenting with infectious keratitis four weeks after cross-linking. If infection persists to severe stages, then a corneal transplant may have to be employed.**

This article has no commercial sponsorship.

Dr. Hersh is the U.S. medical director for Glaukos and a consultant for Corneagen. Dr. Greenstein consults for Glaukos. Dr. Syed is a consultant for Glaukos. Drs. Feldman, Kang and Thulasi have no related financial disclosures.

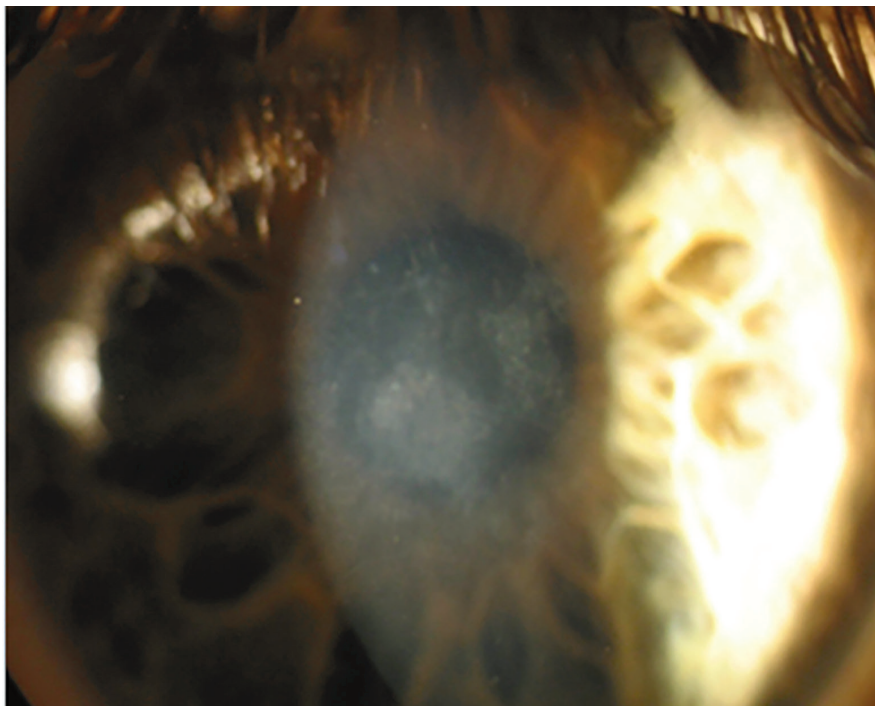
giving them NSAIDs topically, maybe getting them a pain medication beyond just ibuprofen or acetaminophen,” he continues. “It’s pretty rare that I would prescribe a narcotic, but maybe I’ll prescribe one once every couple of years. Then, there’s the people who are doing fine and they start having pain a few days later, and the most common cause of that would be the contact lens falling out and not being noticed by the patient, or tight lens syndrome, where they start to swell up and get a keratitis from that. In that case, we just swap the lens out for a looser one.”

- **Delayed epithelial healing.**

Similar to ocular pain in the sense that it’s one of the earliest complaints a patient has following CXL, delayed reepithelization, if not treated properly, can lead to more severe complications, but these cases are rare.

“Delayed epithelial healing can occur due to many reasons, such as age, steep corneas, poor hygiene, poor compliance with medication, pre-existing ocular surface disease and more,” explains Joann Kang, MD, a cornea and refractive surgeon at the Montefiore Medical Center in New York. “Delayed epithelial healing then in turn puts a patient at risk for other complications.” This is one of the more frequent complications that arises following CXL, with rates varying between 4 and 26 percent, depending on the literature.<sup>1</sup> She notes that, if the wound from removing the epithelium doesn’t heal correctly, then it can result in permanent visual sequelae.

“In the early stages after cross-linking, the most common thing to see would be a delayed wound healing,” adds Steven Greenstein, MD, who practices with Dr. Hersh. “So generally, we see that the epithelium heals somewhere between three to four days. It heals mostly because a high volume of patients are pretty young. We generally will take out a bandage contact lens at



**A slit-lamp photograph of a patient’s left eye with deep corneal haze. Although not seen as a complication, haze can progress late after cross-linking and cause further issues to arise.** (Creative Commons License: <https://creativecommons.org/licenses/by-nc/4.0/>.)

about five days for these patients, and rarely you’ll see a slower wound healing where they still have an epithelial defect. Even with those, I would say most tend to heal with minimal additional intervention, but sometimes they do need things like serum tears or even amniotic membrane to help them heal. It’s extremely rare to see infection with it. I can count on one hand the number of cases we’ve seen over the course of a decade that we’ve done cross-linking.”

- **Corneal haze.** “One of the things that we most noticed as a general event after cross-linking is a cross-linking associated corneal haze,” says Dr. Hersh. Corneal haze is an effect that occurs in most patients but isn’t always described as a complication.

“Most patients who undergo cross-linking initially develop a generalized haze in the anterior corneal stroma soon after the procedure, and then this tends to evolve into what we call a demarcation line,” Dr. Hersh explains. “If you look carefully under the slit lamp or with OCT, you can

see a little bit of haziness down to the area of cross-linking, and this demarcation line delineates really the area of cross-linked tissue from the area of non-cross-linked tissue posteriorly. Typically, with a standard procedure, this is about 250 or 300 microns deep.

“Now, what we find with the cross-linking associated haze is that it peaks in a month, it plateaus at three months, and then it returns to baseline,” he continues. “Typically, it goes back to baseline by the first year. It’s very important that the ophthalmologist recognizes this, and we always will advise the patient that this haze will generally subside over time.”

Both Drs. Hersh and Greenstein were a part of clinical trials for corneal cross-linking, and they published a study in the early days of the procedure which reported that 90 percent of eyes that were cross-linked experienced stromal haze.<sup>2</sup> If there are so many patients presenting with this, then why should it be seen as a complication?

**tyrvaya**<sup>®</sup>  
(varenicline solution)  
nasal spray 0.03 mg

**FOR THE SIGNS  
& SYMPTOMS OF  
DRY EYE DISEASE**

IT'S NOT ANOTHER DROP

# ACTIVATE REAL TEARS

WITH TYRVAYA<sup>®1</sup>



**IT'S THE OCULAR SURFACE-SPARING  
NASAL SPRAY FOR DRY EYE<sup>1</sup>**

Tyrvaya is believed to work by activating the trigeminal parasympathetic pathway via the nose to help increase the production of patients' own basal tears. The exact mechanism of action is unknown.<sup>1</sup>

## Indication

Tyrvaya<sup>®</sup> (varenicline solution) nasal spray is indicated for the treatment of the signs and symptoms of dry eye disease.

## Important Safety Information

The most common adverse reaction reported in 82% of patients was sneezing. Events that were reported in 5-16% of patients were cough, throat irritation, and instillation-site (nose) irritation.

**Please see Brief Summary of Prescribing Information on the next page and the full Prescribing Information at [Tyrvaya-pro.com](http://Tyrvaya-pro.com).**

**Reference: 1.** Tyrvaya. Prescribing Information. Oyster Point Pharma.

**SEE WHAT  
TYRVAYA  
CAN DO**







**BRIEF SUMMARY:** Consult the full Prescribing Information for complete product information available at [www.tyrvaya-pro.com](http://www.tyrvaya-pro.com).

### **INDICATIONS AND USAGE**

TYRVAYA® (varenicline solution) nasal spray is a cholinergic agonist indicated for the treatment of the signs and symptoms of dry eye disease.

### **ADVERSE REACTIONS**

**Clinical Trials Experience:** Because clinical trials are conducted under widely varying conditions, adverse reaction rates observed in the clinical trials of a drug cannot be directly compared to rates in the clinical trials of another drug and may not reflect the rates observed in practice.

In three clinical trials of dry eye disease conducted with varenicline solution nasal spray, 349 patients received at least 1 dose of TYRVAYA. The majority of patients had 31 days of treatment exposure, with a maximum exposure of 105 days.

The most common adverse reactions reported in 82% of TYRVAYA treated patients was sneezing. Other common adverse reactions that were reported in >5% of patients include cough (16%), throat irritation (13%), and instillation-site (nose) irritation (8%).

### **USE IN SPECIFIC POPULATIONS**

**Pregnancy: Risk Summary:** There are no available data on TYRVAYA use in pregnant women to inform any drug associated risks. In animal reproduction studies, varenicline did not produce malformations at clinically relevant doses.

All pregnancies have a risk of birth defect, loss, or other adverse outcomes. In the US general population, the estimated background risk of

major birth defects and miscarriage in clinically recognized pregnancies is 2% to 4% and 15% to 20%, respectively.

**Data: Animal Data:** Pregnant rats and rabbits received varenicline succinate during organogenesis at oral doses up to 15 and 30 mg/kg/day, respectively. While no fetal structural abnormalities occurred in either species, maternal toxicity, characterized by reduced body weight gain, and reduced fetal weights occurred in rabbits at the highest dose (4864 times the MRHD on a mg/m<sup>2</sup> basis).

In a pre- and postnatal development study, pregnant rats received up to 15 mg/kg/day of oral varenicline succinate from organogenesis through lactation. Maternal toxicity, characterized by a decrease in body weight gain, was observed at 15 mg/kg/day (1216 times the MRHD on a mg/m<sup>2</sup> basis). Decreased fertility and increased auditory startle response occurred in offspring at the highest maternal dose of 15 mg/kg/day.

**Lactation: Risk summary:** There are no data on the presence of varenicline in human milk, the effects on the breastfed infant, or the effects on milk production. In animal studies varenicline was present in milk of lactating rats. However, due to species-specific differences in lactation physiology, animal data may not reliably predict drug levels in human milk.

The lack of clinical data during lactation precludes a clear determination of the risk of TYRVAYA to an infant during lactation; however, the developmental and health benefits of breastfeeding should be considered along with the mother's clinical need for TYRVAYA and any potential adverse effects on the breastfed child from TYRVAYA.

**Pediatric Use:** Safety and efficacy of TYRVAYA in pediatric patients have not been established.

**Geriatric Use:** No overall differences in safety or effectiveness have been observed between elderly and younger adult patients.

Manufactured for Oyster Point Pharma, Inc., a Viatrix company, 202 Carnegie Center, Suite 106, Princeton NJ 08540. For more information, visit [www.tyrvaya-pro.com](http://www.tyrvaya-pro.com). To report an adverse event, contact 1-877-EYE-0123.

© 2024 Viatrix Inc. and/or its affiliates. All rights reserved. Viatrix and the Viatrix logo are trademarks of Mylan Inc., a Viatrix Company. TYRVAYA and the TYRVAYA logo are registered trademarks of Oyster Point Pharma, Inc., a Viatrix Company. USA-TYR-2024-00040 5/24



“It’s always been a big debate whether haze is even a complication at all,” explains Dr. Greenstein. “It’s important when you talk about haze in cross-linking to really distinguish the type of haze that you expect to see. We did a lot of early work and published papers in terms of the natural course of haze, which tends to increase to its peak and then generally returns to baseline somewhere between six months and a year. That we don’t really consider it a complication. In fact, in some ways, we view that as the cross-linking taking effect and working.”

“On the other hand, a longer-term haze, which kind of leads to more corneal stromal scarring, is certainly a rare complication that you can see with cross-linking in the later phases somewhere between three months and a year down the road,” he adds. The standard postop regimen for CXL at Drs. Greenstein and Hersh’s clinic includes a combination of antibiotics and steroid drops, which are tapered over three weeks. But, in cases of long-term haze, Dr. Greenstein notes that they extend the steroid taper and try to limit any inflammatory response that may be seen.

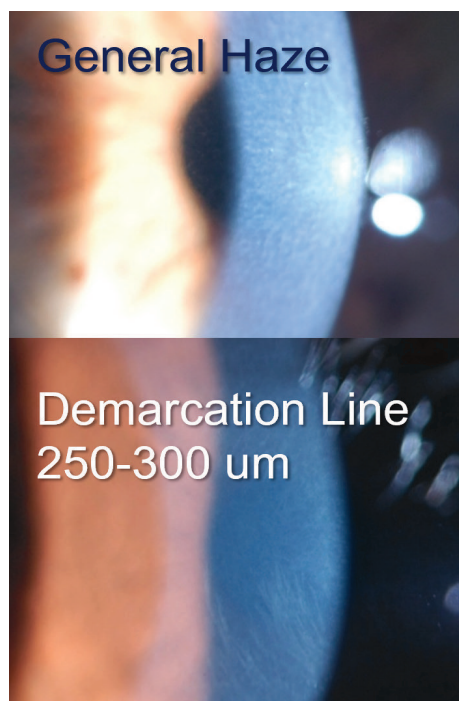“More recently, we’ve tried topical losartan, which we’ve compounded,” Dr. Greenstein adds. “There’s been some early studies that have shown that that might be effective in corneal scarring. We haven’t seen it work that well post-cross-linking, but we have tried that as an option.”

• **Corneal scarring.** This complication is tricky. Some patients may present with scarring before the CXL procedure, and some may develop scarring afterwards. In one study, the incidence of scarring was reported to be 2.9 percent.<sup>3</sup> As explained earlier, scarring can occur due to long-term haze in patients, and losartan can be employed to treat this, although it’s used off-label.<sup>5</sup>

What ophthalmologists need to be aware of is that pre-

“**The most critical thing with cross-linking is to really drill into patients that this is a stabilizing procedure.**  
—Steven Greenstein, MD

existing corneal scarring is seen as a contraindication for CXL and can increase the risk of further complications following the procedure. “Assess the thickness of any pre-existing scarring because this may lead to a greater incidence of haze or scarring after the procedure,” notes Dr. Hersh. “Patients who have central scarring might require a corneal transplant, and patients who have more peripheral scarring, where the risk of haze might be somewhat increased, [should be seen as a contraindication].”



The demarcation line separates the area of cross-linked tissue from the area of non-cross-linked tissue posteriorly in a case where haze is present.

“We know that if we treat people who have scars in the cornea, they’re more likely to develop haze, and I typically won’t treat those patients with cross-linking,” adds Dr. Feldman. “Instead, depending on the size of the scar, we either offer scleral or specialty contact lenses alone, or if it’s a dense scar that the patient can’t see well out of, then we can do a corneal transplant.”

• **Infectious keratitis.** Infections can be caused by a whole host of reasons and should be avoided if possible. Cases of infection are rare, but they’re seen as one of the most dreaded complications to arise following CXL, according to Praneetha Thulasi, MD, an assistant professor of Ophthalmology and Visual Sciences at Washington University School of Medicine in St. Louis, and a cornea specialist at the Washington University Eye Center. In a large population study, researchers found that infection occurs in 0.12 percent of cases.<sup>6</sup>

“[At our practice], we treat patients with steroids postoperatively,” says Dr. Thulasi. “With cross-linking and steroids, patients do have sort of an immunosuppressed state. So, infectious keratitis is the thing that we worry the most about. It’s fairly rare. It’s usually related to some sort of patient compliance issue, but I’ve done this for nine years now, and I’ve seen this in three cases. Only one patient had a really severe infection to the point where we needed to do a corneal transplant.”

“[Infectious keratitis] could be from possible contamination during the surgery,” she continues. “These aren’t technically sterile procedures. They’re what we call ‘clean procedures.’ So, surgeons aren’t doing them in the operating room. It could be from the fact that we put a contact lens on the patient for postoperative pain management. It could be from patients not using antibiotics after treatment. Also, the few patients I’ve had were all young



## Clinical Study

# Keratoconus Treatment

## EpiSmart™ Epi-On Corneal Cross-linking



*"I think EpiSmart will be the next major advance in the treatment of keratoconus."*

**- Michael W. Belin, MD,**  
Chief Medical Officer of Epion

*Expert in Corneal Disease Diagnosis and Treatment*

## Eligibility Requirements\*

- ✓ 8 to 45 years of age
- ✓ Diagnosed with keratoconus in one eye or both eyes
- ✓ Have had no previous eye surgeries

## Enrollment Deadline Ends Soon!

Scan visit the url below to Refer Patients Today

[epiontx.com/referral](https://epiontx.com/referral)



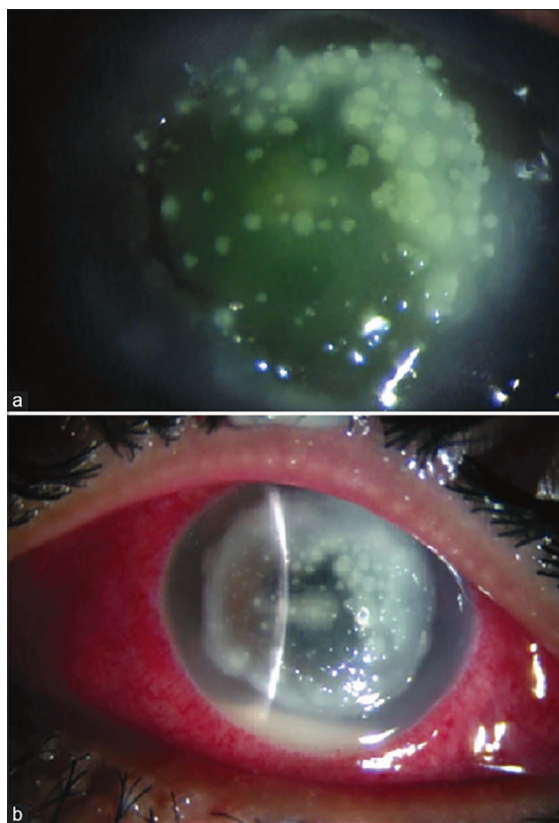
*\*This is not a complete list of study requirements.*

folks who had trouble putting drops in. It could've stemmed from that. I don't think we have a definitive answer as to what causes these infections, but those are all the things we look at any time we have a complication."

Zeba Syed, MD, a cornea and refractive surgeon at Wills Eye Hospital in Philadelphia, makes a procedural plan with her team prior to CXL to avoid infection and treat it if it occurs after the procedure. "I always use povidone-iodine to cleanse the eyelids prior to cross-linking and minimize the risk of eyelid flora resulting in infectious keratitis," she says. "My team members involved in the procedure always wear masks while cross-linking to reduce the chances of oral flora contaminating the surgical field. An antibiotic drop is placed at the conclusion of the procedure, and patients are advised to start antibiotic treatment immediately afterwards.

"These infections are cultured, and the patients are started on fortified antibiotics, and culture results will guide more targeted therapy," she continues. "I'll typically discontinue any corticosteroid drops until culture results return or the clinical picture starts improving."

What both Drs. Thulasi and Syed are alluding to are bacterial infections that may occur after the procedure, but there are other causes. Fungal infections are also a rare possibility that may occur following CXL. "Typically, our first-line drug would be a fourth-generation fluoroquinolone [to treat infection], but I think it's also particularly important to look for unusual organisms in some of these patients," suggests Dr. Hersh. "We've found in our practice a couple of fungal infections after cross-linking.



**Corneal melt presenting in a 15-year-old patient post-CXL. (A) Patient's eye with diffuse infiltrates three days postop. (B) Patient's eye with corneal melt six days postop. They were treated with penetrating keratoplasty.** (Creative Commons License: <https://creativecommons.org/licenses/by-nc/4.0/>.)

So, one needs to be wary of that kind of infection as well. You certainly should recommend first, a genetic culture and sensitivity, including a fungal culture and, secondly, if there isn't a good response to antibiotics, perhaps re-culture and consider a fungal infection.

"Fungal keratitis has been the most severe complication that we saw [in clinical trials], but is that directly affected by the cross-linking? If the epithelium isn't completely smooth and healed, those patients are more prone to infection. Certainly, if they're also on prolonged steroid treatment, they're more susceptible to infection, particularly the possibility of fungal infection. Again, fungal infection is very rare, but it's one of the more unusual things that we have seen."

Agarwal R, et al.

Additionally, it should be noted that herpes simplex keratitis can cause infection and should be noted as a contraindication for CXL. "Anybody with a history of viral keratitis, particularly herpetic keratitis, we know any procedure can trigger recurrence of that virus again, and they'll have delayed healing as well," adds Dr. Thulasi.

- **Corneal melt.** In some cases of infection, the patient may progress to having a corneal melt. "In severe infections, if the patient isn't improving or they progress to having a corneal perforation or melt, we may need to do a corneal transplant, but severe infections are generally pretty rare," says Dr. Thulasi.

Corneal melt can be induced by NSAIDs prescribed to patients for a presenting epithelial defect.<sup>4</sup> This treatment, along with others, can produce changes in the cornea which increase the risk of melt and perforation. There are ways to reduce the epithelial defect and mitigate the risk of corneal melt.

"In these cases, I'll typically place amniotic membrane in the clinic to help reduce inflammation and promote epithelialization," says Dr. Syed.

- **Disease progression.** Sometimes conditions such as keratoconus progress following surgery. The experts in this article tend to see a younger patient population for CXL, therefore these patients' corneas are still progressing naturally as they get older. While CXL is meant to prevent further progression of corneal diseases, the condition can relapse due to patients' changing corneas.

"In cases of disease progression, repeat cross-linking is usually indicated," says Dr. Syed. "I counsel

**Systane**<sup>®</sup>

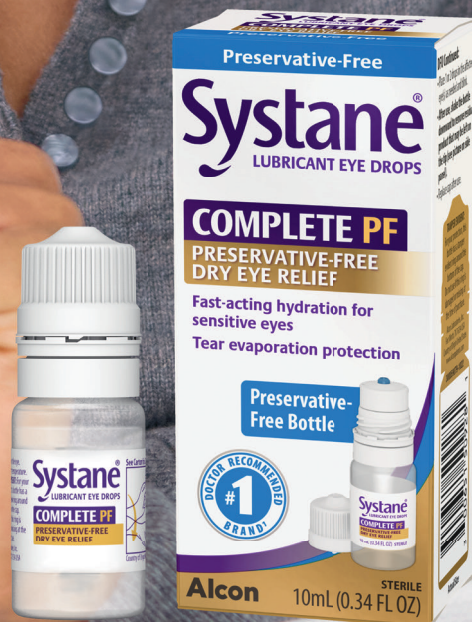**1 drop.**

**8 hours**

**dry eye relief.**

**Alcon**

© 2023 Alcon Inc. US-SYX-2300072



patients who've been cross-linked that even though they're now at a decreased risk of progression, they should still avoid rubbing their eyes because progression is possible. Increased rates of progression after cross-linking typically occur in younger age groups."

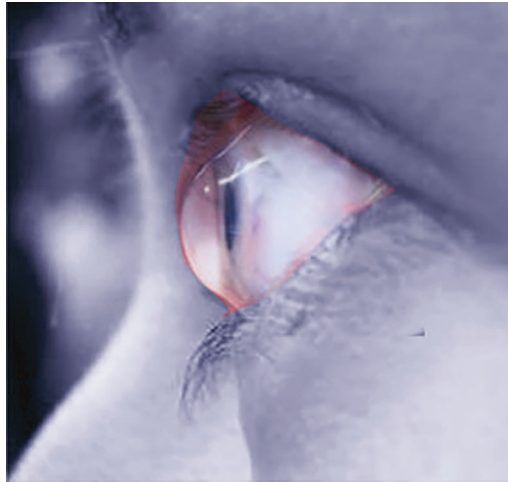
The incidence of disease progression for keratoconus is staggeringly lower than the rates of progression for other diseases. For keratoconus, CXL is quite successful, with only a 7.6 percent failure rate according to one study.<sup>7</sup> In another study looking at the disease progression three years after treatment for both keratoconus and post-LASIK ectasia patients, keratoconus progressed in 5 percent of subjects, while ectasia progressed in 25 percent of subjects.<sup>8</sup>

If the patient begins to complain about their disease progression and how it's affecting their vision, then moving forward with another treatment option could satisfy them. "Contact lenses, particularly the new scleral lenses for keratoconus are very helpful in patients who don't have good spectacle-corrected vision, and then there are a number of surgical procedures that are now available," shares Dr. Hersh. "One of the things that we're particularly interested in is what we called CTAK, or corneal tissue addition keratoplasty, in which we use a shaped allograft to preserve corneal tissue in order to improve corneal topography and vision. But that's really separate and distinct from the need for retreating for progression."

### Pearls for CXL

There are ways to mitigate complications following CXL. While precautions can be made to avoid infection by keeping the procedure sterile, evaluation of each patient prior to treatment can help avoid any surprises that may occur.

"Good patient selection and



S. Bhini, MD

**Corneal collagen cross-linking was approved for keratoconus in 2016, and has been effective in treating cases in the center and periphery of the cornea. Also, it's able to treat other peripheral conditions such as pellucid marginal degeneration.** (Creative Commons License: <https://creativecommons.org/licenses/by-nc/4.0/>.)

preoperative comprehensive discussion with patients regarding risk/benefits [helps prevent complications]," says Dr. Kang. "I discuss in detail what to expect and the importance of follow-up and adherence to treatment recommendations."

Dr. Hersh shares how his clinic selects the right patient for CXL. "What you want to do is evaluate the ocular surface and any ocular surface disease should be treated [prior to cross-linking]," he says. "This includes dry eye, blepharitis and meibomian gland dysfunction. So, we recommend a complete ocular surface examination and observe tear breakup time and perhaps look at imaging of the tear film. Some people will also use tear-film osmolarity. So, we recommend that any ocular surface, dry eye, tear film abnormality or blepharitis be treated beforehand. I think this is one of the most important things in preventing a complication."

In some cases, adjusting the position of the UV light can help, but ensure that the limbus is protected when cross-linking the

periphery of the eye. "Sometimes for very peripheral cones, we might de-center the UV light somewhat toward the periphery of the cornea. Although there hasn't been enough proven data that that affects the limbal stem cells, you're clearly shining more of the UV light in that area, so sometimes we'll place a limbal protector around that area to prevent the light from hitting it, but that's for specific cases. We don't do that across the board." He notes that post-LASIK ectasia patients sometimes present with peripheral cones, in which case he'll de-center the UV light and add protection to the limbus.

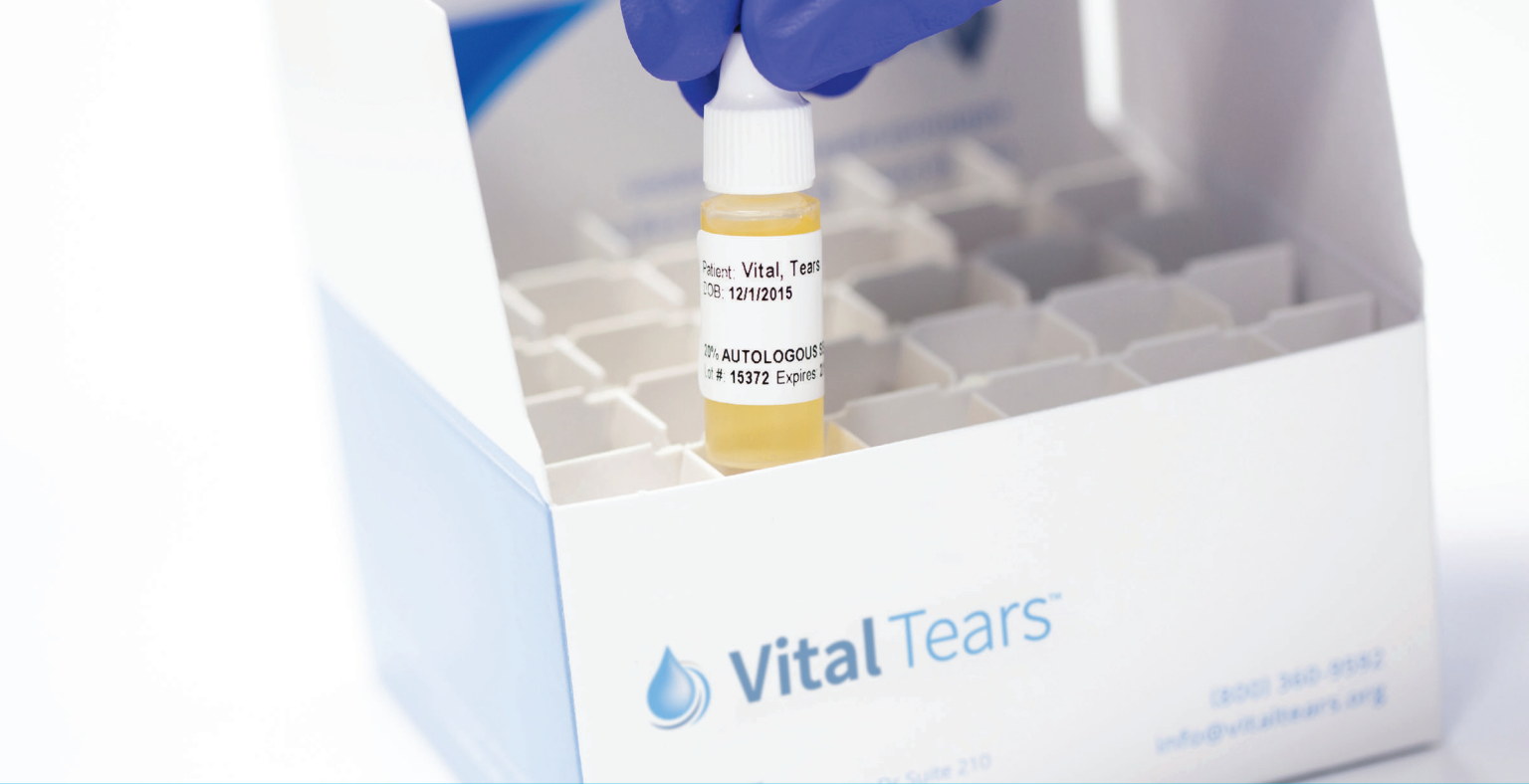After the procedure, there are a host of options to avoid complications. For instance, Dr.

Feldman provides his patients with UV light-blocking sunglasses and requires patients to wear them for three months after treatment. In addition, physicians try to keep the cornea lubricated, possibly with a bandage contact lens, to ensure re-epithelialization. But Dr. Feldman notes that an epithelial defect may persist even with the presence of a bandage contact lens covering exposed nerve endings, since the epithelium was removed during the procedure.

### Talking with Patients

Keep in mind that CXL is a relatively safe and effective procedure, but physicians can't always rely on preoperative and postoperative treatment management. Patients must be made aware of the signs and symptoms of their case as early as possible to alleviate treatment burden. "From a public health point of view, the field would be greatly helped and the loss of vision from keratoconus would be dramatically reduced if patients were recognized early and received proper treatment early on," states Dr. Hersh.

When a patient walks into the clinic presenting with keratoconus or



# Serum Tears Made **Easy, Fast & Safe**

We make it easy for you and your patients to get a **six-month supply of serum tears** from a single blood draw, with **turnaround times as quick as 48 hours** from the blood draw appointment.

Simply place your order online and then Vital Tears takes care of the rest.

## 1

We contact the patient to schedule the blood draw and collect payment.

## 2

Blood is drawn at one of our 400+ contracted facilities or by a mobile phlebotomist.

## 3

Serum tears are processed using rigorous, validated safety procedures then shipped directly to the patient.



Learn more about incorporating serum tears into practice from a panel of eye care leaders.

 **Vital Tears™**



Getty Images

**Patients might not understand how cross-linking treats their condition. Ensure each patient is informed about the procedure, its outcomes and any possible complications that may arise.**

some other CXL-treated condition, begin a conversation with them. Every physician's goal is to satisfy their patients' needs, and that's reliant on how much the patient complies to the treatment plan.

"The most critical thing with cross-linking is to really drill into patients that this is a stabilizing procedure," comments Dr. Greenstein. "Patients expect results that'll improve their situation when they go through a procedure anywhere on the body. So, when it comes to eye procedures, patients are expecting that the procedure is going to improve their vision. While all of our studies have indicated that cross-linking, on average, does slightly improve spectacle-corrected vision, those changes are incredibly small, and for the vast majority of our keratoconus patients, they're not really noticeable.

"We have other procedures that can help with improving corneal curvature and vision, but the key is to stress the stability component of the procedure and that we don't expect

things to get better from a vision standpoint, or even significantly from a curvature standpoint, simply by doing cross-linking alone," he continues.

### Advancements Towards Safety and Efficacy

Dr. Thulasi says certain advancements are improving CXL and improving the safety and efficacy of the procedure. "There are three groups of people I can think of where we could use advancements," she explains. "One is to decrease risk of complications of infection and pain. So, epithelium-on cross-linking, at least according to the data that we have so far, shows efficacy. It essentially eliminates any pain. So, that's something we're very excited about.

"The second issue is that cross-linking is a really long procedure," she continues. "It takes an hour and a half during which a patient has to sit in a room. And so, there are accelerated cross-linking and certain variable-fluence cross-linking that do

decrease the duration significantly, and that would increase tolerance. It would allow us to do cross-linking on patients such as kids or patients with Down syndrome or other patients where they wouldn't be able to stay still for about an hour. So, that would really expand the number of patients we could offer this to safely.

"And the third issue is that patients who come in with advanced keratoconus who are already below the threshold of 400 microns don't have the required corneal thickness for treatment," she continues. "So, there are some newer ideas out there. One being contact lens-assisted cross-linking, which can artificially boost the thickness of the cornea, so to speak, and prevent complications. There's also some interesting research on this method. Investigators are individualizing the duration of cross-linking to each person's corneal thickness and that would certainly allow for effective treatment without ruling all these patients out and letting them progress to needing a corneal transplant. So, those would be the groups that could use these advancements. I think some of these advancements are very exciting in those particular subgroups." ◀

1. And MJ, Darbinian JA, Hoskins EN, et al. The safety profile of FDA-approved epithelium-off corneal cross-linking in a US community-based healthcare system. *Clinical Ophthalmology* 2022;16:1117-1125.

2. Greenstein SA, Fry KL, Bhatt J, Hersh PS. Natural history of corneal haze after collagen crosslinking for keratoconus and corneal ectasia: Scheimpflug and biomicroscopic analysis. *J Cataract Refract Surg* 2010;36:12:2105-14.

3. Agarwal R, Jain P, Arora R. Complications of corneal collagen cross-linking. *Indian J Ophthalmol* 2022;70:5:1466-1474.

4. Wilson SE. Topical losartan: Practical guidance for clinical trials in the prevention and treatment of corneal scarring fibrosis and other eye diseases and disorders. *J Ocul Pharmacol Ther* 2023;39:3:191-206.

5. Rigas B, Huang W, Honkanen R. NSAID-induced corneal melt: Clinical importance, pathogenesis, and risk mitigation. *Surv Ophthalmol* 2020;65:1:1-11.

6. Farrokhpour H, Soleimani M, Cheraqpour K, et al. A case series of infectious keratitis after corneal cross-linking. *J Refract Surg* 2023;39:8:564-572.

7. Koller T, Mrochen M, Seiler T. Complication and failure rates after corneal crosslinking. *J Cataract Refract Surg* 2009;35:8:1358-62.

8. Chanbour W, El Zein L, Younes MA, et al. Corneal cross-linking for keratoconus and post-LASIK ectasia and failure rate: A 3 year follow-up study. *Cureus* 2021;13:11:e19552.





EDITED BY KULDEV SINGH, MD, MPH,  
AND PETER A. NETLAND, MD, PHD

## GLAUCOMA MANAGEMENT

# Intraocular Tumors And Glaucoma

*Benign or malignant, a tumor in the eye can lead to rising pressures and difficult-to-treat glaucoma.*

CAROL L. SHIELDS, MD  
PHILADELPHIA

**W**hen dealing with glaucoma secondary to intraocular tumors, it's essential to have a systematic approach. These cases can be complex, often requiring a careful evaluation to differentiate between typical glaucoma causes and those linked to tumors. If there's a tumor, glaucoma management efforts must be planned with care.

Here, I'll review the most common types of intraocular tumors that should be on every glaucoma specialist's radar and discuss the crucial treatment do's and don'ts.

## The First Signs

When assessing a patient, the glaucoma specialist should consider intraocular tumor if the patient has unilateral or refractory glaucoma. It's essential to rule out a tumor, particularly if there are additional signs such as melanocytosis—pigmentation of the sclera—or if gonioscopy reveals a brown hue in the anterior chamber angle. These features strongly suggest the potential for melanoma. With unilateral glaucoma, it's crucial to determine the underlying cause, as a small minority of cases may be due to intraocular tumors, which aren't limited to melanoma alone; other types of intraocular tumors can

also lead to glaucoma.

## Glaucomatous Mechanisms

Intraocular tumors can cause glaucoma in a number of ways. One of the most common mechanisms involves angle invasion from the tumor, which can be seen with iris melanoma, ciliary body melanoma that invades the iris or even melanocytoma—a benign tumor that, while not malignant, can drop pigment into the angle, leading to glaucoma. This results in tumor-related open-angle glaucoma.

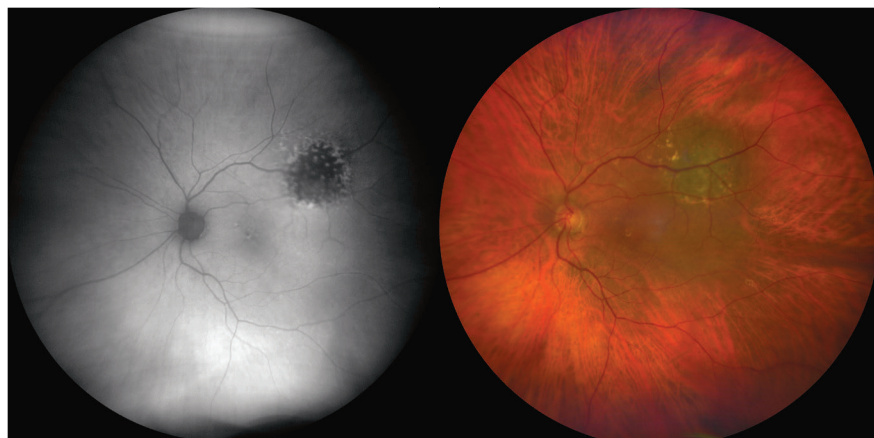
A second common mechanism is neovascular glaucoma, where the tumor produces excessive VEGF, or in cases of retinal detachment, causes neovascularization of the iris in the

anterior segment, which then leads to glaucoma. While neovascular glaucoma is very rare with melanoma or metastasis, it can occur, particularly when a patient has a significant retinal detachment, as the ischemic retina promotes the development of NVI.

## Intraocular Tumors

The most common tumors that produce secondary glaucoma are iris melanoma or ciliary body melanoma with angle invasion. Uveal melanomas represent 5 percent of all melanoma (including skin melanoma) diagnosed in the United States.<sup>1</sup> Secondary glaucoma has been reported to occur in 33 percent of eyes with iris melanoma, with significantly higher rates in American Joint Committee on Cancer Classification category T4 versus T1.<sup>2</sup>

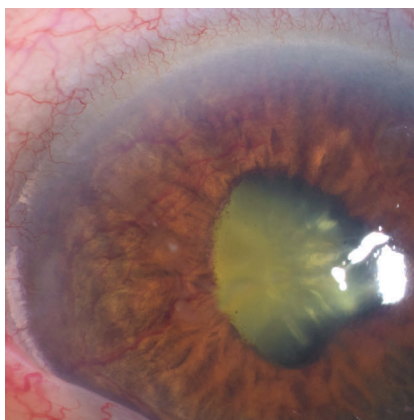
It's crucial not to wait for the patient suspected of having iris melanoma to exhibit extraocular extension; instead, examine the angle for brown pigmentation. If it appears brown, perform an ultrasound biomicroscopy and check the retina with indirect ophthalmoscopy-induced scleral depression to see if there's any pigmented mass posteriorly.



**Figure 1.** Autofluorescence and fundus photography showing dense vitreous hemorrhage in an 86-year-old woman with choroidal melanoma with neovascular glaucoma and loss to follow-up for three years.

This article has no commercial sponsorship.

Dr. Singh is a professor of ophthalmology and chief of the Glaucoma Division at Stanford University School of Medicine. He is a consultant to Alcon, Allergan, Santen, Sight Sciences, Glaukos and Ivantis. Dr. Netland is Vernah Scott Moyston Professor and Chair at the University of Virginia in Charlottesville.



**Figure 2. An external photograph of the same patient from Figure 1, showing iris neovascularization.**

If uncertainty remains, refer the patient to an ocular oncologist, who can perform a fine needle aspiration biopsy to confirm whether the pigmentation in the angle is or isn't a tumor. We frequently use fine needle aspiration biopsy in our practice.

A specific form of iris melanoma infiltrates the trabecular meshwork. Patients with this type of melanoma typically present with eye pain and elevated intraocular pressure. Upon examining the angle, if it appears chocolate brown, this raises the suspicion of melanoma localized to the trabecular meshwork. At that point, we'd perform a fine needle aspiration biopsy to sample the trabecular meshwork. If melanoma is detected, we proceed to irradiate the entire anterior segment, including the trabecular meshwork and a bit of the ciliary body, to ensure that all affected cells are treated.

In cases of iris metastasis, secondary glaucoma has been reported to occur in 37 percent of eyes.<sup>3</sup> Treatment with anti-VEGF agents such as ranibizumab<sup>4</sup> and bevacizumab<sup>5,6</sup> has shown success in secondary neovascular glaucoma. Iris metastasis manifests as yellow, white or pink nodules in the iris stroma. Hyphema or pseudohyphema may be present as well, along with poorly defined iris thickening and iridocyclitis.

Ciliary body melanoma, or ring melanoma, as its other name suggests, extends in a ring-like fashion around

the ciliary body. It's often missed on the exam, but there are several diagnostic clues that indicate its presence, including shadow on transillumination, multilobular mass and bulging episcleral veins.<sup>7</sup>

Melanoma of the choroid has a pigmented, dome or mushroom-shaped appearance. It's often accompanied by subretinal fluid, orange pigment and exudative retinal detachment. This type of melanoma accounts for 90 percent of all uveal melanomas, and secondary glaucoma occurs in 2 percent of cases.<sup>8</sup> Cream-colored or yellow lesions may be indicative of choroidal metastasis. This condition is often associated with serous retinal detachment. Secondary glaucoma occurs in 1 percent of cases.<sup>9</sup>

Retinoblastoma and retinal astrocytic hamartoma can also result in secondary glaucoma.<sup>9</sup> Among children, retinoblastoma is the most common malignant intraocular tumor and leads to secondary glaucoma in 17 percent of cases.<sup>9</sup> Its white, elevated lesions located in the sensory retina are accompanied by afferent and efferent blood vessels and intratumoral calcification. Retinal astrocytic hamartoma is benign but in rare instances may cause iris neovascularization, leading to secondary glaucoma. It appears as a slightly elevated, transparent or white lesion in the retinal nerve fiber layer.

When evaluating a child with unilateral glaucoma, it's crucial to check the fundus for retinoblastoma or retinal detachment and to examine the ciliary body for medulloepithelioma, a very rare nonpigmented ciliary epithelial tumor of which we encounter, on average, only two cases per year. These tumors are often misdiagnosed long-term because clinicians may not think to look in the ciliary body. Ultrasound biomicroscopy or anterior segment OCT can help image the ciliary body, especially in cases of neovascular glaucoma. Before inserting a tube shunt or performing any manipulation, a full exam under anesthesia to exclude medulloepithelioma is warranted.

In adults, neovascular glaucoma typically arises from classic conditions

like diabetic retinopathy, ocular ischemic syndrome, or central retinal vein obstruction—vasculopathic causes. However, in children presenting with neovascular glaucoma, the suspicion should be for tumors, primarily retinoblastoma or medulloepithelioma, and potentially juvenile xanthogranuloma, which can lead to vascular changes in the iris. This highlights the different focuses in diagnosis: vasculopathic in adults versus tumor-related in children. If you see a child with unilateral neovascular glaucoma, it's essential to investigate thoroughly; you may not find an ischemic retina, but rather a small ciliary body medulloepithelioma, which can be as tiny as a pea or even smaller, yet still produce extensive neovascular glaucoma with ectropion, making early detection vital.

## Misdiagnoses

Intraocular tumors can be overlooked in unilateral open-angle glaucoma, though other masqueraders are possible. In one case report, non-Hodgkin lymphoma of the iris masqueraded as uveitis-glaucoma-hyphema syndrome.<sup>10</sup>

Usually, glaucoma specialists are comfortable with gonioscopy and would notice that the angle appears brown in color or irregularly pigmented. If there's an iris mass, they may consider iris melanoma with seeding.

However, in cases of trabecular meshwork melanoma, general ophthalmologists might diagnose the patient with unilateral glaucoma and start treatment with eye drops. When the glaucoma remains uncontrolled, they may increase the medication or add more drops before eventually referring the patient to a glaucoma specialist. Upon conducting thorough gonioscopy, the specialist might observe that the angle does look brown and then refer the patient to an ocular oncologist. This process can lead to delays of six months or even a year on eye drops while the tumor continues to develop.

I can't emphasize enough how important UBM is in these cases. We perform UBM by taking images at

NANODROPPER

Learn more at  
NANODROPPER.com  
10% off: **ROPHM10**



# STOP SWIMMING IN YOUR EYEDROPS



Triple bottle life<sup>1</sup>



Reduce cost



Improve side  
effects<sup>2-4</sup>

"My dry eye has  
cleared up  
significantly since I  
started using the  
Nanodropper for  
Rocklatan."

- *Glaucoma Patient*

[pro@nanodropper.com](mailto:pro@nanodropper.com)

(507) 405-5676 ext.2

**References:** 1. St. Peter et al. Reduction of Eyedrop Volume for Topical Ophthalmic Medications with the Nanodropper Bottle Adaptor. *Med Devices (Auckl)*. 2023. 2. Steger et al. An Evaluation of the Efficacy and Safety of Timolol Maleate 0.5% Microdrops Administered with the Nanodropper®. *Ophthalmology*. 2024. 3. <https://nanodropper.com/whitepaper>. 4. Nanodropper, Inc. data on file.

© 2024 Nanodropper, Inc. All rights reserved. Nanodropper and the associated logos are trademarks of Nanodropper, Inc.

every clock hour—12 o'clock, 1 o'clock, 2 o'clock, 3 o'clock and so on—to confirm that there's no solid mass in the ciliary body.

If there's still a question as to whether or not an intraocular tumor is present, obtaining a good MRI can be very helpful. An MRI will show you a medulloepithelioma, which is often quite small and can still promote neovascular glaucoma. It's believed that medulloepithelioma releases VEGF, leading to neovascular glaucoma. If you can't determine the cause, an MRI is warranted. Ensure that thin slices are taken through the globe—both axial and coronal cuts—to thoroughly visualize the ciliary body and confirm that nothing is missed. We typically obtain T1 with fat suppression plus gadolinium, as well as T2 images.

In our practice, we typically see a patient with an intraocular tumor causing glaucoma about once every month or two. The first thing we emphasize in our correspondence to referring doctors is, "Please don't perform a trabeculectomy, tube shunt, or MIGS," because we worry that tumor spread through the globe opening could occur. Our approach is to treat the tumor first, then manage with topical drops, and finally consider cyclophotocoagulation. This is about all we can offer the patient, as we want to avoid opening the eye.

### Managing Tumor-induced Glaucoma

Is it safe to insert a tube shunt, perform a trabeculectomy or place a MIGS valve in these patients? The answer is yes, it can be done, but the tumor should hopefully be treated first. We avoid any open globe surgery if the patient has iris melanoma, but it's fine to perform this surgery after treatment of choroidal melanoma in the back of the eye.<sup>11</sup> We recommend the first line of treatment for treated iris melanoma be topical drops, and if those fail, cyclophotocoagulation.

Coping with glaucoma secondary to intraocular tumor, especially iris melanoma, is a long and challeng-

TABLE 1. FREQUENCY AND MECHANISM OF SECONDARY GLAUCOMA BY TUMOR TYPE

Tumor Type	Mechanism for Glaucoma	Frequency of Secondary Glaucoma
Iris melanocytoma	Seeding into angle	11 percent
Iris melanoma (nodular or diffuse)	Angle invasion, NVI, hyphema	33 percent
Iris melanoma (TM type)	TM infiltration	100 percent
Iris metastasis	Angle invasion, NVI	37 percent
Iris lymphoma	Angle invasion, NVI	29 percent
Ciliary body melanoma	Angle invasion, seeding into angle, angle closure, NVI	35 percent
Choroidal melanoma	Angle invasion, angle closure, NVI, hyphema, suprachoroidal hemorrhage	2 percent
Choroidal metastasis	Angle closure, NVI	1 percent
Retinoblastoma	Angle closure, tumor seeding, NVI	17 percent
Medulloepithelioma	Angle invasion, angle closure, NVI	44 to 46 percent

Adapted from Camp DA et al.<sup>9</sup>

ing journey for the patient, as we're unlikely to permit a tube shunt or trabeculectomy due to the risk of seeding the tumor outside the eye. Tumor seeding could lead to more serious complications, including dead or viable tumor in the orbit. For choroidal melanoma, tube shunt or trabeculectomy can be employed after treatment of the melanoma.

This presents a difficult scenario, which is why many patients with glaucoma resulting from an intraocular tumor undergo enucleation. However, if the pressure isn't excessively high, it's sometimes possible to manage it effectively while preserving vision. Once the pressure rises to around 45 to 50 mmHg, though, enucleation is necessary, as nothing can effectively lower the pressure if the eye has a tumor infiltrating the angle.

At Wills Eye Hospital, we've encountered all sorts of cases where the glaucoma was discovered and the tumor remained hidden. In these cases, if glaucoma surgery is performed before tumor treatment, the conjunctiva might eventually turn black from

hidden melanocytoma or melanoma seeding into the subconjunctival space. So again, with unilateral glaucoma, it's crucial to ensure there's no underlying tumor.

Missing an intraocular tumor is a fear shared by all glaucoma specialists. To ensure there's no tumor present, it's common to refer patients with unilateral glaucoma and unclear causes for further examination, and we're happy to assist. We conduct a comprehensive examination of both the anterior and posterior segments, performing ultrasound biomicroscopy, anterior segment OCT and even transilluminate the eye to detect any abnormalities in the ciliary body. We also perform a fundus evaluation that includes scleral depression all the way up to the pars plana to make sure we can see everything.

### Tumor Management

Intraocular tumors can be addressed in several ways, depending on the specific tumor. Some management options include observation, local resection, plaque radiotherapy, enucleation and systemic chemotherapy.

# Find the perfect fit for your practice

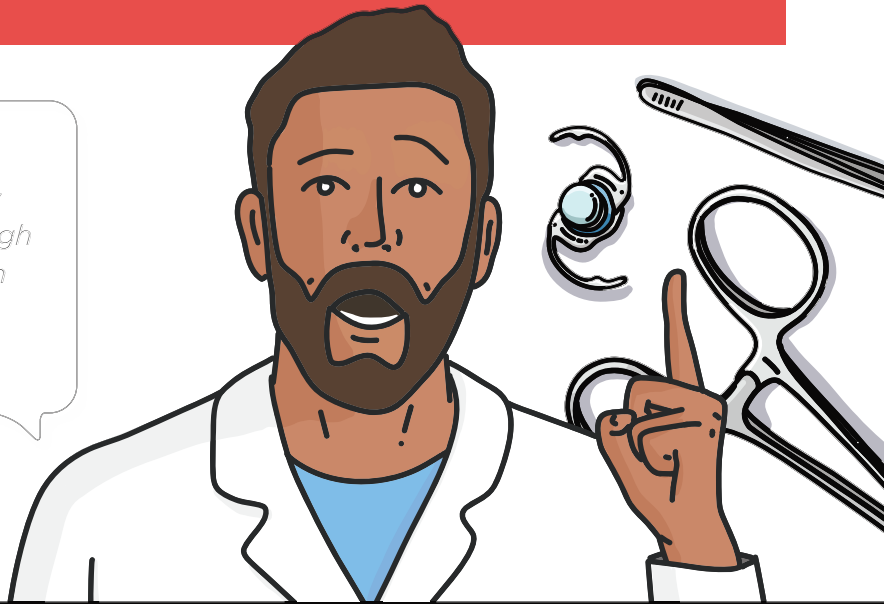Generic job boards not getting results? Add your job listing to eyecare's #1 job board to connect with the largest network of active and passive job seekers.

## STARTING AT \$249, OUR JOB BOARD OFFERS:

- ✓ An applicant tracking system and email blasts
- ✓ Syndication to major job platforms and our affiliate network, including in Vision Monday, 20/20 Magazine, and other leading eyecare publications
- ✓ Applications that come straight to your inbox so you can expedite top candidates

*"I had such a wonderful experience using Eyes On Eyecare. It was so easy to post a job and they walk you through the entire process. I recommend them to everyone I know."*

*- Ashley Wojcik*



PROUD PARTNER OF JOBSON OPTICAL GROUP

Save time and hire faster with Eyes On Eyecare  
Learn more at [eyesoneyecare.com/hire-now](https://eyesoneyecare.com/hire-now)

**eyes on**  
EYECARE

**REVIEW**  
of OPTHALMOLOGY

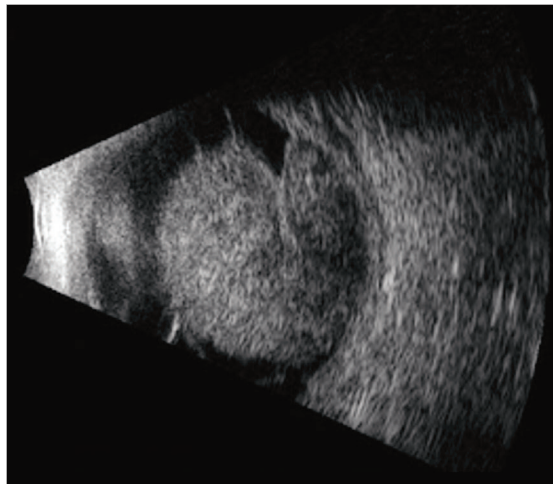
Years ago, we conducted a study of retinoblastoma and found that about 15 percent of retinoblastomas have NVI. In the past, we would enucleate those eyes, but nowadays we treat them with chemotherapy: The tumor shrinks, the retinal detachment resolves and the NVI disappears. Recently, we had a new pediatric patient with NVI and a large retinoblastoma that we managed with intra-arterial chemotherapy.

Unfortunately, the same approach doesn't quite apply to melanoma. Most melanoma cases with NVI involve very large tumors that are less responsive to regression from radiotherapy. However, we now have a new drug called darovasertib, which we're using with large melanomas. This medication is used in a neoadjuvant setting, which means if a patient presents with a large tumor and is heading towards enucleation, we can administer this chemotherapy to shrink the tumor. Our hope is that it will even resolve retinal detachment and neovascular glaucoma. Currently, it's in Phase II/III (NCT05987332),<sup>12</sup> and as of now, glaucoma—or any type of glaucoma—is an exclusion criterion, though NVI is not. But down the road, once it's hopefully approved by the FDA, we may use it to reduce tumors and resolve NVI. This represents a major breakthrough in ocular oncology.

### Co-management

Collaboration and good communication are vital when co-managing a patient with ocular oncology. If we see an iris melanoma, we know our radiotherapy for the tumor might create a cataract. We advise that the cataract should be left alone for at least three years to ensure all tumor activity is under control. This is a key guideline we teach all glaucoma specialists and cataract surgeons.

We don't permit any open globe procedures—no trabeculectomies, no tube shunts and no MIGS, for patients with iris melanoma. We want



**Figure 3. Ultrasound revealed a large tumor in the patient from Figure 2. Enucleation was performed for this case.**

to avoid filtering the aqueous into the subconjunctival space, as that could lead to bigger problems such as orbital tumor, access to blood vessels and lymphatics, and from there to potential metastatic disease.

If a tube shunt is inadvertently placed before a tumor is detected, we always remove the eye with the tube shunt in place. This is a rare occurrence; it happens once or twice a year. A patient presents with unilateral glaucoma, and the glaucoma specialist treats it with a tube shunt, only for a tumor to be discovered later. In such cases, we remove the eye and tube shunt as one specimen, and then we walk it to our pathology lab. They section everything—the globe, the tube and the valve—and we also take a sample of the orbit where the valve was to check for any deposition of seeds into the orbit. Most of the time, the results are negative, which is good news. If there's any doubt, we irradiate the socket.

### The Takeaway

Establish your routine for evaluating a patient with unilateral glaucoma. Start with a thorough slit lamp exam and a comprehensive fundus exam to rule out diabetic retinopathy, CRVO, ocular ischemic syndrome or even tumor. Perform gonioscopy to check for pigment in the angle or disinsertion of the iris from its scleral attachment,

which could indicate a small melanoma. Don't forget to get UBM to ensure there's no ciliary body mass.

By following an organized evaluation, you'll likely catch most cases and rule out other conditions. However, if you're still in doubt, get an MRI with gadolinium. This will help confirm that there's no tumor in the eye. And if you're still unsure, consult with an ocular oncologist for a thorough evaluation. ◀

1. Chattopadhyay C, Kim DW, Gombos DS, et al. Uveal melanoma: From diagnosis to treatment and the science in between. *Cancer* 2016;122:15:2299-2312.

2. Shields CL, Di Nicola M, Bekerman VP, et al. Iris melanoma outcomes based on the American Joint Committee on Cancer Classification (eighth edition) in 432 patients. *Ophthalmology* 2018; 125:913-923.

3. Shields CL, Kaliki S, Crabtree GS, et al. Iris metastasis from systemic cancer in 104 patients: The 2014 Jerry A. Shields Lecture. *Cornea* 2015; 34:42-48.

4. Makri OE, Psachoulia C, Exarchou A, Georgakopoulos CD. Intravitreal ranibizumab as palliative therapy for iris metastasis complicated with refractory secondary glaucoma. *J Glaucoma* 2016;25:e53-e55.

5. Seidman CJ, Finger PT, Silverman JS, Oratz R. Intravitreal bevacizumab in the management of breast cancer iris metastasis. *Retin Cases Brief Rep* 2017;11:47-50.

6. Aydin A, Tezel TH. Use of intravitreal bevacizumab for the treatment of secondary glaucoma caused by metastatic iris tumor. *J Glaucoma* 2018; 7:e113-e116.

7. Demirci H, Shields CL, Shields JA, et al. Ring melanoma of the ciliary body: Report on twenty-three patients. *Retina* 2002;22:698-706.

8. Shields CL, Shields JA, Shields MB, Augsburger JJ. Prevalence and mechanisms of secondary intraocular pressure elevation in eyes with intraocular tumors. *Ophthalmology* 1987;94:839-846.

9. Camp DA, Yadav P, Dalvin LA, Shields CL. Glaucoma secondary to intraocular tumors: Mechanisms and management. *Curr Opin Ophthalmol* 2019;30:2:71-81.

10. Gauthier AC, Nguyen A, Munday WR, et al. Anterior chamber non-Hodgkin lymphoma of the iris masquerading as uveitis-glaucoma-hyphema syndrome. *Ocul Oncol Pathol* 2016; 2:230-233.

11. Kaliki S, Eagle RC, Grossniklaus H, et al. Inadvertent implantation of aqueous tube shunts in glaucomatous eyes with unrecognized intraocular neoplasms: Report of 5 cases. *JAMA Ophthalmol* 2013; 131:925-928.

12. DE196 (darovasertib) in combination with crizotinib as first-line therapy in metastatic uveal melanoma. <https://clinicaltrials.gov/study/NCT05987332>. Accessed October 7, 2024.

### ABOUT THE AUTHOR



**Dr. Shields** is the director of the Ocular Oncology Service at Wills Eye Hospital, a professor of ophthalmology at Thomas Jefferson University and a consultant at Children's Hospital of Philadelphia. She has no related financial disclosures.



EDITED BY CARL REGILLO, MD,  
AND YOSHIHIRO YONEKAWA, MD

RETINAL INSIDER

# An Update on Radiation Retinopathy

*An expert look at risk factors, diagnosis and which treatment methods work best in various patient presentations.*

JENNA KRIVIT, BA BRISBANE, AUSTRALIA  
ANTONIO YAGHY, MD WORCESTER, MASS.  
LAUREN A. DALVIN, MD ROCHESTER, MINN.

**R**adiation retinopathy is a chronic and progressive retinal vasculopathy resulting from radiation to the orbit, globe, head or neck.<sup>1</sup> We use the term radiation maculopathy to describe RR limited to the macula, where vascular damage leads to the most significant changes in visual acuity. RR/RM is the most common cause of severe, irreversible vision loss in eyes treated with radiotherapy.<sup>2</sup>

Here, we'll highlight the diagnostic clues to watch for, the risk factors to take into account and the various treatment methods to consider when faced with a possible case of radiation retinopathy.

## Background

While this review will primarily focus on RR caused by treatment for intraocular tumors, such as uveal melanoma, it's crucial to recognize that radiation therapy for non-ocular neoplasms of the head, neck, and brain can also lead to this condition. In the case of intraocular tumors, we often use plaque brachytherapy, where a tiny radioactive plaque (about the size of a grain of rice) is inserted directly adjacent to the tumor. For extraocular tumors or, in some specific centers or

circumstances for intraocular tumors, proton beam irradiation, delivered externally, may be the preferred treatment method.

Radiotherapy has replaced enucleation for small, medium and some large uveal melanomas since the Collaborative Ocular Melanoma Study of 1985 demonstrated there was no difference in mortality between the two treatments for medium-sized choroidal melanoma.<sup>3</sup> As a result, radiation has become the go-to treatment, allowing us to preserve the eye, maintain useful vision and improve our patients' quality of life.

## Clinical Presentation and Diagnostics

Radiation to the orbit immediately disrupts the capillary endothelium and causes accumulation of fibrinous material within vascular walls, eventually leading to vessel occlusion and ischemia of the retina.<sup>4</sup> In RR, retinal ischemia presents with a variable spectrum of retinal nonperfusion, retinal capillary leakage, neovascularization and hemorrhage.<sup>5</sup> The pathology of RR is similar to diabetic retinopathy. In both diseases, vascular endothelial growth factor is released in response to ischemia and stimulates angiogenesis—or neovascularization of the retina—which poses well-known, significant problems

because the newly formed vessels are disorganized, weak and susceptible to leakage. Over time, these leaky vessels lead to edema and hemorrhage, which distort the retinal architecture and lead to the visual changes seen by these patients.

Vascular damage is hypothesized to begin immediately after the retina is exposed to radiation.<sup>2,6</sup> On average, clinical features of RR present about 32 months after treatment.<sup>7</sup> During a dilated fundus examination, you might spot macular edema, retinal hemorrhage, microaneurysms, cotton-wool spots, hard exudates and disc swelling. While these findings are similar to diabetic retinopathy, there are a couple of key differences to keep in mind. RR is more likely to be unilateral and tends to have fewer microaneurysms. By contrast, diabetic retinopathy often lacks atrophic retinal pigment epithelium.<sup>8</sup> Depending on the specific pathology at play, you might classify a patient's RR as exudative (due to endothelial tight junction damage and fluid accumulation), hemorrhagic (caused by capillary weakness or abnormal neovascularization) or atrophic (characterized by thinning of the retinal pigment epithelium and retinal disorganization).<sup>5</sup>

Fluorescein angiography is a sensitive test for the vascular impact of RR. Given the occlusive nature of RR, capillary non-perfusion is an early and consistent sign.<sup>9</sup> In the early 90s, a team at Queen's Hospital Belfast developed a staging system using FA to classify RR based on microvascular changes.<sup>10</sup> Later, the team at Wills Eye Hospital, led by Carol Shields, MD, created a classification system based on the severity of macular edema on optical coherence

This article has no commercial sponsorship.

**Dr. Regillo** is the director of the Retina Service of Wills Eye Hospital, a professor of ophthalmology at Thomas Jefferson University School of Medicine and the principle investigator for numerous major international clinical trials.

**Dr. Yonekawa** is an assistant professor of ophthalmology at Sidney Kimmel Medical College at Thomas Jefferson University. He serves on the Education Committee of the American Society of Retina Specialists and on the Executive Committee for the Vit Buckle Society, where he is also the vice president for academic programming.

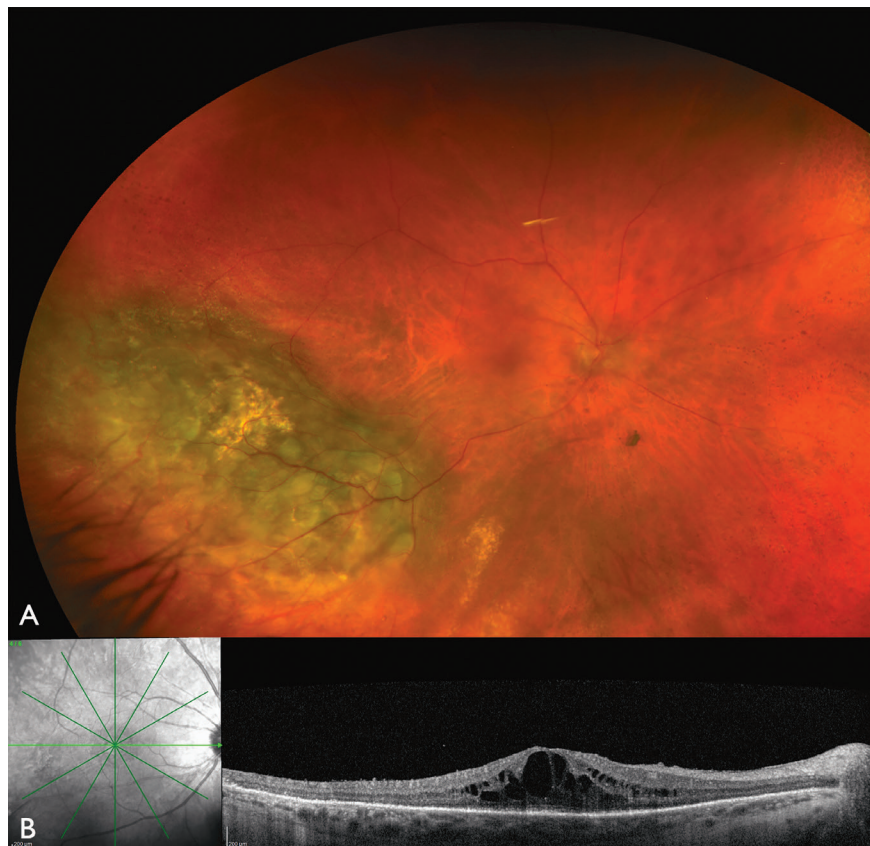
tomography.<sup>11</sup> OCT has become an incredibly valuable tool in detecting early macular edema even before we can see any signs of retinopathy during a clinical exam (*Figure 1*). In fact, studies have shown that macular edema can be present in up to 33 percent of eyes with no clinically apparent retinopathy.<sup>8</sup>

OCT-angiography is highly sensitive to vascular changes in RR, with high definition and delineation of the retinal layers allowing for quantification of capillary disruption.<sup>5</sup> A study from the Wills team in 2016 compared 65 patients with choroidal melanoma treated with plaque brachytherapy to non-irradiated patients. Using OCTA, they discovered enlargement of the foveal avascular zone and decreased capillary density, even in eyes without clinically evident RR.<sup>12</sup> In another study led by Alexandre Matet, MD, of the Jules-Gonin Eye Hospital in Switzerland, 93 patients underwent OCTA imaging, and the results were striking. They found that the same features—larger foveal avascular zone and decreased capillary density—were associated with worse visual acuity.<sup>13</sup> Since then, multiple other studies have echoed this link between OCTA and pre-clinical detection of vascular changes in RR.<sup>14,15</sup> It's become clear that OCTA is a sensitive tool for picking up on the subtle vascular changes that occur before we can see any clinical signs of RR.

This highlights the importance of multimodal imaging in early detection. By combining the powers of FA, OCT and OCTA, we can spot the earliest signs of RR and potentially intervene before irreversible damage occurs. As appropriate treatments are identified; this could be the key to preserving vision in irradiated eyes and giving our patients the best possible outcomes.

### Risk Factors

In 1999, a study from Wills Eye Hospital analyzed 1,300 patients with posterior uveal melanoma treated



**Figure 1. Color fundus photograph and optical coherence tomography of the right eye one year after plaque radiotherapy for uveal melanoma. (A) The color fundus photograph reveals regressed uveal melanoma inferotemporally with no overt retinal hemorrhages or exudates typical of radiation retinopathy. (B) The OCT, however, reveals cystoid macular edema, indicating the presence of radiation maculopathy.**

with plaque radiotherapy. They found that 42 percent of patients developed non-proliferative radiation maculopathy at the five-year mark, while 8 percent progressed to proliferative radiation maculopathy.<sup>16</sup> After three years, over half of the patients treated with plaque brachytherapy have visual acuity worse than 20/200 (*Figure 2*).<sup>3</sup> What factors influence the risk of developing visually significant RR? The dose of radiation and the location and size of the tumor play a crucial role. Tumors located within 4 mm of the foveola, or 5 mm of the optic disc are associated with an increased risk of RM.<sup>16,17</sup> Larger tumors require more radiation and are associated with increased rates of RR, especially tumors with thickness greater than 4 mm.<sup>18</sup>

When it comes to external beam radiation, cumulative doses greater

than 45 Gy and doses greater than or equal to 1.9 Gy per fraction have been linked to the development of RR.<sup>19</sup> However, a technique called hyperfractionation, where the total dose is divided into smaller fractions, can reduce the risk of RR in patients receiving more than a 50 Gy total dose.<sup>20</sup>

Nevertheless, radiation isn't the only factor at play. Patients with underlying vascular diseases, such as diabetes or hypertension, are more likely to develop RR.<sup>17,21</sup> In fact, for diabetic patients, the risk of visual loss from RR was reported to increase by a staggering 300 percent.<sup>22</sup> The synergistic effect of diabetes (affecting the pericytes) and radiation (affecting the endothelial cells) is a dangerous combination for the retinal vasculature. Age is another important



consideration. Younger patients, particularly those under 50, are at higher risk of developing RR.<sup>17,21</sup> This mirrors what we see in diabetes, where a younger age at presentation is associated with a higher risk of developing proliferative diabetic retinopathy.<sup>23</sup> A recent study from Wills Eye Hospital in 2020 looked at 1,131 eyes treated with prophylactic anti-VEGF therapy after plaque radiotherapy and confirmed that patients under 50 were more likely to develop both RM and RR compared to older age groups.<sup>24</sup>

In 2019, one of this article's authors (LD) and co-authors developed a nomogram for visual acuity after plaque radiotherapy based upon clinical risk factors.<sup>25</sup> They found the most important risk factors were initial presentation of the tumor with subretinal fluid involving four quadrants, tumor thickness >4 mm, presenting visual acuity ≤20/30, non-Caucasian race, tumor shape (mushroom, bilobed or multilobulated) and insulin-dependent diabetes.<sup>25</sup> Risk of poor visual acuity at two and four years increased from 11 percent and 24 percent with 40 nomogram points to 97 percent and >99 percent with 304 points.<sup>25</sup> These findings underscore the importance of individualized risk assessment and long-term monitoring for patients undergoing radiation therapy for ocular tumors. By understanding the factors that influence the development of RR, we can better counsel our patients, tailor our treatment strategies and work towards preserving vision in the face of this challenging complication.

## Management

When it comes to treating RR, our primary goals are to halt the progression of the disease and preserve visual acuity. It's important to note that currently, there's no FDA-approved treatment specifically for RR, and the therapies we'll discuss are considered "off-label" uses. The data in this field are largely derived from clinician-led pilot studies or retrospective chart reviews, and there is a notable scarcity

of large-scale randomized controlled trials.

• **Laser photocoagulation.** Before the era of anti-VEGF therapy, retinal laser therapies were the go-to treatment for RR. The idea was to kill off the ischemic tissues that were releasing VEGF and driving neovascularization. Multiple studies showed promising results, with panretinal photocoagulation or focal laser photocoagulation improving or stabilizing visual acuity and decreasing macular edema in patients with RR.<sup>26-29</sup> Panretinal photocoagulation can be especially useful in the setting of proliferative RR to cause lasting regression of neovascularization and prevent recurrent vitreous hemorrhage. However, there are some limitations to laser therapy, particularly when ocular tumors involve the fovea or optic disc. In these cases, the risks of laser treatment may outweigh the potential benefits.

“  
When it comes to treating radiation retinopathy, our primary goals are to halt the progression of the disease and preserve visual acuity.  
”

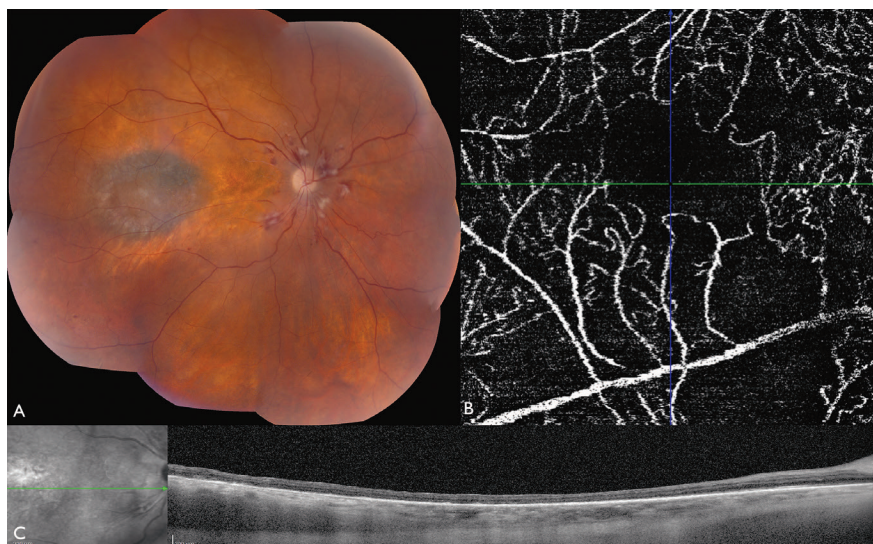
• **Anti-VEGF therapy.** Intravitreal anti-VEGF therapies have revolutionized the treatment of RR, much like they have for other ischemia-driven retinal pathologies. The mid-2000s marked a turning point in the management of RR, with the introduction of these game-changing medications. A 10-year prospective study from Dr. Paul Finger's team at New York Eye and Ear's ocular oncology service treated 120 patients with uveal melanoma who had developed macular vasculopathy after plaque brachytherapy. The results were impressive: Anti-VEGF agents

(bevacizumab and ranibizumab) were found to be both safe and effective in reducing macular edema, and 80 percent of patients maintained their visual acuity within two lines or better.<sup>6</sup>

Subsequently, Timothy Murray, MD, and his team at Bascom Palmer Eye Institute conducted a two-year prospective trial using aflibercept. They included 40 patients with uveal melanoma treated with plaque brachytherapy who had developed visually compromising radiation maculopathy. The results mirrored those of Dr. Finger's study: Aflibercept was deemed safe and effective for maintaining VA and reducing macular edema.<sup>30</sup>

Furthermore, aflibercept may be more effective as a second-line treatment in patients who've failed bevacizumab treatment for RR. A study in 2022 looked at 30 patients who had previously failed bevacizumab treatment. When switched to aflibercept, the patients showed both statistical and clinical improvement in VA and central foveal thickness.<sup>31</sup> The Aflibercept for Radiation Retinopathy Trial (ARRT) from Retinal Consultants of Texas took a slightly different approach. They conducted a small, randomized trial of 30 patients with clinical evidence of macular edema after radiation. The focus of the study was to investigate a "treat-and-extend" regimen of aflibercept injections.<sup>32</sup> The results were promising—96.7 percent of the entire cohort had VA better than 20/200 at one year, and the treat-and-extend group showed significant improvement in central retinal thickness (182.4 μm) and VA (6.69 letters).<sup>32</sup>

Another Phase IIb randomized trial, from the Ranibizumab for Radiation Retinopathy (RRR) Study Group, investigated the efficacy of a treat-and-extend ranibizumab regimen in 40 eyes with radiation-induced macular edema and decreased visual acuity.<sup>33</sup> During the first year, the cohort received monthly ranibizumab injections, which resulted in



**Figure 2. Montage color fundus photograph, optical coherence tomography angiography, and optical coherence tomography of the right eye three years after plaque radiotherapy for uveal melanoma. (A) The color fundus photograph shows signs of atrophic radiation retinopathy and maculopathy, including retinal hemorrhages and radiation papillopathy. OCTA reveals an enlarged foveal avascular zone (FAZ) and capillary dropout in the macular area. The disrupted and reduced capillary network indicates significant macular ischemia. (C) OCT shows thinning of the retina secondary to atrophy.**

statistically significant improvements in visual outcomes, with a gain of four letters, and a reduction in central macular thickness.<sup>33</sup> In the second year, the study protocol was modified to treat-and-extend ranibizumab to more closely mimic real-world clinical care.<sup>33</sup> At the end of the two-year study period, some of the initial visual improvements had regressed, with a loss of 1.9 letters compared to the end of year one. However, visual acuity remained above baseline levels, and the anatomic improvements in central macular thickness were maintained, with no significant change from baseline at the study's conclusion.<sup>33</sup>

Brolucizumab, a relatively new anti-VEGF agent, is currently undergoing testing for macular edema, including in the setting of RR patients who have failed prior anti-VEGF treatments. While there have been some concerns about intraocular inflammation and vasculitis with brolucizumab, it may still hold promise for complex eyes that have been unresponsive to aggressive intravitreal pharmacotherapy.<sup>34</sup>

To sum it all up, a recent systematic review and meta-analysis of seven studies, including a total of 922 patients, found that anti-VEGF therapy can significantly improve VA (-0.34 logMAR) and reduce central retinal thickness (-34.65  $\mu\text{m}$ ).<sup>35</sup> However, it's important to note that improving macular edema, as measured by OCT, doesn't always translate to improved visual outcomes, especially in eyes that have undergone ischemic changes or repeated periods of oxidative stress.

• **Steroids.** Corticosteroids have also been explored as a potential treatment option for RR, given their anti-inflammatory properties. The rationale behind their use is that radiation induces an inflammatory reaction in the retina, and steroids may help to mitigate this response. Several small studies have investigated the use of intravitreal dexamethasone or fluocinolone acetonide implants in the treatment of RR. A team from the University of Padova in Italy looked at 13 patients treated with intravitreal dexamethasone, while a

German study included five patients who received fluocinolone acetonide implants. Both studies reported improvements in macular edema and VA.<sup>36,37</sup>

Arun Singh, MD, and colleagues from the Cleveland Clinic Cole Eye Institute took a slightly different approach. They trialed "rescue" steroids in seven patients who had previously failed anti-VEGF treatment. These patients received fluocinolone acetonide implants, and the results showed stable VA and a reduction in central retinal thickness (-30  $\mu\text{m}$ ).<sup>38</sup> One of the potential advantages of steroid implants is that they reduce the burden of frequent intravitreal injections, which can improve patient satisfaction. However, the superiority of steroids over anti-VEGF therapy in the treatment of RR remains unclear. A study by Berlin's Ira Siebel and his colleagues in 2016 compared intravitreal anti-VEGF (n=38) with intravitreal steroids (n=35) and found no significant differences between the two treatment modalities.<sup>39</sup> It's important to approach the use of steroids cautiously in patients who have undergone radiation treatment. Steroids have the potential to exacerbate glaucoma or contribute to the development of radiation-induced cataract.

• **Prophylaxis.** The concept of prophylactic treatment for RR has gained significant attention in recent years, fueled by the advent of advanced imaging techniques like OCTA that allow for earlier detection of retinal vascular changes. The rationale behind this approach is to intervene before visual or clinical signs of RR develop, with the goal of preserving vision and preventing the progression of retinal damage.

One of the initial studies that sparked interest in prophylactic treatment was the 10-year anti-VEGF study by Dr. Finger and associates. While they found that anti-VEGF therapy improved the clinical manifestations of radiation maculopathy, the patients still developed evidence

of retinal microaneurysms, capillary nonperfusion and retinal telangiectasias.<sup>6</sup> This suggested that despite ongoing periodic anti-VEGF treatment, the disease process was progressive and required more intensive treatment over time.<sup>6</sup>

Drawing parallels to other progressive retinal vasculopathies, like diabetic retinopathy, where earlier intervention is associated with better outcomes, researchers began to investigate the potential benefits of prophylactic management of RR.<sup>2</sup> A study from Wills Eye Hospital, led by Carol Shields, MD, and associates, compared prophylactic bevacizumab (given every four months starting after plaque removal) with a historical control group who didn't receive bevacizumab.<sup>40</sup> This large 10-year retrospective study included 1,131 eyes and demonstrated that the treatment group had better visual acuity outcomes than the controls every year for four years.<sup>40</sup> There was also significantly less clinical evidence of RM at 24, 36 and 48 months, and less macular edema at 24 and 36 months.<sup>40</sup>

In the setting of proton beam irradiation for uveal melanoma, a pilot study from Mass Eye and Ear, led by Ivana Kim, MD, investigated prophylactic ranibizumab (given every two months for two years) in 40 patients. They found that 97 percent (30/31) of the prophylactic ranibizumab group had VA better than 20/200, compared to 42 percent (92/105) of controls.<sup>42</sup> This effect was more pronounced in small/medium tumors, likely due to the lower dose of radiation, with only a third (8/24) developing clinical evidence of radiation maculopathy versus 68 percent (42/62) of controls.<sup>42</sup> Tara McCannel, MD, PhD, from UCLA reported that vitrectomy with silicone oil tamponade in conjunction with plaque brachytherapy could be useful in preventing RR. This prophylactic silicone oil placement was found to reduce central macular thickness and improve VA in 20 patients undergoing treatment for uveal melanoma.<sup>43</sup>

Other treatment strategies have

been proposed to reduce the risk of radiation retinopathy, although their efficacy has yet to be reported. Image-guided radiation, a real-time imaging technique used to deliver external beam radiation directly to the tumor without damaging the surrounding healthy retina, is one such approach.<sup>44</sup> Dose hyperfractionation is another method.<sup>20</sup>

## Future Directions

The upcoming randomized clinical trial, Protocol AL, led by Arun Singh, MD, in the Diabetic Retinopathy Clinical Research Retina Network, is an exciting development in the field of RR research.<sup>45</sup> This study will evaluate how prophylactic, repeated injections of faricimab or fluocinolone acetonide implants affect long-term vision compared to initial observation and as-needed treatment for radiation side effects, with the goal of determining if these interventions can prevent or alter the course of macular edema and visual acuity outcomes related to RR.<sup>45</sup>

Another important aspect of this study is the evaluation of the natural history of RR using multimodal imaging techniques, such as fundus photography, FA and OCTA.<sup>45</sup> This comprehensive approach to monitoring the progression of RR will provide valuable insights into the disease process and may help to identify early markers of retinal damage that could guide future treatment strategies. The significance of this trial can't be overstated, as RR is a devastating consequence of radiation therapy that can have a profound impact on patients' quality of life.

As we have discussed throughout this review, RR is a common and visually significant complication, and its risks should be thoroughly discussed with patients undergoing radiation for ocular, head or neck malignancies.

The varied clinical presentations of RR highlight the importance of maintaining a high index of suspicion in any patient with a history of radiation exposure. Clinicians must

be vigilant in monitoring for signs of RR, even years after the initial treatment, and should consider multimodal imaging techniques to detect subtle changes in retinal vasculature before visual decline or overt clinical signs manifest.

Emerging evidence for the prevention of RR, particularly with the use of prophylactic anti-VEGF therapy, is promising and offers hope for delaying or reducing the incidence and severity of this condition. However, current management strategies still primarily aim to prevent progression and further visual loss once RR has developed.

Treatment options for RR are varied and often mirror the treatments available for other common vasculopathies, such as diabetic retinopathy. These include anti-VEGF agents, corticosteroids and laser photocoagulation. However, it's important to acknowledge that the evidence for these treatments in the specific context of RR is limited, with most studies being small and retrospective in nature.

In conclusion, RR remains a significant challenge for patients undergoing radiation therapy for certain malignancies. The upcoming DRCR Retina Network trial, Protocol AL, represents an important step forward in our understanding of this condition and the potential for early intervention to prevent or mitigate vision loss.

In the years to come, we'll have a stronger evidence basis for RR management decisions as a result of this trial. In the meantime, as clinicians, it's our responsibility to remain vigilant in monitoring for signs of RR, to use the latest imaging techniques to detect early changes in retinal vasculature, and to provide our patients with the best available evidence-based care.

While there's still much work to be done in this field, the future holds promise for improving outcomes and preserving vision in patients at risk for radiation retinopathy. ◀

*This publication was supported by CTSA Grant Number KL2 TR002379 from the National Center for Advancing Translational Science (NCATS). Its contents are solely the responsibility of the authors and do not necessarily represent the official views of the NIH.*

1. Ramos MS, Echegaray JJ, Kuhn-Asif S, Wilkinson A, Yuan A, Singh AD, et al. Animal models of radiation retinopathy—From teletherapy to brachytherapy. *Exp Eye Res* 2019;181:240-51.
2. Powell BE, Chin KJ, Finger PT. Early anti-VEGF treatment for radiation maculopathy and optic neuropathy: Lessons learned. *Eye (Lond)* 2023;37:5:866-74.
3. Diener-West M, Earle JD, Fine SL, Hawkins BS, Moy CS, Reynolds SM, et al. The COMS randomized trial of iodine 125 brachytherapy for choroidal melanoma, III: Initial mortality findings. COMS Report No. 18. *Arch Ophthalmol* 2001;119:7:969-82.
4. Zamber RW, Kinyoun JL. Radiation retinopathy. *West J Med* 1992;157:5:530-3.
5. Chen K, Browne AW. Radiation Retinopathy. *Current Ophthalmology Reports* 2023;11:3:49-56.
6. Finger PT, Chin KJ, Semenova EA. Intravitreal anti-VEGF therapy for macular radiation retinopathy: a 10-year study. *Eur J Ophthalmol* 2016;26:1:60-6.
7. Bianciotto C, Shields CL, Priondini C, Mashayekhi A, Furuta M, Shields JA. Proliferative radiation retinopathy after plaque radiotherapy for uveal melanoma. *Ophthalmology* 2010;117:5:1005-12.
8. Sahoo NK, Ranjan R, Tyagi M, Agrawal H, Reddy S. Radiation retinopathy: detection and management strategies. *Clin Ophthalmol*. 2021;15:3797-809.
9. Brown GC, Shields JA, Sanborn G, Augsburger JJ, Savino PJ, Schatz NJ. Radiation retinopathy. *Ophthalmology* 1982;89:12:1494-501.
10. Amoaku WM, Archer DB. Fluorescein angiographic features, natural course and treatment of radiation retinopathy. *Eye (Lond)* 1990;4(Pt 5):657-67.
11. Horgan N, Shields CL, Mashayekhi A, Teixeira LF, Materin MA, Shields JA. Early macular morphological changes following plaque radiotherapy for uveal melanoma. *Retina* 2008;28:2:263-73.
12. Shields CL, Say EA, Samara WA, Khoo CT, Mashayekhi A, Shields JA. Optical coherence tomography angiography of the macula after plaque radiotherapy of choroidal melanoma: Comparison of irradiated versus nonirradiated eyes in 65 patients. *Retina* 2016;36:8:1493-505.
13. Matet A, Daruich A, Zografos L. Radiation maculopathy after proton beam therapy for uveal melanoma: Optical coherence tomography angiography alterations influencing visual acuity. *Invest Ophthalmol Vis Sci* 2017;58:10:3851-61.
14. Skalet AH, Liu L, Binder C, Miller AK, Crilly R, Hung AY, et al. Longitudinal detection of radiation-induced peripapillary and macular retinal capillary ischemia using OCT angiography. *Ophthalmol Retina* 2020;4:3:320-6.
15. Skalet AH, Liu L, Binder C, Miller AK, Wang J, Wilson DJ, et al. Quantitative OCT angiography evaluation of peripapillary retinal circulation after plaque brachytherapy. *Ophthalmol Retina* 2018;2:3:244-50.
16. Gündüz K, Shields CL, Shields JA, Cater J, Freire JE, Brady LW. Radiation retinopathy following plaque radiotherapy for posterior uveal melanoma. *Arch Ophthalmol* 1999;117:5:609-14.
17. Krema H, Xu W, Payne D, Vasquez LM, Pavlin CJ,

- Simpson R. Factors predictive of radiation retinopathy post (125)Iodine brachytherapy for uveal melanoma. *Can J Ophthalmol* 2011;46:2:158-63.
18. Stack R, Elder M, Abdelaal A, Hidajat R, Clemett R. New Zealand experience of I125 brachytherapy for choroidal melanoma. *Clin Exp Ophthalmol* 2005;33:5:490-4.
19. Parsons JT, Bova FJ, Fitzgerald CR, Mendenhall WM, Million RR. Radiation retinopathy after external-beam irradiation: Analysis of time-dose factors. *Int J Radiat Oncol Biol Phys* 1994;30:4:765-73.
20. Monroe AT, Bhandare N, Morris CG, Mendenhall WM. Preventing radiation retinopathy with hyperfractionation. *Int J Radiat Oncol Biol Phys* 2005;61:3:856-64.
21. Gragoudas ES, Li W, Lane AM, Munzenrider J, Egan KM. Risk factors for radiation maculopathy and papillopathy after intraocular irradiation. *Ophthalmology* 1999;106:8:1571-7; discussion 7-8.
22. Viebahn M, Barricks ME, Osterloh MD. Synergism between diabetic and radiation retinopathy: Case report and review. *Br J Ophthalmol* 1991;75:10:629-32.
23. Hietala K, Harjutsalo V, Forsblom C, Summanen P, Groop PH. Age at onset and the risk of proliferative retinopathy in type 1 diabetes. *Diabetes Care* 2010;33:6:1315-9.
24. Chang M, Dalvin LA, Mazloumi M, Martin A, Yaghy A, Yang X, et al. Prophylactic intravitreal bevacizumab after plaque radiotherapy for uveal melanoma: Analysis of visual acuity, tumor response, and radiation complications in 1131 eyes based on patient age. *Asia Pac J Ophthalmol (Phila)* 2020;9:1:29-38.
25. Dalvin LA, Zhang Q, Hamerschock RA, Chang M, Yu MD, Mashayekhi A, et al. Nomogram for visual acuity outcome after iodine-125 plaque radiotherapy and prophylactic intravitreal bevacizumab for uveal melanoma in 1131 patients. *Br J Ophthalmol* 2020;104:5:697-702.
26. Finger PT, Kurli M. Laser photocoagulation for radiation retinopathy after ophthalmic plaque radiation therapy. *Br J Ophthalmol* 2005;89:6:730-8.
27. Hykin PG, Shields CL, Shields JA, Arevalo JF. The efficacy of focal laser therapy in radiation-induced macular edema. *Ophthalmology* 1998;105:8:1425-9.
28. Kinyoun JL. Long-term visual acuity results of treated and untreated radiation retinopathy (an AOS thesis). *Trans Am Ophthalmol Soc* 2008;106:325-35.
29. Kinyoun JL, Lawrence BS, Barlow WE. Proliferative radiation retinopathy. *Arch Ophthalmol* 1996;114:9:1097-100.
30. Murray TG, Latiff A, Villegas VM, Gold AS. Aflibercept for radiation maculopathy (ARM Study): Year-2 extension of a prospective clinical study. *J Vitreoretin Dis* 2021;53:232-8.
31. Srivastava Q, Weis E. Outcomes of second-line intravitreal anti-VEGF switch therapy in radiation retinopathy secondary to uveal melanoma: Moving from bevacizumab to aflibercept. *Ocul Oncol Pathol* 2023;84:6:230-5.
32. Trejo Corona S, Villanueva Boone C, Ali AM, Moore C, Brown A, Munoz J, et al. Randomized trial of treat-and-extend intravitreal aflibercept for radiation retinopathy: 1-Year outcomes. *Invest Ophthalmol Vis Sci* 2023;64:7:35.
33. Yu HJ, Fuller D, Anand R, Fuller T, Munoz J, Moore C, et al. Two-year results for ranibizumab for radiation retinopathy (RRR): A randomized, prospective trial. *Graefes Arch Clin Exp Ophthalmol* 2022;60:1:47-54.
34. Murray JE, Gold AS, Latiff A, Murray TG. Brolucizumab: Evaluation of compassionate use of a complex anti-VEGF Therapy. *Clin Ophthalmol* 2021;15:4731-8.
35. Zhuang J, Yang Y, Liao Y, Li C, Wang WA, Luo X, et al. Efficacy of intravitreal injections anti-vascular endothelial growth factor treatment for radiation retinopathy: A systematic review and meta-analysis. *Am J Ophthalmol* 2024;263:141-51.
36. Frizziero L, Parrozzani R, Trainiti S, Pilotto E, Miglionico G, Pulze S, et al. Intravitreal dexamethasone implant in radiation-induced macular oedema. *Br J Ophthalmol* 2017;101:12:1699-703.
37. Zimmermann L, Kneifel C, Grajewski L, Ciernik IF, Krause L. Treatment of radiation-induced maculopathy with fluocinolone acetonide. *Graefes Archive for Clinical and Experimental Ophthalmology* 2020;258:11:2535-9.
38. Singaravelu J, Oakey ZB, Wrenn JM, Singh AD. Intravitreal fluocinolone acetonide implant for radiation retinopathy: Report of preliminary findings. *Retina* 2023;43:8:1364-9.
39. Seibel I, Riechardt AI, Davids A-M, Böker A, Rehak M, Hager A, et al. Radiation retinopathy after proton beam therapy in uveal melanoma. *Investigative Ophthalmology & Visual Science* 2016;57:12:4097.
40. Shields CL, Dalvin LA, Chang M, Mazloumi M, Fortin P, McGarvey M, et al. Visual outcome at 4 years following plaque radiotherapy and prophylactic intravitreal bevacizumab (every 4 months for 2 years) for uveal melanoma: Comparison with nonrandomized historical control individuals. *JAMA Ophthalmol* 2020;138:2:136-46.
41. Powell BE, Finger PT. Anti-VEGF Therapy immediately after plaque radiation therapy prevents or delays radiation maculopathy. *Ophthalmol Retina* 2020;45:547-50.
42. Kim IK, Lane AM, Jain P, Awh C, Gragoudas ES. Ranibizumab for the prevention of radiation complications in patients treated with proton beam irradiation for choroidal melanoma. *Trans Am Ophthalmol Soc* 2016;114:72.
43. McCannel TA, McCannel CA. Iodine 125 brachytherapy with vitrectomy and silicone oil in the treatment of uveal melanoma: A 1-to-1 matched case-control series. *Int J Radiat Oncol Biol Phys* 2014;92:347-52.
44. Eib-Lindner K, Fürweger C, Nentwich M, Foerster P, Wowra B, Schaller U, Muacevic A. Robotic radiosurgery for the treatment of medium and large uveal melanoma. *Melanoma Res* 2016;26:1:51-7.
45. Intravitreal Faricimab injections or fluocinolone acetonide (0.19 mg) intravitreal implants vs observation for prevention of VA loss due to radiation retinopathy (AL): [ClinicalTrials.gov. 2023 \[updated May 6, 2024. NCT05844982\]. Available from: https://clinicaltrials.gov/study/NCT05844982?cond=Radiation%20Retinopathy&aggFilters=status:rec&rank=1.](https://clinicaltrials.gov/study/NCT05844982?cond=Radiation%20Retinopathy&aggFilters=status:rec&rank=1)

**ABOUT THE AUTHORS**



**Ms. Krivit** is a medical student at the University of Queensland, Australia.



**Dr. Yaghy** is a first-year resident at the Department of Ophthalmology and Visual Sciences, University of Massachusetts Chan Medical School in Worcester.



**Dr. Dalvin** is an associate professor of ophthalmology and a senior associate consultant in the Division of Medical Oncology, Department of Oncology at the Mayo Clinic in Rochester. She is a Consultant for Ideaya Biosciences. Neither of the other authors have a financial interest in any of the material presented.

Correspondence to: Lauren A. Dalvin, MD. Email address: [dalvin.lauren@mayo.edu](mailto:dalvin.lauren@mayo.edu)



EDITED BY ERIK MASZENIO, MD

## WILLS EYE RESIDENT CASE REPORT

*A 64-year-old man was referred to Wills Eye Hospital for a suspicious conjunctival lesion in his left eye.*

THOMAS M. CATAPANO, BS, ERIC B. LEE, MD, TATYANA MILMAN, MD, CAROL L. SHIELDS, MD  
PHILADELPHIA

### Presentation

A 64-year-old man was referred to Wills Eye Ocular Oncology clinic for a pigmentedary lesion on his left eye. He had seen an ophthalmologist three months prior, at which point the pigmented area had already been noted for approximately four months. The patient denied any vision changes, pain, redness or discharge.

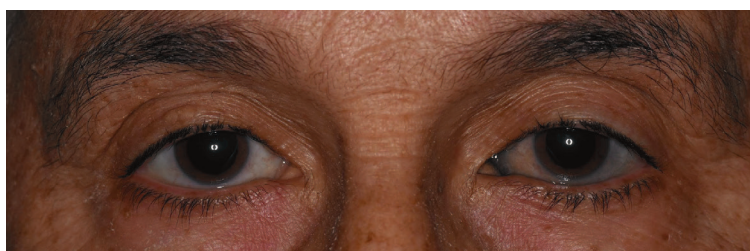### History

The patient had an ocular history of central retinal vein occlusion in the left eye 10 years prior. He also had dry eyes, for which he took an over-the-counter eye drop. His medical history was notable for hyperlipidemia and benign prostatic hypertrophy, for which he took pravastatin and finasteride. He was a former smoker. Ocular family history included macular degeneration. Review of systems was unremarkable.

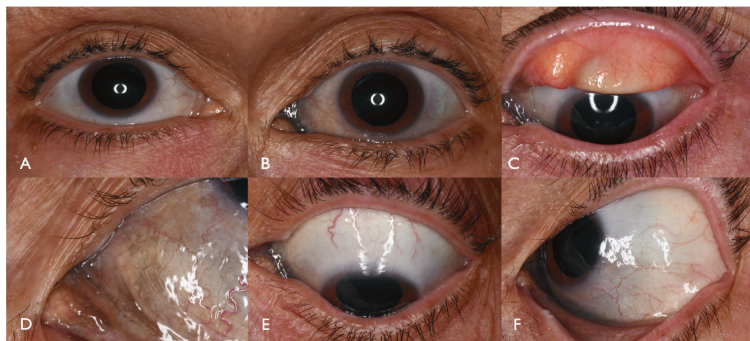
### Examination

At presentation, corrected visual acuity was 20/20 in the right eye and 20/30 in the left. The pupils were round and reactive in both eyes without an afferent pupillary defect in either eye. Intraocular pressures were 20 mmHg OD and 22 mmHg OS. Extraocular motility was full bilaterally.

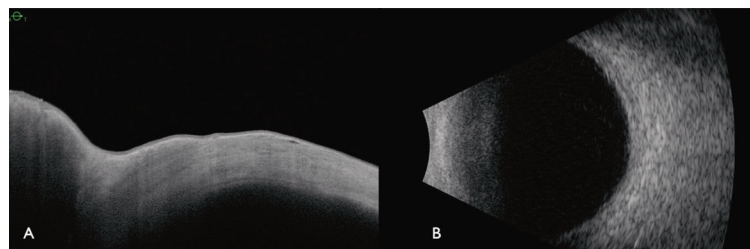
The anterior segment examination OD was unremarkable (*Figures 1 and 2*). The anterior segment examination OS revealed a diffuse (30 x 20 mm diameter) area of ill-defined gray pigmentation of the inferonasal bulbar conjunctiva, extending from the inferonasal limbus and involving the tarsal conjunctiva, plica semilunaris and caruncle (*Figures 1 and 2*). There was no skin, scleral, iris or choroidal involvement. Anterior segment optical coherence tomography of the conjunctiva OS was normal with no atypical thickening, hyperreflectivity or cystic changes. B-scan ultrasonography OS was unremarkable with no evidence of scleral or choroidal abnormalities (*Figure 3*).



**Figure 1.** External photograph of both eyes in primary gaze highlighting gray conjunctival inferonasal pigmentation on the left eye.



**Figure 2.** External photography at presentation of the right eye (A) and left eye (B) in primary gaze. Left upper eyelid eversion showing superior tarsus clear of pigmentation (C). The inferonasal conjunctiva demonstrated pigmentation (D), that was absent superiorly (E) and temporally (F).



**Figure 3.** (A) Anterior segment OCT and (B) B-scan ultrasonography of the left eye with normal findings.

***What's your diagnosis? What management would you pursue? The case continues on the next page.***

## Work-up, Diagnosis and Treatment

The differential diagnosis for a conjunctival pigmented lesion includes benign and malignant melanocytic tumors such as complexión-associated melanosis (CAM), primary acquired melanosis (PAM), secondary acquired melanosis (SAM) and conjunctival non-melanin pigmentation from trauma, exposure, systemic diseases (ochronosis), mascara, tattoos or medications. Since the lesion was gray and unilateral, conjunctival deposition of an unidentified material was the suspected diagnosis.

The patient underwent an incisional biopsy with cryotherapy to better understand the diagnosis. Histopathology demonstrated black, punctate, uniform size, non-birefringent deposits scattered deep to the epithelium between collagen fibrils in the stroma, and in a perivascular distribution (Figure 4). The deposits were primarily extracellular and associated with a mild chronic non-granulomatous inflammatory infiltrate. There was no evidence of malignancy. Further history revealed the patient used a medication, Nature's Sunshine brand Silver Shield eye drops for nine years for dry-eye symptoms, three to four times a day, instilled directly into the eyes as advised by his naturopathy practitioner.

Our final diagnosis was conjunctival secondary acquired pigmentation (SAP) from Silver Shield eye drops. This medication was advised to be discontinued. The patient didn't require additional treatment.

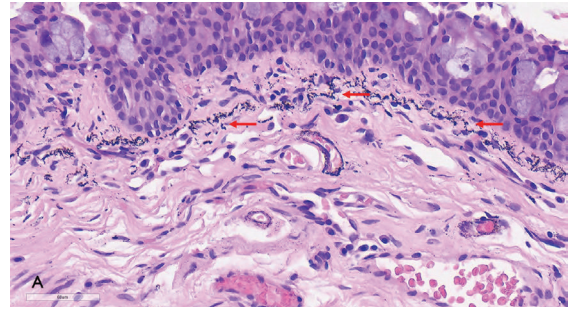
## Discussion

Pigmented lesions of the conjunctiva include a variety of neoplastic and non-neoplastic conditions.<sup>1</sup> Melanocytic neoplasms can present with few symptoms and include benign nevus, CAM, PAM and SAM, but it should be noted that serious life-threatening neoplasms can also occur in the conjunctiva, such as melanoma and pigmented squamous cell carcinoma.

SAM can result from a number of conditions including conjunctival trauma, inflammation, exposure from edema or exposure from elevation over pinguecula/pterygium/squamous cell carcinoma, by a mechanism of reactive melanosis of the conjunctival epithelium. In contrast, SAP can be caused by systemic disorders (such as Addison's disease), ochronosis, or exposure to radiotherapy or chemicals. SAP can also be caused by deposition of medications (Argyrol, silver-dosed eye medications, oral minocycline/tetracycline), periocular makeup (mascara) or periocular/ocular tattoos.<sup>3-6</sup> In contrast to SAM, SAP is pathologically characterized by deposition of pigment without melanosis, though clinically the presentation of SAM and SAP can be difficult to distinguish.<sup>1-4</sup> An understanding of each of these conditions is important as each carries different implications on the ocular and systemic management.<sup>4,7</sup>

Notable to this case, SAP was from chronic conjunctival silver deposition and is known as conjunctival argyrosis, a condition that can be mistaken for CAM and PAM.<sup>7,8</sup> The clinical symptoms of argyrosis relate to the gray discoloration of the conjunctiva that results from deposition of silver within the epithelium and later infiltration into the subepithelial layers.<sup>7-9</sup> While this clinical manifestation may be cosmetically disfiguring, ocular argyrosis doesn't cause visual disturbance.<sup>7-9</sup>

Historically, naturally occurring silver was used for various applications. In the late 1800s, silver nitrate was used as pro-



**Figure 4. (A) Histopathologic specimen of the left eye from the nasal bulbar conjunctiva and plica semilunaris showing black, punctate nonbirefringent deposits (arrows) in the stroma, underlying the epithelium and focally in a perivascular distribution.**

phylaxis for neonatal ophthalmia to prevent the effects of ocular infections.<sup>10</sup> Silver-containing drops are no longer used.<sup>9</sup> Silver is still used for wound dressings (Nanocrystalline silver) and medical devices (bone cements, catheters, surgical sutures, cardiovascular prostheses and dental fillings) as a broad-spectrum anti-infection agent.<sup>9</sup> Other common causes of ocular argyrosis include unintended exposure to silver compounds from inadequate eye protection in workplaces, such as with silver workers including polishers, engravers, and smelters; and workers in the photographic film and X-ray film manufacturing industry.<sup>7,8</sup>

In summary, this patient demonstrated conjunctival SAP from chronic exposure to silver eye drops. It's worth noting that manifestations of SAP can masquerade as potentially a neoplastic process and it's important to review the patient's history, medication use, systemic conditions and exposures to uncover the proper etiology. ◀

- Bresler SC, Simon C, Shields CL, et al. Conjunctival pigmented lesions. *Arch Pathol Lab Med* 2022;146:5:632-646.
- Stulberg DL, Clark N, Tovey D. Common hyperpigmentation disorders in adults: Part I. Diagnostic approach, café au lait macules, diffuse hyperpigmentation, sun exposure, and phototoxic reactions. *Am Fam Physician* 2003;68:10:1955-60.
- Liesegang TJ. Pigmented conjunctival and scleral lesions. *Mayo Clin Proc* 1994;69:2:151.
- Shields CL, Shields HA. Tumors of the conjunctiva and cornea. *Surv of Ophthalmol* 2004;49:1:3-24.
- Gandhi V, Verma P, Naik G. Exogenous ochronosis after prolonged use of topical hydroquinone (2%) in a 50-year-old Indian female. *Indian J Dermatol* 2012;57:5:394-395.
- Maloney SM, Williams BK, Shields CL. Long-term minocycline therapy with scleral pigmentation simulating melanocytosis. *JAMA Ophthalmol* 2018;136:11:e183088.
- Tendler IM, Pulitzer MP, Roggli V et al. Ocular argyrosis mimicking conjunctival melanoma. *Cornea* 2017;36:6:747-748.
- Zografos L, Uffer S, Chamot L. Unilateral conjunctival-corneal argyrosis simulating conjunctival melanoma. *JAMA Ophthalmol* 2003;121:10:1483-1487.
- Landsdown ABG. A pharmacological and toxicological profile of silver as an antimicrobial agent in medical devices. *Adv Pharmacol Sci* 2010;910686. Epub 2010 Aug 24.
- Moore DL, MacDonald NE, Canadian Paediatric Society. Preventing ophthalmia neonatorum. *Paediatr Child Health* 2015;20:2:93-96.

From the makers of the #1-prescribed dry eye brand in Europe\*

## Covering the spectrum of

# Dry Eye Relief

Over-the-counter iVIZIA® lubricant eye drops protect the ocular surface and deliver a unique combination of immediate and long-lasting relief in a **preservative-free** formulation.

- A unique formulation—including povidone (active), trehalose (inactive), and hyaluronic acid (inactive)
- Proprietary, multi-dose preservative-free (MDPF) bottle

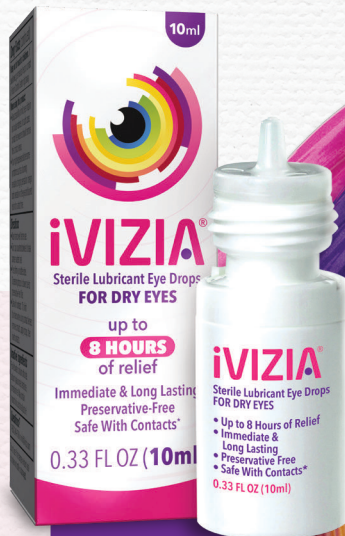### Chronic Dry Eye Patient Usage Study†:

Up to  
**8 hours**  
of relief

as well as improved comfort during computer work, reading, and driving<sup>1</sup>

**84%**

of users reported iVIZIA worked better than their previous eye drops<sup>1</sup>



Safe for use with contact lenses‡



Recommend iVIZIA and request samples by visiting [iVIZIA.com/ECP](https://www.iVIZIA.com/ECP)

Scan here.

\*Prescription market data, Dec. 2022 – S01K without cyclosporine.

†In a chronic dry eye patient usage study, participants from a variety of socioeconomic backgrounds answered questions about their experience with iVIZIA lubricant drops. In the study, 203 chronic dry eye patients, 28-80 years old, switched from their dry eye artificial tears to iVIZIA for a month.<sup>1</sup>

‡To limit blurriness when using contact lenses, remove contacts, apply drops, then insert contacts.

Reference: 1. Thea Data on File.

Copyright ©2024 Thea Pharma Inc. | All Rights Reserved. | PRC-IED-1030-v4 1.2024

 **Thea**  
let's open our eyes


# INTERVENTIONAL GLAUCOMA SHATTERING THE STATUS QUO

Introducing

**iDose<sup>®</sup> TR**   
(travoprost intracameral  
implant) 75 mcg

**The catalyst to advance the interventional glaucoma revolution, helping you and your patients take back control of their treatment journey.**

iDose TR is a long duration intracameral procedural pharmaceutical that delivers prostaglandin analog therapy for the reduction of intraocular pressure in patients with open-angle glaucoma or ocular hypertension.<sup>1</sup>

 **Actual size**  
1.8mm x 0.5mm

1. iDose TR (travoprost intracameral implant) 75 mcg Prescribing Information. Glaukos Corporation. 2023.

## INDICATIONS AND USAGE

iDose TR (travoprost intracameral implant) is indicated for the reduction of intraocular pressure (IOP) in patients with open angle glaucoma (OAG) or ocular hypertension (OHT).

## IMPORTANT SAFETY INFORMATION

### DOSAGE AND ADMINISTRATION

For ophthalmic intracameral administration. The intracameral administration should be carried out under standard aseptic conditions.

### CONTRAINDICATIONS

iDose TR is contraindicated in patients with active or suspected ocular or periocular infections, patients with corneal endothelial cell dystrophy (e.g., Fuch's Dystrophy, corneal guttatae), patients with prior corneal transplantation, or endothelial cell transplants (e.g., Descemet's Stripping Automated Endothelial Keratoplasty [DSAEK]), patients with hypersensitivity to travoprost or to any other components of the product.

### WARNINGS AND PRECAUTIONS

iDose TR should be used with caution in patients with narrow angles or other angle abnormalities. Monitor patients routinely to confirm the location of the iDose TR at the site of administration. Increased pigmentation of the iris can occur. Iris pigmentation is likely to be permanent.

### ADVERSE REACTIONS

In controlled studies, the most common ocular adverse reactions reported in 2% to 6% of patients were increases in intraocular pressure, iritis, dry eye, visual field defects, eye pain, ocular hyperaemia, and reduced visual acuity.

Please see full [Prescribing Information](#).

You are encouraged to report all side effects to the FDA. Visit [www.fda.gov/medwatch](http://www.fda.gov/medwatch), or call 1-800-FDA-1088.

You may also call Glaukos at 1-888-404-1644.

View full  
prescribing  
information at  
[iDoseTRhcp.com](http://iDoseTRhcp.com)



**GLAUKOS**  
TRANSFORMING VISION